

Special Article - Cancer Clinical Cases and Images

Chondromatosis of the Sternum

Feng C*

Department of Radiology and Anesthesiology, First Hospital of Jilin University, China

***Corresponding author:** Chunsheng Feng, Department of Anesthesiology, The First Hospital of Jilin University, China

Received: October 13, 2015; **Accepted:** November 04, 2015; **Published:** November 06, 2015

Keywords

Sternal tumors; Chondromatosis; Computed tomography

Abbreviation

CT: Computed Tomography

Clinical Image

A 62-year-old woman presenting with exertional shortness of breath for 18 months was admitted to our hospital. Chest CT showed Sternal tumor with circular calcification, shifting adjacent mediastinal structures (Figure1). Diagnostic biopsy of the lesion was indicative of

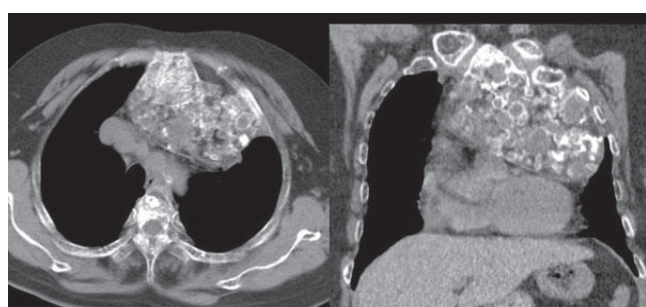


Figure 1: Chest axial and oblique reformatted CT images showed giant sternal mass with scattered circular or arc calcifications.

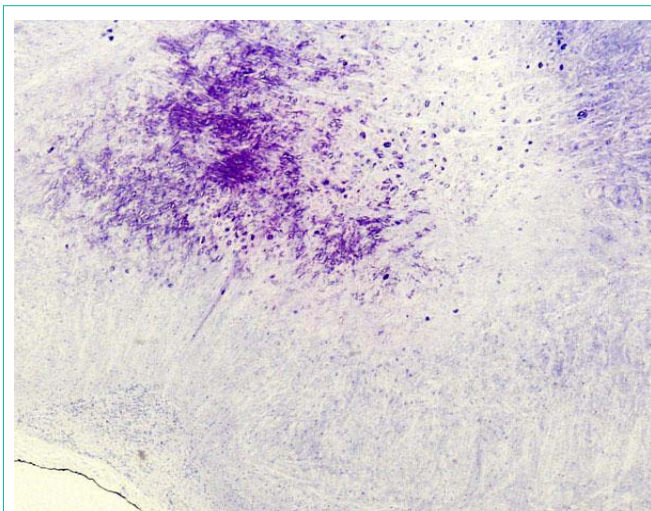


Figure 2: Pathological analysis from biopsy showed cartilaginous cells without cytologic atypia (HE stain \times 40).

chondroma with no evidence of malignancy (Figure2). The patient refused any intervention.