

Case Report

Vibrio Cholerae Colonisation in a Case of Bilateral Cystic Bronchiectasis in an Immunocompetent Male

Muniza Bai^{1*}; Lakshmi Shanmugam²; Dharm Prakash Dwivedi³; Sujatha Sistla⁴; Manju R⁵

¹Senior Resident, Department of Pulmonary Medicine, Jawaharlal Institute of Postgraduate Medical Education and Research, India

²Senior Resident, Department of Microbiology, Jawaharlal Institute of Postgraduate Medical Education and Research, India

³Associate Professor, Department of Pulmonary Medicine, Jawaharlal Institute of Postgraduate Medical Education and Research, India

⁴Professor, Department of Microbiology, Jawaharlal Institute of Postgraduate Medical Education and Research, Puducherry, India

⁵Additional Professor, Department of Pulmonary Medicine, Jawaharlal Institute of Postgraduate Medical Education and Research, India

***Corresponding author: Muniza Bai**

Department of Pulmonary Medicine, Jawaharlal Institute of Postgraduate Medical Education and Research, Puducherry, India.

Email: muzuni123@gmail.com

Received: May 29, 2023

Accepted: June 21, 2023

Published: June 28, 2023

Case Details

A 41-year-old man presented with complaints of cough with copious, mucopurulent and foul-smelling expectoration for 2 months. It was not associated with hemoptysis. He had breathlessness of grade 3 severity as per modified medical research council. It was associated with wheeze and seasonal worsening in the winters and rainy season. He also gave history of low-grade fever on and off for 2 months with evening rise of temperature. Fever was not associated with rashes, pain abdomen, or change in bowel and bladder habits.

He had history of ATT intake for 2 months for smear positive pulmonary tuberculosis 15 years back. He has been having recurrent respiratory tract infections since then.

Abstract

Non O1 and non O139 strains of *Vibrio cholerae* are often nontoxigenic and tend to cause extraintestinal infections such as wound infections, external ear infection, sepsis, epidural and subdural abscesses. We herein describe an unusual presentation where there is colonisation of *Vibrio cholerae* in a case of bilateral cystic bronchiectasis in an immunocompetent male.

Keywords: Bronchiectasis; Immunocompetent; *Vibrio cholerae*

On examination, he was conscious, oriented and comfortable at rest. His vitals were stable. He was afebrile. His general examination was normal except for pandigital grade 3 clubbing. Respiratory system examination revealed bilateral normal vesicular breath sounds and diffuse coarse crepitations in all areas. Other system examination was unremarkable.

Chest radiograph showed bilateral ectatic changes in mid and lower zones along with non-homogeneous opacities. HRCT thorax revealed bilateral lower lobe predominant cystic bronchiectasis along with tree in bud nodules (Figure 1). His routine blood investigations – complete blood count, renal and liver function tests were normal. Serum immunoglobulin levels were normal. Sweat chloride level was within normal levels.

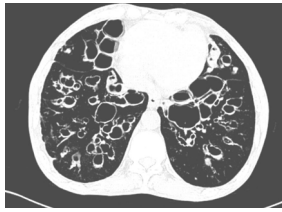

Figure 1: High resolution computed tomography of thorax showing bilateral lower lobe predominant cystic bronchiectasis along with tree in bud nodules.

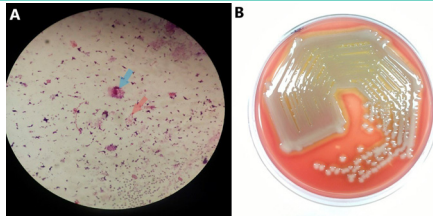


Figure 2: A) Direct gram staining of sputum showing pus cells (blue arrow) and curved gram-negative rods (red arrow). B) 5% sheep blood agar plate showing circular smooth grey moist mucoid colonies with hemodigestion.

Sputum workup for Mycobacterium tuberculosis complex was negative by Ziehl Neelsen acid-fast staining and Auramine phenol staining, nucleic acid amplification test (GenXpert® MTB/RIF) and liquid culture (BD BACTEC™ MGIT™ mycobacterial growth indicator tube). Sputum stain & culture for fungal elements were negative. Deeply coughed out sputum was sent for pyogenic culture. Direct gram staining showed pus cells >25 per Low Power Field (LPF), epithelial cells <5 per LPF and curved gram-negative rods (Figure 2A). 1µl of the sample was plated onto 5% Sheep Blood Agar (SBA) and MacConkey agar and incubated at 37°C with 5-10 % CO₂. After 16-18 hours of aerobic incubation, heavy growth of circular grey moist mucoid colonies with hemodigestion were seen in 5% SBA (Figure 2B) and pale non lactose fermenting colonies in MacConkey agar. Gram stain performed from colonies in both the plates showed curved gram-negative rods and exhibited darting motility. String test with 0.5% sodium deoxycholate was positive. Subculture onto Thiosulfate-Citrate-Bile Salts-sucrose agar (TCBS) showed flat yellow colonies. Biochemical reactions were as follows: Indole produced, citrate utilised, urea not hydrolysed and alkaline

slant with acidic butt in Kligler iron agar. The colonies were subjected to matrix assisted laser desorption ionisation - time of flight (MALDI TOF MS- VITEK®MS, bioMérieux) and was identified as *Vibrio cholerae* with a confidence interval of 99%. The strain was not agglutinated with antisera against *Vibrio cholerae* O1 and O139. The isolate was hence identified as *Vibrio cholerae* non O1 non O139. Antimicrobial susceptibility testing was performed by Kirby Bauer disc diffusion method and interpreted using Clinical and Laboratory Standards Institute break-points (CLSI M45-3rd edition) and was found to be sensitive to Levofloxacin, Cefoperazone Sulbactam, Ceftazidime, Ceftriaxone, Amikacin and Azithromycin. Sputum for pyogenic culture was repeated twice to confirm the organism [1]. However, rectal swab culture was negative for *Vibrio cholerae*. We further probed in the history to find some clue to the colonization of lower respiratory tract by *Vibrio cholerae*. He does not live in the coastal areas. No history of loose stools or watery stools. His work is not related to exposure to sea water, he is unemployed for the past 10 years.

He was treated with Levofloxacin and bronchodilators for 14 days. His sputum quantity and purulency improved. He was discharged, is now under teleconsultation follow up and doing well.

Learning Points

- *Vibrio cholerae* causing bacteremia is well known, but respiratory tract being the entry point is rarely reported [2].
- Spectrum of diseases caused by *Vibrio cholerae* is expanding as we see the colonisation of *Vibrio cholerae* in a case of bilateral cystic bronchiectasis in an immunocompetent male.

References

1. Hindler JA, Richter SS. Methods for antimicrobial dilution and disk susceptibility testing of infrequently isolated or fastidious bacteria: M45. 3rd edition. Wayne, PA: Clinical and Laboratory Standards Institute; 2016. 98. (Documents / Clinical and Laboratory Standards Institute).
2. Shannon JD, Kimbrough RC. Pulmonary Cholera Due to Infection with a Non-O1 *Vibrio cholerae* Strain. J Clin Microbiol. 2006; 44: 3459–60.