

## Case Report

# Spontaneous Neonatal Posterior Gastric Perforation with Tension Pneumoperitoneum of Lesser Sac

Govani DR<sup>1</sup>, Kumar H<sup>2</sup>, Scott V<sup>3</sup>, Patel RR<sup>4</sup>, Patel RV<sup>5\*</sup> and Doshi S<sup>6</sup>

<sup>1</sup>Department of Surgery, University of Birmingham Medical School, UK

<sup>2</sup>Department of Ped Surgery, Patan Academy of Health Sciences, Nepal

<sup>3</sup>Department of Ped Surgery, Royal Alexandra Children's Hospital, UK

<sup>4</sup>Department of Pediatrics, Saurashtra University, India

<sup>5</sup>Department of Ped Surgery, Saurashtra University, India

<sup>6</sup>Department of Pediatrics, Saurashtra University, India

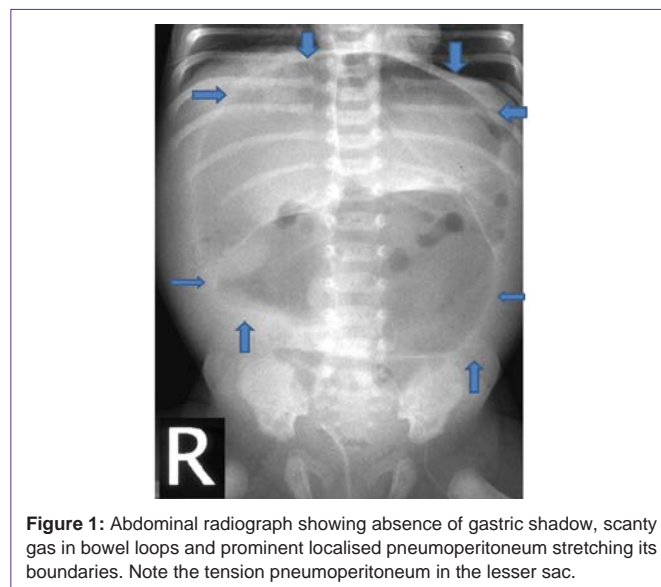
\*Corresponding author: Patel RV, Department of Surgery, Postgraduate Institute of Child Health and Research and K T Children Government Hospital, Saurashtra University, Rajkot 360001 Gujarat, India

Received: June 14, 2014; Accepted: July 07, 2014;

Published: July 08, 2014

A 21-day-old full term boy born after an uneventful pregnancy and normal vaginal delivery, weighing 3650 g, presented to paediatric accident and emergency department with a history of poor feeding, lethargy, fever, abdominal distension and anuria for 12 hours. On examination he was lethargic with marked upper and central abdominal distension. Bowel sounds were absent. Urethral catheterisation yielded 10mls of very concentrated urine. His pulse was 186bpm, respiratory rate of 56 breaths/min and temperature of 35.8°C. His blood results showed hemoglobin of 128 Gm/L, white cell count  $26 \times 10^9/L$ , polymorphs  $22 \times 10^9/L$ , platelets  $120 \times 10^9/L$ , and C-reactive protein 350 mg/L. An abdominal radiograph showed an isolated tension pneumoperitoneum localised to the lesser sac and stretching its boundaries to both sides and inferiorly into greater omental leaves (Figure 1). At exploration the lesser sac was very tense and filled with gas. On opening the lesser sac a gush of free air was noted and a 2 cm perforation was seen on the posterior wall of the stomach, near the greater curvature. Inflammatory exudates were seen in the lesser sac cavity. The rest of the abdomen was clear and the downstream intestinal tract was intact. The perforation edges were freshened and a primary repair in two layers using 4/0 PDS sutures concluded the operation. The postoperative period was uneventful with discharge home on day 5. Histopathology of the perforation border revealed nonspecific inflammation supporting the diagnosis of a spontaneous perforation.

Spontaneous posterior gastric perforation is rare especially if it presents with lesser sac pneumoperitoneum. Neonatal gastric perforations can be iatrogenic or ischemic in preterm or term neonates and spontaneous perforation is very rare<sup>1</sup>. Perforation usually presents with a generalised pneumoperitoneum [1]. A giant bilious collection (from a neonatal spontaneous bile duct perforation) may localise to the lesser sac and may organise to form a pseudocyst



**Figure 1:** Abdominal radiograph showing absence of gastric shadow, scanty gas in bowel loops and prominent localised pneumoperitoneum stretching its boundaries. Note the tension pneumoperitoneum in the lesser sac.

[2]. Tropical infections may rarely cause gastro-duodenal perforations in infants [3].

Neonatal spontaneous gastric perforation is rare and potentially lethal and can cause a generalised tension pneumoperitoneum with splinting of diaphragm and abdominal compartment syndrome. Posterior gastric perforation in a term, otherwise well, neonate may seal the foramen of Winslow and localise it to lesser sac only and may keep the rest of the abdominal cavity clean.

We believe that the posterior gastric perforation causes complete and immediate chemical vagotomy leading to gastroparesis and ileus may allow foramen of Winslow being sealed with peritoneal patch from gastrointestinal loops and/or omental serosal patch allowing air to accumulate in the lesser sac stretching all its boundaries leading to tension lesser sac pneumoperitoneum as evident in our case.

In cases of spontaneous neonatal bile duct perforation chemical irritation and aseptic peritonitis may allow the foramen of Winslow being sealed with serosal patch leading to a giant tension pseudocyst of the lesser sac [2]. An omental infarct plugging the inguinal hernial orifice leading to acute tension hemiscrotum with scrotal compartment syndrome leading to testicular ischemia and subsequent atrophy has been reported [4]. Extensive search of the literature failed to find a similar case in the English literature and to the best of our knowledge this could be the first documented case of lesser sac tension pneumoperitoneum following spontaneous posterior gastric perforation in a neonate.

## References

1. Lawther S, Patel R, Lall A. Neonatal gastric perforation with tension pneumoperitoneum. *J Ped Surg Case Reports*. 2013; 1: 14-16.

2. Patel RV, Durell J, Dagash H, Patwardhan N. Neonatal spontaneous bile duct perforation presenting as giant intraabdominal cyst. *J Ped Surg Case Reports*. 2013; 1: 36-38.
3. Stabell N, Klingenberg C, Rushfeldt C. Duodenal perforation in an infant with rotavirus gastroenteritis. *BMJ Case Rep*. 2013; 2013.
4. Patel RV, Dawrant M, Scott V, Fisher R. Omental infarct in a hernia: an unusual cause of paediatric acute scrotum. *BMJ Case Rep*. 2014; 2014.