

## Mini Review

# Myocarditis in Patients with COVID-19

**Parillo M and De Stefano D\***

Unit of Diagnostic Imaging and Interventional Radiology,  
Departmental Faculty of Medicine and Surgery,  
Università Campus Bio-Medico di Roma, Rome, Italy

**\*Corresponding author:** Domenico De Stefano,  
Università Campus Bio-Medico di Roma, Via Alvaro del  
Portillo, 21, 00128, Rome, Italy

**Received:** August 27, 2021; **Accepted:** September 30,  
2021; **Published:** October 07, 2021

## Abstract

SARS-CoV-2 is an enveloped RNA beta coronavirus, identified as the pathogen responsible for coronavirus disease 2019 (COVID-19). It primarily affects the respiratory system; however, cardiovascular complications have been found in 30% of hospitalized patients, associated with worse outcomes. The virus can invade human host cell by binding with high affinity the Angiotensin Converting Enzyme 2 (ACE 2) receptor, which is expressed especially in the lungs and heart, where the human immune response can lead to an inflammation of the myocardium itself. Patients with myocarditis commonly experience nonspecific signs and symptoms; laboratory tests often revealed elevated marker of myocardial necrosis and inflammation while electrocardiogram in most patients have demonstrated features similar to an acute coronary syndrome. Echocardiography is the first method of investigation to evaluate the left ventricular systolic function. In suspected case, Cardiac Magnetic Resonance Imaging (CMRI) is acknowledged as the non-invasive gold standard test for myocarditis, also useful in assessing prognosis. Endomyocardial biopsy (EMB), although considered a gold standard for the diagnostic confirmation of myocarditis, is an invasive procedure that cannot be performed in all patients. Current management is mainly supportive in association with glucocorticoids.

**Keywords:** Myocarditis; SARS-CoV-2; COVID-19; Cardiac Magnetic Resonance Imaging

## Introduction

Severe Acute Respiratory Syndrome Coronavirus 2 (SARS-CoV-2) is an enveloped RNA with positive polarity beta coronavirus, identified as the pathogen responsible for coronavirus disease 2019 (COVID-19) [1]. This pathology was first reported in Wuhan (China) in December 2019 and, then, in March 2020 the World Health Organization (WHO) declared a COVID-19 global pandemic [2]. SARS-CoV-2 primarily infects the lung epithelium causing flu-like symptoms (headache, anosmia, dysgeusia, cough, fever, myalgia, and dyspnea) as the most common clinical manifestation; however cardiovascular complications have been found in 30% of hospitalized patients, sometimes associated with worse outcomes [3].

## Pathogenesis

SARS-CoV-2 through the receptor-binding domain on the S protein can invade the human host cell by binding with high affinity the Angiotensin Converting Enzyme 2 (ACE 2) receptor. ACE-2 is widely expressed throughout the body, especially in the lungs and heart where the TMPRSS2 co-expression is required for SARS-CoV-2 entry. After penetration, viral RNA enters the cell nucleus for replication and apoptosis [4]. The human immune response to the virus is variable as the clinical presentation. Several mechanisms have been proposed to explain the underlying pathophysiology of COVID-19-related acute myocarditis but the main biomolecular mechanism responsible for heart damage is thought to be the abnormal state of systemic inflammation, causing low oxygen levels and thrombosis and the cell-mediated cytotoxicity in which CD8+ T lymphocytes migrate to cardiomyocytes with an inflammation of the myocardium itself [5]. Furthermore, myocardial damage may be due to the direct viral action on the tissue or to extrapulmonary migration of

infected alveolar macrophages through the bindings of the ACE2; these bindings in turn cause downregulation of ACE2 receptors with increases type 1 angiotensin II receptors expression, which leads finally to endothelial damage and vasoconstriction in both lung and heart [6]. Lastly, the hyperactivation of the autoimmune system with possible interferon mediated activation of the innate and adaptive immune system has also been proposed as possible mechanism [7].

## Signs and Symptoms

Patients with myocarditis commonly experience dyspnea and fever, followed by cough and chest pain. Other reported symptoms include nausea, fatigue, myalgia, diarrhea and headache, all flu-like symptoms which hamper the clinical diagnosis of myocarditis especially in the setting of COVID-19 pandemic [8].

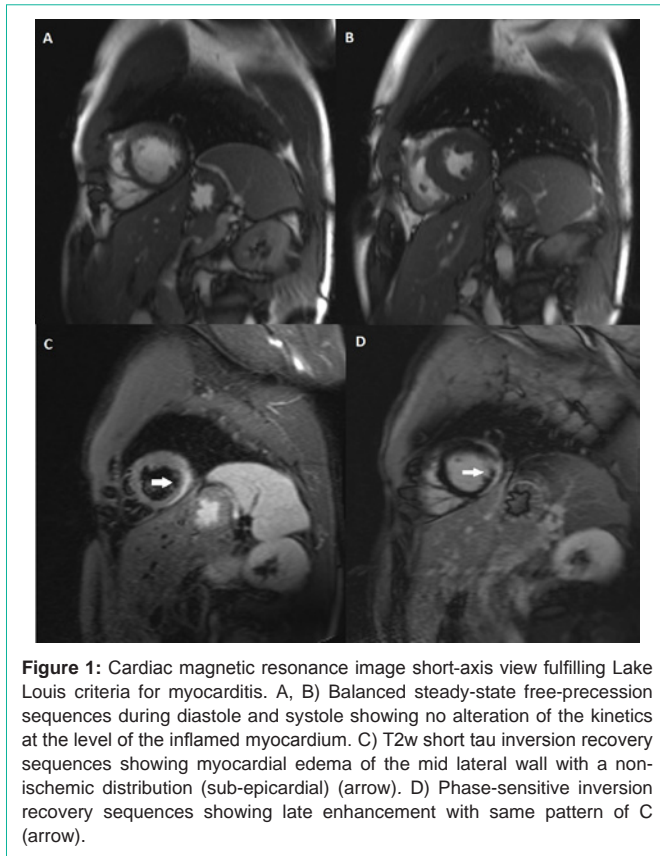
## Laboratory and Instrumental Findings

In many COVID-19 patients elevated levels of troponin, Creatine Kinase Myocardial Band (CKMB), Brain Natriuretic Peptide (BNP) and also of C-Reactive Protein (CRP) were reported; however, these are nonspecific findings as normal levels did not exclude myocarditis [9].

Electrocardiogram (ECG) in most patients with myocarditis have demonstrated features including sinus tachycardia, ST-segment elevation, T-wave abnormalities and occasional atrioventricular or branch blocks [10], findings often similar to acute coronary syndrome.

## Imaging Findings

Echocardiography it is the first and most available method of investigation, demonstrating mainly the presence of pericardial effusion, global left ventricular systolic dysfunction and regional



**Figure 1:** Cardiac magnetic resonance image short-axis view fulfilling Lake Louis criteria for myocarditis. A, B) Balanced steady-state free-precession sequences during diastole and systole showing no alteration of the kinetics at the level of the inflamed myocardium. C) T2w short tau inversion recovery sequences showing myocardial edema of the mid lateral wall with a non-ischemic distribution (sub-epicardial) (arrow). D) Phase-sensitive inversion recovery sequences showing late enhancement with same pattern of C (arrow).

wall motion abnormalities [11]. Even if the coronary angiography is considered the gold standard for the visualization of coronary tree, Coronary Compute Tomography coronography plays a central role as a non-invasive instrument that allows the differential diagnosis between acute myo-pericarditis and ischemic heart disease [12].

Cardiac Magnetic Resonance Imaging (CMRI) is acknowledged as the non-invasive gold standard test for myocarditis; the reference diagnostic criteria are those of Lake Louis where the diagnosis of myocardial inflammation is based on at least one T1-based criterion (non-ischemic late enhancement, increased myocardial T1 relaxation times, increased extracellular volume fraction) with at least one T2-based criterion (noticeable myocardial edema, global signal intensity ratio myocardium/skeletal muscle  $\geq 2$ , increased myocardial T2 relaxation times) (Figure 1) [13]. Moreover, CMRI provides important prognostic information in myocarditis; in fact, the presence of Late Gadolinium Enhancement (LGE) is correlated with cardiac mortality with a hazard ratio of 12.8 [14] and with left ventricular dilatation and reduced Ejection Fraction (EF) [15]. The distribution pattern of LGE also matters because major cardiac event and heart failure hospitalization occurred more frequently in patients with an antero-septal involvement [16].

## Histological Findings

Endomyocardial Biopsy (EMB), although considered a gold standard for the diagnostic confirmation of myocarditis, is an invasive procedure that cannot be performed in all patients with suspected COVID-19 myocarditis for various reasons (such as the hemodynamic instability and the associated coagulopathy);

moreover, its sensitivity is limited because myocarditis may be focal or predominantly epicardial which reduces the yield of endomyocardial biopsy. Certainly, it remains the only way to detect the presence of the SARS-CoV-2 genome or to showed virus-negative lymphocytic myocarditis [9]. The histologic classification of myocarditis is traditionally based on the Dallas Criteria which requires evidence of “inflammatory infiltrates within the myocardium associated with myocyte degeneration and necrosis of non-ischemic origin” [17].

## Treatment

The effectiveness of the various treatment strategies currently attempted in cases of COVID-19 myocarditis remains uncertain, given the lack of results from randomized control studies. Glucocorticoids have been widely used despite the lack of proven clinical efficacy, in relation to the pathophysiology of myocarditis [18]. A meta-analysis published in 2019 comparing IV-IG with corticosteroids for acute myocarditis showed that IV-IG therapy improved mortality and recovery of left ventricular function but to date, the evidence does not support the routine use of IV corticosteroids or IV-IGs alone [19].

The optimal management of heart failure and arrhythmias caused by myocarditis is recommended in the guidelines of the European Society of Cardiology, including the use of ACE inhibitors, diuretics, beta-adrenergic blockade, antiarrhythmics and temporary stimulation [11].

## References

- Santacroce L, Charitos IA, Carretta DM, De Nitto E, Lovero R. The human coronaviruses (HCoVs) and the molecular mechanisms of SARS-CoV-2 infection. *J. Mol. Med.* 2021; 93:106.
- World Health Organization. Coronavirus.
- Charitos IA, Ballini A, Bottalico L, Cantore S, Passarelli PC, Inchingolo F, et al. Special features of SARS-CoV-2 in daily practice. *World J. Clin. Cases.* 2020; 8: 3920-3933.
- Jaffe AS, Cleland JGF, Katus HA. Myocardial injury in severe COVID-19 infection. *Eur. Heart J.* 2020; 41: 2080-2082.
- Cazzolla AP, Lovero R, Muzio LL, Testa NF, Schirizzi A, Palmieri G, et al. Taste and Smell Disorders in COVID-19 Patients: Role of Interleukin-6. *Acs Chem. Neurosci.* 2020; 11: 2774-2781.
- Nicin L, Abplanalp WT, Mellentin H, Kattih B, Tombor L, John D, et al. Cell type-specific expression of the putative SARS-CoV-2 receptor ACE2 in human hearts. *Eur. Heart J.* 2020; 41: 1804-1806.
- McMurray JC, May JW, Cunningham MW, Jones OY. Multisystem Inflammatory Syndrome in Children (MIS-C), a Postviral Myocarditis and Systemic Vasculitis-A Critical Review of Its Pathogenesis and Treatment. *Front. Pediatr.* 2020; 8: 626182.
- Thakkar S, Arora S, Kumar A, Jaswaney R, Faisaluddin M, Ammad Ud Din M, et al. A Systematic Review of the Cardiovascular Manifestations and Outcomes in the Setting of Coronavirus-19 Disease. *Clin. Med. Insights Cardiol.* 2020; 14: 1179546820977196.
- Carretta DM, Silva AM, D'Agostino D, Topi S, Lovero R, Charitos IA, et al. Cardiac Involvement in COVID-19 Patients: A Contemporary Review. *Infect Dis Rep.* 2021; 13: 494-517.
- Lakkireddy DR, Chung MK, Gopinathannair R, Patton KK, Gluckman TJ, Turagam M, et al. Guidance for cardiac electrophysiology during the COVID-19 pandemic from the Heart Rhythm Society COVID-19 Task Force; Electrophysiology Section of the American College of Cardiology; and the Electrocardiography and Arrhythmias Committee of the Council on Clinical Cardiology, American Heart Association. *Heart Rhythm.* 2020; 17: e233-e241.
- Caforio AL, Pankuweit S, Arbustini E, Basso C, Gimeno-Blanes J, Felix SB,

- et al. Current state of knowledge on aetiology, diagnosis, management, and therapy of myocarditis: a position statement of the European Society of Cardiology Working Group on Myocardial and Pericardial Diseases. *Eur Heart J*. 2013; 34: 2636-2648.
12. De Stefano D, Parillo M, Garipoli A, Zobel BB. Imaging Findings in a Case of Myo-Pericarditis Associated with SARS-Cov-2 Disease. *J Cardiol Cases*. 2021.
  13. Ferreira VM, Schulz-Menger J, Holmvang G, Kramer CM, Carbone I, Sechtem U, et al. Cardiovascular magnetic resonance in nonischemic myocardial inflammation: expert recommendations. *J Am Coll Cardiol*. 2018; 72: 3158-3176.
  14. Grün S, Schumm J, Greulich S, Wagner A, Schneider S, Bruder O, et al. Long-term follow-up of biopsy-proven viral myocarditis: predictors of mortality and incomplete recovery. *J Am Coll Cardiol*. 2012; 59: 1604-1615.
  15. Kindermann I, Kindermann M, Kandolf R, Klingel K, Bültmann B, Müller T, et al. Predictors of outcome in patients with suspected myocarditis. *Circulation*. 2008; 118: 639-648.
  16. Aquaro GD, Perfetti M, Camastra G, Monti L, Dellegrottaglie S, Moro C, et al. Cardiac Magnetic Resonance Working Group of the Italian Society of Cardiology. Cardiac MR with Late Gadolinium Enhancement in Acute Myocarditis with Preserved Systolic Function: ITAMY Study. *J Am Coll Cardiol*. 2017; 70: 1977-1987.
  17. Aretz HT, Billingham ME, Edwards WD, Factor SM, Fallon JT, Fenoglio JJ, et al. Myocarditis. A histopathologic definition and classification. *Am J Cardiovasc Pathol*. 1987; 1: 3-14.
  18. Hasan SS, Capstick T, Ahmed R, Kow CS, Mazhar F, Merchant HA, et al. Mortality in COVID-19 patients with acute respiratory distress syndrome and corticosteroids use: A systematic review and meta-analysis. *Expert Rev. Respir. Med*. 2020; 14: 1149-1163.
  19. Li Y, Yu Y, Chen S, Liao Y, Du J. Corticosteroids and Intravenous Immunoglobulin in Pediatric Myocarditis: A Meta-Analysis. *Front. Pediatr*. 2019; 7: 342.