

## Case Report

# Tyre Explosion Ocular Injury

**Rathi M\*, Bhatt N, Dhull CS, Sachdeva S, Phogat J**  
Department of ophthalmology, Regional Institute of Ophthalmology, PGIMS, India

\*Corresponding author: Manisha Rathi, Department of Ophthalmology, Rathi Nursing Home, Sonapat road, Rohtak, Haryana, India

**Received:** July 04, 2016; **Accepted:** August 16, 2016;  
**Published:** August 17, 2016

## Abstract

A 35 year old patient presented with gross and sudden diminution of vision in both eyes following injury due to bursting of the bullock cart tyre while he was inflating it. There is a meteoric rise in DIY (Do It Yourself) injuries worldwide. Isolated tyre burst bilateral ocular injuries have never been seen before in our clinical practice or reported in literature. These injuries, though rare, can lead to permanent visual impairment and blindness. Often the ophthalmologist has to rely on experience and instinct and a closely monitored follow up to save the eyes.

**Keywords:** Ocular injury; Tyre burst

## Introduction

Tyre burst injury is a type of an explosion injury which is rarely encountered. In today's world these injuries are a potential threat due to an exponential increase in the use of vehicles and the trend of DIY. The severity of the injuries depends on the size of the tyre, the contained air pressure, and the distance between the tyre and the victim [1]. There are only a handful of case reports with ocular injuries due to a tyre burst reported in literature throughout the world. Many fatal and severely deforming injuries affecting the extremities have been reported but very few articles are published on ocular involvement due to tyre burst [2-5].

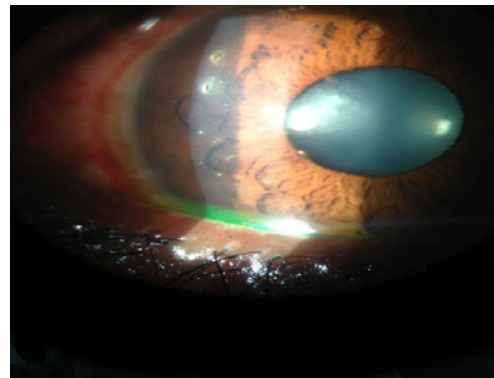
## Case Report

A 35 year old male patient, farmer by occupation, visited our out-patient department with chief complaints of diminution of vision, pain, redness, photophobia and watering of two hours duration following tyre burst bilateral ocular injury. This injury was sustained while he was inflating the old and frayed tyre of his bullock cart to save money. Symptoms were more in the right eye as compared to the left eye. Patient was not wearing glasses at the time of incident. He reached hospital within two hours of the incident. Initial visual acuity was hand movement in right eye and 6/60 in left eye. On slit lamp examination, there was lid edema, superficial conjunctival congestion and multiple black fragments on and within the cornea and conjunctiva of both eyes at various depths. Foreign bodies were embedded in the epithelium and stroma of the cornea. There were multiple foreign bodies in the congested conjunctiva. Fluorescein stain was positive in both eyes. Posterior segment of both eyes was normal. Foreign bodies were removed under topical anaesthesia under microscope. Foreign bodies were removed from cornea and conjunctiva using 26 gauge needle taking care to keep the tip bevel of the needle upwards, away from the eye. Both eyes were patched with Moxifloxacin ointment for 24 hours. The next day, the vision was 6/24 in the right eye and 6/12 in the left eye. With close monitoring and removal of as many foreign bodies as possible without endangering the eye and topical treatment with antibiotic, NSAID, lubricant eye drops he regained visual acuity of 6/6 in both eyes with -0.5 ds correction. Since references of this injury were limited in the available literature, we had to rely on clinical judgment it was decided that the deeper foreign bodies in the cornea would be left as such to avoid

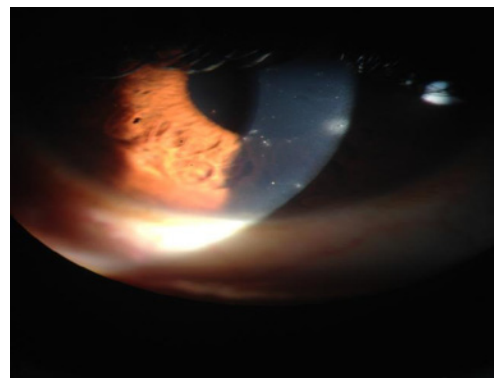
permanent opacities, inflammation and permanent damage to the cornea. It was observed that they were inert and there was no harmful effect on the eye over a period of one year follow up.

## Discussion

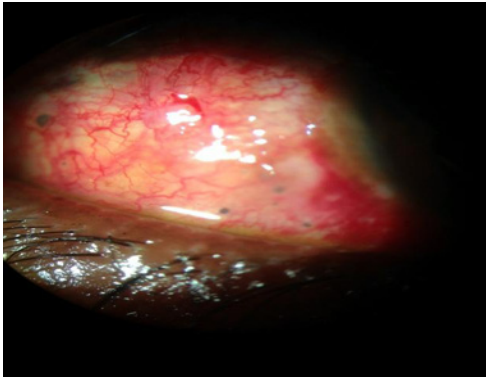
Worldwide, there are very few case reports of ocular injuries due to tyre burst. In the available literature, there is no case report of bilateral ocular injury without any systemic involvement due to a bullock cart tyre burst as part of a Do-It-Yourself injury. We were able to find only 1 case report similar to our case that also due to explosion of tyre of a tractor [6].



**Figure 1:** Right eye showing multiple fragments over cornea.



**Figure 2:** Left eye showing multiple fragments over cornea.



**Figure 3:** Multiple fragments embedded in conjunctiva.

Timely treatment based on clinical judgment and a close follow up is essential to restore vision. Such kind of injuries can lead to permanent visual disability/blindness if not managed properly. One should wear protective glasses or helmet while inflating the tyre and only experienced person should inflate tyres as they know when to stop. Based on our experience, the foreign bodies of such an injury can be left in the cornea if they are deeply embedded in the stroma as they are inert and do not cause any long term damage to the eye.

The socioeconomic aspect of this injury is significant. In third world countries tyres continue long past their prescribed limit, these tyres are more prone to be over inflated and give way. This can lead to severe morbidity and mortality.

## Conclusion

The practice of Do It Yourself by untrained personnel to save time and money should be discouraged. The public should be educated about health hazards due to these practices. In our case the foreign

bodies were embedded deep inside the stroma of the cornea in both eyes but did not involve the pupillary area, hence the patient has a vision of 6/6. It is often seen that an acute injury can lead to a chronic condition, which necessitates a life-long follow up, which is the case in the patient discussed above. In effect, any condition which requires treatment or regular follow up of more than 3 months is considered chronic.

Although our patient has a vision of 6/6 which is stable over a one year follow up, he has foreign body sensation due to mild dry eye because of the permanent damage caused to the conjunctiva and cornea caused by the injury. His symptoms are alleviated by tear supplements. Hence, he has been advised to be on a regular follow up of 3 months. Cases for which a treatment protocol does not exist should be reported and documented so that proper guidelines can be created and followed.

## References

1. Rautji R, Rudra A, Dogra TD. An unusual fatal injury due to tyre burst: a case report. *Forensic SciInt.* 2003; 138: 111-113.
2. Hefny A, Eid O, Al-Bashir M, Abu-Zidan M. Blast injuries of large tyres. *International journal of surgery* 2010; 8: 151-154.
3. Hefny AF, Eid HO, Abu-Zidan FM. Severe tyre blast injuries during servicing. *Injury.* 2009; 40: 484-487.
4. Teasdall RD, Aiken MA, Freeland AE. Tyre explosion injuries. *Orthopedics.* 1989; 12:123-128.
5. Sheperd RS, Ziccardi VB, Livingston D. Trauma from tyre and rim explosions: a retrospective analysis. *J OralMaxillofac Surg.* 2004; 62: 36-38.
6. Levy J, Kratz A, Lifshitz T. Eye injuries due to tractor wheel explosion: report of two cases. *Can J Ophthalmol.* 2005; 40: 747-749.