

## Case Report

# Early Anterior Temporal Artery Can Masquerade as Patent Middle Cerebral Artery on Transcranial Doppler in Acute Ischemic Stroke

Reza Bavarsad Shahripour<sup>1</sup>, Gyanendra Kumar<sup>1</sup>, Michal Haršány<sup>3</sup> and Andrei V. Alexandrov<sup>1,2\*</sup>

<sup>1</sup>Comprehensive Stroke Center, Department of Neurology, University of Alabama at Birmingham, USA

<sup>2</sup>Department of Neurology, The University of Tennessee Medical Center, USA

<sup>3</sup>Department of Neurology, St. Anne's University Hospital and Medical Faculty of Masaryk University, Czech Republic

\*Corresponding author: Andrei V. Alexandrov, Semmes-Murphey Professor and Chairman, Department of Neurology, The University of Tennessee Health Science Center, 855 Monroe Avenue, Suite 415, Memphis, TN 38163, USA, Tel : 901 448 6199; Fax: 901 448 7440; Email: avalexandrov@att.net

Received: July 01, 2014; Accepted: October 13, 2014;

Published: October 15, 2014

## Introduction

The ATA is the first major branch of the MCA arising proximal or opposite to the origin of the lenticulostriate branches in some subjects and distal to the lenticulostriate arteries in others [1]. This artery courses over the superior surface of the temporal pole and the anterior temporal lobe into the Sylvian fissure where it gives off the anterior and temporal branches [1].

The early ATA takes off the M1 segment of the MCA, provides collateral supply in the event of an MCA occlusion, and is a favorable prognostic sign in acute ischemic stroke [2,3]. Detection of flow in the ATA by TCD has been described but the literature as to how it can affect accuracy of TCD in detection of the MCA occlusion is limited [4,5].

TCD accuracy in detection of acute proximal intracranial occlusions is the highest for the M1 MCA segment ranging from 88.6% to 100%. [5] We report a patient with acute ischemic stroke due to M1 MCA occlusion and TCD findings of patent ATA that could have led to a false negative TCD interpretation.

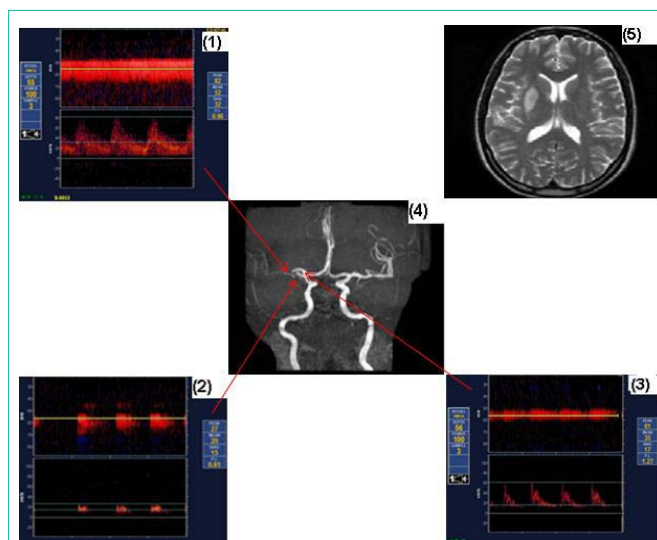
## Case Presentation

A thirty nine year old right-handed woman with a history of hypertension, hyperlipidemia, and smoking presented with a left-sided facial droop, weakness and numbness in the left extremities. A total NIH Stroke Scale (NIHSS) score was 18 and she was outside time window for thrombolysis. Fast track TCD examination (in 20 minutes after presentation in the ER) demonstrated a low resistance flow towards the probe at motion-mode depth range from 65 mm to 48 mm depth (Figure, Panel 1), and normal Doppler spectral waveform at the depth 55 mm: mean flow velocity [MFV] 52 cm/s; pulsatility index [PI] 0.98. Given the discrepancy between the clinical presentation,

## Abstract

The anterior temporal artery (ATA) is the first branch of the middle cerebral artery (MCA). This branch can alter the morphology of the MCA waveform when the MCA is sampled proximal to an occlusion. When present, it can result in spurious interpretation of the Transcranial Doppler (TCD) as a normal study in a patient with M1 occlusion. Here we describe TCD findings in a patient with M1 MCA occlusion with an early ATA branch.

consistent with a proximal MCA occlusion (NIHSS score of 18 points for the right hemispheric stroke), and initial TCD findings further TCD examination through different aspects of the right temporal bone window was performed. The second TCD exam is performed in 3 hours and half after her first visit in the E.R (30 minutes after reading MRI and MRI). TCD showed two more vessel intercepts at the same depth range and variable angulation of the transducer. Both of these vessel samples (Figure, Panels 2 and 3) had high resistance flow signatures on motion-mode displays and abnormal waveforms



**Figure:** Panel 1, 2, 3: Low resistance flow (Panel 1), Thrombolysis In Brain Ischemia (TIBI) grades 1 (Minimal; Panel 2) and 3 (Dampened; Panel 3). Panel 4, 5: MRA and MRI-T2 within 24 hours after stroke symptom onset in patients.

corresponding to Thrombolysis In Brain Ischemia (TIBI) grades 1 (Minimal; Panel 2) and 3 (Dampened; Panel 3). Both waveforms displayed flow towards the transducer.

Brain MRA showed a right M1 MCA occlusion with early ATA branching at the proximal M1 segment (Figure, Panel 4), and MRI showed a right basal ganglia, deep white matter, and, temporal opercular infarction (Figure, Panel 5). The infarct was smaller than expected from the occlusion location in the proximal (M1) MCA. (The MRI/MRI (stroke protocol) is performed and read by neuro-radiologist in three hours after her presentation in the ER)

## Discussion

Our case report illustrates the need for fast track examinations with TCD not to settle on the first detectable blood flow signal and to be further driven by clinical examination as to the suspected location of an acute intracranial occlusion. Knowledge of variable ATA anatomy can avoid false negative diagnosis of proximal MCA occlusions [3]. Of note, our patient did not have flow diversion to the anterior cerebral artery on TCD – a finding that could have further led to a false negative TCD diagnosis.

ATA is a normal anatomical variant with unknown prevalence in terms of its early origin. Its presence is associated with reduced mortality in patients with M1 occlusion and it can be easily identified on axial and coronal sections of a brain CT- and MR-angiography [3]. TCD has complimentary value to CTA in the acute phase of stroke [6]. For example, it can show reversal of flow and transient emboli (both phenomena cannot be seen on CTA or MRA). In addition, it can point to location of non-occlusive thrombi (focal bruit or artery-to-artery embolization), or branch occlusions (flow diversion). These TCD findings can help interpret CTA results. Furthermore, TCD can help identify the pathogenic mechanism of stroke. Nevertheless,

reliance on a single vessel intercept during fast track TCD can lead to misinterpretation of a patent ATA as MCA. Moreover, patent early ATA can alter the morphology of the M1 MCA waveform sampled proximal to the occlusion since it provides a branching point where both systolic and diastolic flows can be diverted to a low resistance brain tissue not affected by severe ischemia or distal embolization. To minimize error we recommend using power mode Doppler (PMD) or similar motion mode multi-depth displays to search for more subtle near-occlusive flow signals that can be identified in locations close to ATA. Normal flow spectra presumably detected from the MCA in patients with high NIHSS scores should be questioned at the time of bedside examination. TCD examination should be extended and vascular imaging such as CTA or MRA can supplement TCD examination when discrepancy is noted.

## References

1. Fisher M. Left hemiplegia and motor impersistence. *J Nerv Ment Dis.* 1956; 123: 201-218.
2. Babikian V, Sloan MA, Tegeler CH, DeWitt LD, Fayad PB, Feldmann E, et al. Transcranial Doppler validation pilot study. *J Neuroimaging.* 1993; 3: 242-249.
3. Menon BK, Bal S, Modi J, Sohn SI, Watson TW, Hill MD, et al. Anterior temporal artery sign in CT angiography predicts reduced fatal brain edema and mortality in acute M1 middle cerebral artery occlusions. *J Neuroimaging.* 2012; 22:145-148.
4. Moppett IK, Mahajan RP. Transcranial Doppler ultrasonography in anaesthesia and intensive care. *Br J Anaesth.* 2004; 93: 710-724.
5. Razumovsky AY, Oppenheimer SM. TCD in acute stroke. *Stroke.* 2000; 31: 234-235.
6. Tsvigoulis G, Ribo M, Rubiera M, Vasdekis SN, Barlinn K, Athanasiadis D, et al. Real-time validation of transcranial Doppler criteria in assessing recanalization during intra-arterial procedures for acute ischemic stroke: an international, multicenter study. *Stroke.* 2013; 44: 394-400.