

Editorial

Therapeutic Approaches for Patients with Acute Ischemic Stroke: IV t-PA, Endovascular/Catheter-based Intervention, or Both?

Lopez JI, Rothrock JF and Cortez JV
 Department of Internal Medicine, University of Nevada, USA

*Corresponding author: Lopez JI, Department of Internal Medicine, University of Nevada, Reno School of Medicine, USA, Email: JLopez@renown.org

Received: July 15, 2014; Accepted: August 15, 2014; Published: August 19, 2014

Data derived from the National Institute of Neurological Disorders and Stroke study published in 1995 indicate- that compared to placebo, intravenous IV administration of tissue plasminogen activator (IV-tPA) within 3 hours of ischemic stroke onset resulted

in no or minimal stroke-related deficit in about 30% of the study's subjects three months following stroke [1]. Advances in patient selection, mobilization of resources, and other factors have led to the current standard of practice wherein IV t-PA may be administered safely and with potential benefit to the majority of patients who present within 4.5 hours of ischemic stroke onset [2,3].

The Interventional Management of Stroke (IMS) Trial III studied the effectiveness of using IV t-PA in combination with endovascular therapy versus IV t-PA alone for patients with moderate-to-severe acute ischemic stroke. The study showed similar safety outcomes and no significant benefit from combined therapy compared to using IV t-PA alone [4]. Another study, the SYNTHESIS (Local Versus

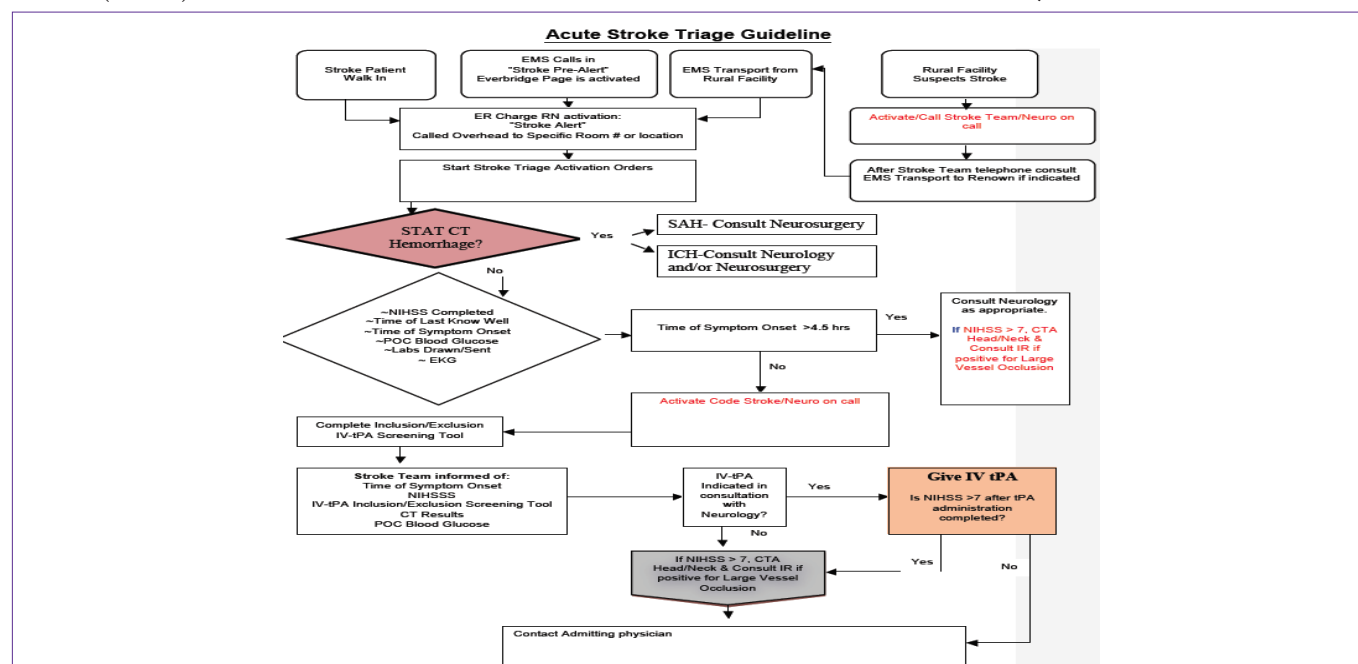


Figure 1: Acute Stroke Triage Guideline at Renown Regional Medical Center (Reno, NV):

As shown in the above figure that represents the acute stroke triage guidelines at Renown Regional Medical Center (RRMC) in Reno, NV, a patient can walk in to the emergency room (ER) or present through emergency medical services (EMS) within the city. Additionally, RRMC serves as a tertiary care center for several surrounding rural communities. These rural communities have an agreement with RRMC to transport suspected stroke patients through EMS to RRMC. When the ER charge registered nurse (RN) is aware of these patients, he/she will notify the appropriate health care providers through overhead alert, and stroke triage activation orders are initiated. A stat computed tomography (CT) scan of the brain is performed to evaluate for hemorrhage. If there are signs of subdural or intracranial hemorrhages (SAH or ICH, respectively) neurosurgery is consulted for further evaluation. If there are no signs of hemorrhage appreciated on the brain CT scan, information such as time of symptom onset and information to calculate NIHSS score are gathered. Laboratory information such as prothrombin time, international normalized ratio (INR), partial thromboplastin time (PTT), glucose, and other such information, is also sought at this time. If the patient who presents has had his/her symptoms for more than 4.5 hours and as a NIHSS score of greater than 7, a CT angiogram (CTA) of the head/neck is performed, and interventional radiology (IR) is consulted if there is evidence of a large vessel occlusion. If the patient presents within the 4.5 hour time period, a "code stroke" is activated, and the on-call neurologist is notified. The patient is screened for IV-tPA inclusion criteria, and the patient's other laboratory data is evaluated for possible contraindications to IV-tPA therapy. If the patient presents within 4.5 hours and meets the inclusion criteria for IV-tPA, the patient is given IV-tPA. If the patient does not meet the inclusion criteria for IV-tPA (and has a NIHSS score of greater than 7) or if the patient still has a NIHSS score of greater than 7 following tPA, a CTA of the head/neck is performed, and IR is consulted if there is evidence for a large vessel occlusion. Following administration of IV-tPA and/or consultation with interventional radiology, the admitting physician from the internal medicine service is informed.

Systemic Thrombolysis for Acute Ischemic Stroke)-Expanded) trial, similarly failed to demonstrate any advantage from the use of endovascular treatment for acute ischemic stroke relative to the use of IV t-PA alone [5]. These studies did not evaluate the utility of using endovascular therapy alone as a primary approach to treating ischemic stroke, especially in cases where there was a significant bleeding risk consequent to thrombocytopenia, use of oral anticoagulants, or other factors. The MR-Rescue (Mechanical Retrieval and Recanalization of Stroke Clots Using Embolectomy) trial compared the use of standard non-endovascular care with the use of mechanical recanalization and clot retrieval in patients who presented with acute ischemic stroke, and embolectomy was not shown to be superior to the standard of care [6]. It should be noted that in the MR Rescue Trial-an INR greater than 3.0 was an exclusion criteria, and since the study was performed more technologically advanced devices have become available for use.

Although there is currently insufficient scientific evidence to demonstrate the utility of using endovascular therapies to treat acute ischemic stroke in patients, it seems likely that there are some patients who may benefit from those therapies. At Renown Regional Medical Center (Reno, NV), we have implemented a management algorithm for patients who present with acute ischemic stroke that includes the potential for endovascular intervention (Figure).

In brief, if a patient presents within 4.5 hours of stroke onset, CT neuroimaging shows no evidence of intracranial hemorrhage, and there are no other laboratory or clinical exclusion criteria present, IV t-PA is administered. . If the patient presents with an initial National Institutes of Health Stroke Scale score of > 7, CT angiography (CTA) is performed immediately following initiation of the IV t-PA infusion; if the CTA demonstrates evidence of symptomatic large vessel occlusion and the patient has failed to improve 1 hour post completion of the t-PA infusion, interventional radiology is consulted for possible endovascular treatment.

If a patient presents within 4.5 hours of ischemic stroke onset, is ineligible for IV t-PA, has CTA evidence of symptomatic large vessel

occlusion and on clinical grounds is considered to be an appropriate candidate for endovascular therapy, interventional radiology is consulted.

Our management algorithm clearly represents an amalgamation of evidence-based therapy and therapeutic interventions whose utility in selected cases is suspected to exist but remains unproven. While “absence of proof” is not synonymous with “proof of absence” regarding therapeutic benefit from endovascular therapy for acute ischemic stroke, such therapy should be utilized judiciously and only in those cases wherein the risk resulting from IV t-PA therapy only or no stroke-specific treatment whatsoever appears to equal or exceed the risk of endovascular therapy. Data from anticipated clinical research hopefully will define for us more clearly what specific role catheter-based therapy should assume in the management of acute ischemic stroke.

References

- [No authors listed]. Tissue plasminogen activator for acute ischemic stroke. The National Institute of Neurological Disorders and Stroke rt-PA Stroke Study Group. *N Engl J Med.* 1995; 333: 1581-1587.
- Powers WJ. Endovascular (intraarterial) treatment of acute ischemic stroke: efficacy not supported by clinical trials. *South Med J.* 2014; 107: 101-106.
- Hacke W, Kaste M, Bluhmki E, Brozman M, Dávalos A, Guidetti D, et al. Thrombolysis with alteplase 3 to 4.5 hours after acute ischemic stroke. *N Engl J Med.* 2008; 359: 1317-1329.
- Broderick JP, Palesch YY, Demchuk AM, Yeatts SD, Khatri P, Hill MD, et al. Endovascular therapy after intravenous t-PA versus t-PA alone for stroke. *N Engl J Med.* 2013; 368: 893-903.
- Ciccone A, Valvassori L, Nichelatti M, Sgoifo A, Ponzio M, Sterzi R, et al. Endovascular treatment for acute ischemic stroke. *N Engl J Med.* 2013; 368: 904-913.
- Kidwell CS, Jahan R, Gornbein J, Alger JR, Nenov V, Ajani Z, et al. A trial of imaging selection and endovascular treatment for ischemic stroke. *N Engl J Med.* 2013; 368: 914-923.