

Case Report

Lipomatous Hypertrophy of Interatrial Septum
Presenting with Two Distinct Atrial ArrhythmiasZargarian E^{1*}, Rochon-Duck ME² and Donaldson DM²¹Department of Medicine, University of California - Irvine, USA²Division of Cardiology, Department of Medicine, University of California - Irvine, USA***Corresponding author:** Emin Zargarian, Department of Medicine, University of California, Irvine, 333 The City Blvd W, Suite 400, Orange, CA 92868, USA**Received:** September 21, 2021; **Accepted:** October 14, 2021; **Published:** October 21, 2021

Abstract

Lipomatous Hypertrophy of the Interatrial Septum (LHIS) is usually a benign condition, but it has been known to produce a variety of symptoms and arrhythmias. Management is guided by symptoms and can range from watchful waiting to surgical resection. Here we describe a unique case of a patient with LHIS associated with two distinct atrial arrhythmias. Due to persistent symptoms an EP study with ablation was pursued which resulted in abatement of symptoms. This case illustrates that an EP study and ablation is a viable option that could be considered in patients with continued symptoms in conjunction with medical or surgical options and ultimately lead to prompt diagnosis and appropriate treatment.

Keywords: Electrophysiology; Arrhythmias; Atrial tachycardia; Atrial fibrillation; Cardiac tumors; Cardiac imaging

Case Presentation

Lipomatous Hypertrophy of the Interatrial Septum (LHIS) is a non-malignant deposition of lipid vacuoles in the septum [1]. Symptoms may include right atrial inflow obstruction [2], variety of supraventricular arrhythmias and even sudden death [3,4]. Here we describe a unique case of a patient with LHIS associated with two distinct atrial arrhythmias and the management that followed. The reader of this article should be able to recognize the clinical presentation of LHIS, the radiographic and ECG findings of this condition, identify the variety of arrhythmias associated with it and learn the management options of persistently symptomatic patients with LHIS.

A 63-year-old woman had a six-month history of palpitations, which were now occurring multiple times daily, presented to an outside hospital after recurrent syncopal episodes. These episodes resulted in trauma and a motor vehicle accident. An echocardiogram showed a partially obstructive 2.1 x 3.7 cm right atrial mass which was thought to be associated with her symptoms. She was transferred

to our hospital for consideration of surgical management. During her hospitalization, she had multiple episodes of symptomatic Supraventricular Tachycardia (SVT) at 140 bpm and a brief episode of a second different SVT at 110 bpm, which was suggestive of atrial flutter. Despite increasing doses of Metoprolol and Digoxin, symptomatic episodes of SVT at 140 bpm continued to recur.

The patient had no prior medical history and did not take any medications. Her father had a myocardial infarction in his third decade of life and a second in his fifth decade of life, while her mother had a cardiac arrest in her seventh decade of life.

Exam was unremarkable with a BMI of 20kg/m². Basic laboratory values were within normal limits. Echocardiogram revealed thickened atrial septum near the fossa ovalis measuring 2.0 cm x 3.5 cm, but otherwise normal atrial size (Figure 1). Cardiac MRI revealed a large dumbbell shaped expansion of the atrial septum with fat signal intensity sparing the fossa ovalis (Figure 2). Coronary angiography revealed normal coronaries.

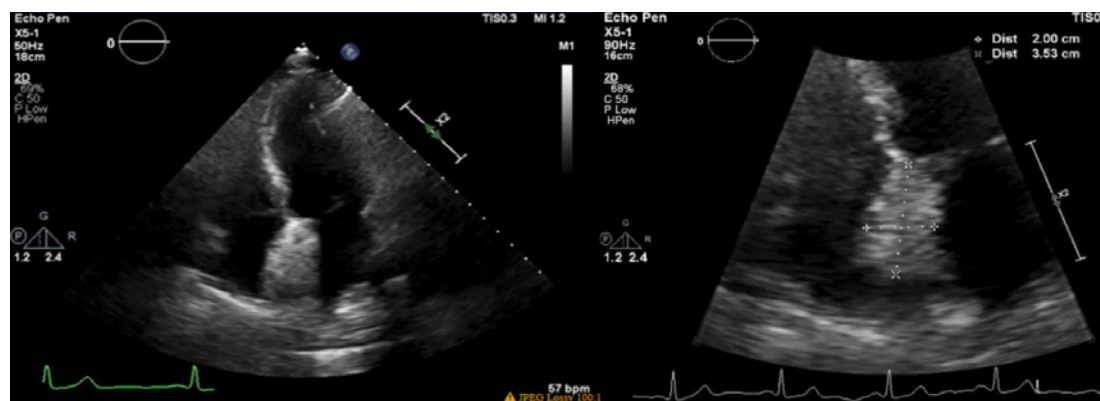


Figure 1: Transthoracic echocardiogram images. Left: 4-chamber view demonstrating thickening of the interatrial septum in the area of fossa ovalis. Right: Zoomed in view of the interatrial mass measuring 2 cm x 3.5 cm in thickness.

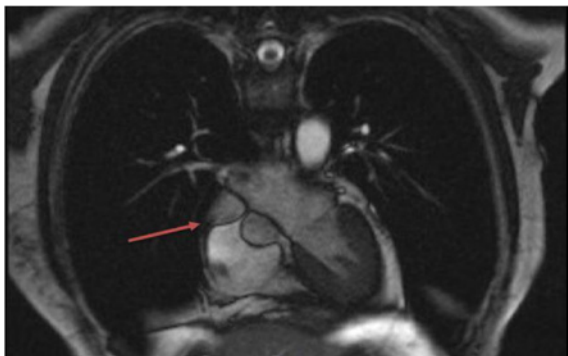


Figure 2: T1 weighted images from Cardiac MRI showing “dumbbell shaped” appearance of the atrial septum.

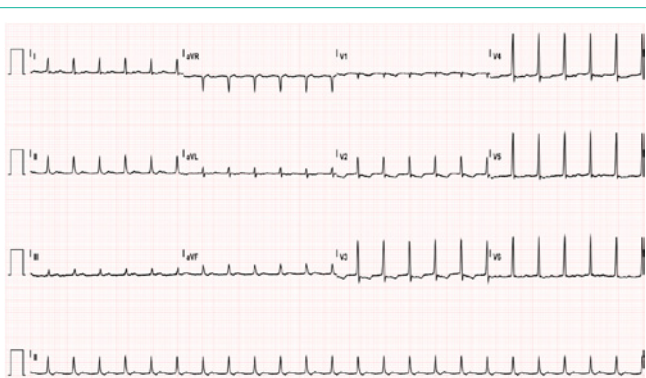


Figure 3: Electrocardiogram performed after surgical resection showing supraventricular tachycardia with tachycardia cycle length at a rate of 142 bpm. In leads I, II, III, AVF, AVL, V3-V6 there is evidence of deflections in the ST segment consistent with possible retrograde P waves.

Surgical resection with bovine patch repair was offered due to the severity of her clinical presentation, with resection of the atrial septal mass with adipose deposits consistent with lipomatous hypertrophy of the interatrial septum. Post operatively, the patient continued to have highly symptomatic supraventricular tachycardia at 140-150 bpm and three days post operatively she had episodes of sustained atrial flutter at 110 bpm. Her electrocardiogram revealed supraventricular tachycardia with tachycardia cycle length of 142 bpm and evidence of deflections in the ST segment in leads I, II, III, AVF, AVL, V3-V6 consistent with possible retrograde P waves (Figure 3). An Electrophysiology (EP) study was offered. EP study revealed easily inducible typical counterclockwise right atrial flutter circuit utilizing the cavotricuspid isthmus. Standard pacing maneuvers with Biosense Webster CARTO 3 mapping system including entrainment mapping on the cavotricuspid isthmus confirmed the diagnosis. Radiofrequency ablation with Biosense Webster CARTO 3 mapping system was performed along the cavotricuspid isthmus line with termination of the atrial flutter and bidirectional block. In the waiting period, atrial stimulation protocol easily induced a narrow complex tachycardia and standard pacing maneuvers confirmed the diagnosis of typical Atrioventricular Nodal Reentry Tachycardia (AVNRT). Radiofrequency modification of the slow pathway was performed. The patient was non-inducible with pacing to Wenckebach cycle length and also rapid atrial pacing at 250 milliseconds at the completion of the study. She did well post

procedure and was symptom free at the time of discharge. She was discharged with 3 months of anticoagulation with apixaban post ablation. Ambulatory ECG monitoring using Ziopatch device for 14 days did not reveal any recurrence of her AVNRT or atrial flutter. Her CHA_2DS_2 -VASc score was calculated to be 1. She was transitioned to aspirin for stroke prevention.

Discussion

Lipomatous Hypertrophy of the Interatrial Septum (LHIS) is usually a benign condition. It was first described in autopsy reports in 1963 [5]. It is becoming increasingly recognized due to availability of imaging modalities [6]. It is found more commonly in women, patients over the age of 50, and is associated with obesity [3]. No formal diagnostic criteria have been devised; however, it is typically characterized by atrial septal thickness of >2 cm and characteristic “dumbbell” shaped appearance of the septum sparing the fossa ovalis membrane found on imaging [3]. Clinically, patients are generally asymptomatic, however there are associated symptoms in rare cases. A wide variety of supraventricular arrhythmias have been described including premature atrial complexes, atrial fibrillation, and atrial tachycardia [3,6]. The mechanism by which LHIS causes arrhythmias is unknown. Since the lipid accumulation occurs along the interatrial septum and the right atrial wall, it is suspected that it infiltrates the atrial conduction pathways resulting in disruption and fibrosis. The disorganized fibers ultimately result in impairment of electrical conduction and lead to the arrhythmias described [2,7]. This is further evidenced by cases where the infiltration extends into the conduction fibers of the Atrioventricular (AV) node resulting in complete AV node block [8].

In our case, we can postulate that the flutter may have been caused by fatty infiltration from the LHIS. The echocardiogram did not reveal enlarged atria or signs of atrial obstruction to make us suspect atrial remodeling as the underlying cause. It is unclear if AVNRT is related to the lipomatous infiltration process.

Surgical resection and repair is warranted in cases of high risk or life-threatening symptoms and arrhythmias [9]. Surgical resection can potentially result in termination of the arrhythmia [2]. Further investigations and treatments are warranted in cases like the one presented here, due to the persistence of the arrhythmia and symptoms after surgical resection of the mass.

To our knowledge, this is the first case of two distinct atrial arrhythmias, typical right atrial flutter and AVNRT, occurring in the same patient with LHIS. It is important to remain vigilant about this possibility and thoroughly evaluate persistently symptomatic patients. As illustrated by this case, EP study and radiofrequency ablation is an option that could be considered in patients with continued symptoms in conjunction with medical or surgical options and ultimately lead to prompt diagnosis and appropriate treatment.

References

1. Cannavale G, Francone M, Galea N, et al. Fatty Images of the Heart: Spectrum of Normal and Pathological Findings by Computed Tomography and Cardiac Magnetic Resonance Imaging. *Biomed Res Int.* 2018; 2018: 5610347.
2. Dickerson JA, Smith M, Kalbfleisch S, Firstenberg MS. Lipomatous hypertrophy of the intraatrial septum resulting in right atrial inflow obstruction and atrial flutter. *Ann Thorac Surg.* 2010; 89: 1647-1649.

3. Heyer CM, Kagel T, Lemburg SP, Bauer TT, Nicolas V. Lipomatous hypertrophy of the interatrial septum: a prospective study of incidence, imaging findings, and clinical symptoms. *Chest*. 2003; 124: 2068-2073.
4. Arbarello P, Maiese A, Bolino G. Case study of sudden cardiac death caused by lipomatous hypertrophy of the interatrial septum. *Med Leg J*. 2012; 80: 102-104.
5. Prior Jt. Lipomatous Hypertrophy of Cardiac Interatrial Septum. A Lesion Resembling Hibernoma, Lipoblastomatosis and Infiltrating Lipoma. *Arch Pathol*. 1964; 78: 11-15.
6. Shirani J, Roberts WC. Clinical, electrocardiographic and morphologic features of massive fatty deposits ("lipomatous hypertrophy") in the atrial septum. *J Am Coll Cardiol*. 1993; 22: 226-238.
7. Laura DM, Donnino RM, Kim EE, Benenstein RJ, Freedberg RS, Sarić M. Lipomatous atrial septal hypertrophy: a review of its anatomy, pathophysiology, multimodality imaging, and relevance to percutaneous interventions. *J Am Soc Echocardiogr*. 2016; 29: 717-723.
8. Zubin Yavar, Jasen L. Gilge, Parin J. Patel, Amit C. Patel, Rafael S. Garcia-Cortes, Julie K. Fetters, et al. Lipomatous Hypertrophy of the Interatrial Septum Manifesting as Third Degree Atrioventricular Block. *JACC: Case Reports*. 2020; 2: 2235-2239.
9. Ampatzidou F, Koutsogiannidis CP, Cheva A, Vasiliadis K, Drossos G. Surgical treatment of atrial septum lipomatous hypertrophy associated with syncopal attacks. *Ann Card Anaesth*. 2018; 21: 319-320.