

Letter to the Editor

Cardiac Myxomas and Carcinomas: Is it Incidental or Consequential Finding?

Alizadehasl A^{1#}, Samimi S^{2#} and Sanadgol G^{3*}¹Professor of Cardiology, Echocardiologist, Cardio-Oncologist Head of Cardio-Oncology Department & Research Center Rajaie Cardiovascular Medical & Research Center, Iran University of Medical Science, Tehran, Iran²Tehran Heart Center, Tehran University of Medical Sciences, Tehran, Iran³Cardiovascular Research Center, Shahid Beheshti University of Medical Sciences, Tehran, Iran[#]Contributed Equally to this Work***Corresponding author:** Ghazal Sanadgol, Cardiovascular Research Center, Shahid Beheshti University of Medical Sciences, Tehran, Iran**Received:** August 30, 2021; **Accepted:** September 13, 2021; **Published:** September 20, 2021

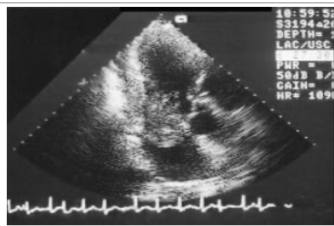
Letter to the Editor

Myxoma is the most common primary intracardiac neoplasm, ranging between 0.001% to 0.03% in the general population [1]. Cardiac myxomas are most frequently located in the left atrium in 80% of cases, with the remainder mostly originating from the right atrium [2]. Patients may present with various cardiovascular manifestations depending on the anatomical location (e.g., cardiac arrhythmia, embolization,...). It may also present with nonspecific constitutional sign and symptoms such as fever and weight loss [3,4].

The association between cardiac myxomas and other simultaneous tumors has previously been described in the case of carney complex. Carney complex is a rare autosomal dominant syndrome caused by abnormalities in the PRKARIA gene [5]. Patients may present with skin pigmentations and a variety of endocrine and non-endocrine tumors [5]. However, multiple reports of cardiac myxomas in patients with synchronous primary tumors have been reported, speculating that cardiac myxomas may simultaneously be present with other primary cancers, not classified as the carney complex.

A variety of malignancies have been documented that coincide

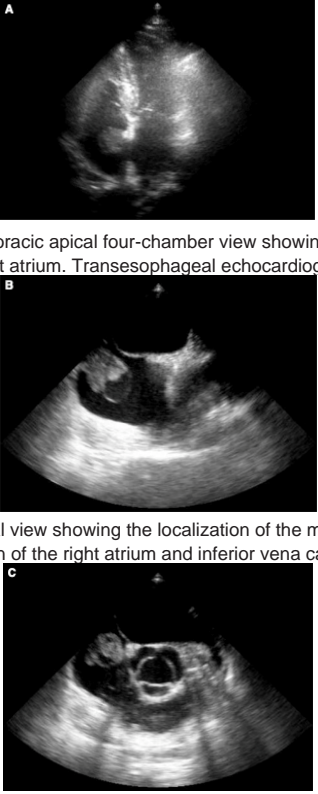
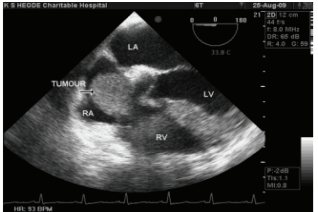

Table 1: Previous studies: Association of myxomas and other carcinomas.

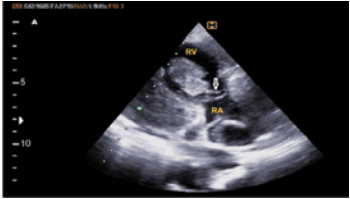
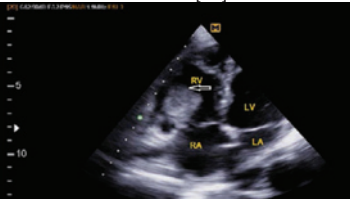
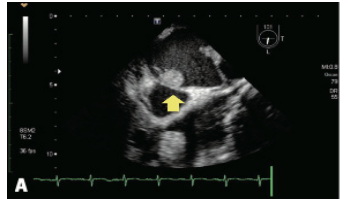
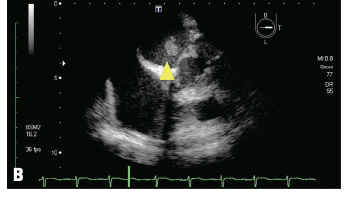
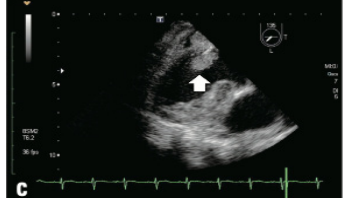
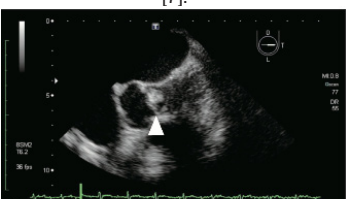
Year	Authors	Title of Article	Associated Carcinoma	Location of Cardiac Myxoma(s)	Images
2001	Nuño IN et al. [9]	Synchronous cardiac myxoma and colorectal cancer: a case report	Colon Carcinoma (sigmoid)	Left atrium and protruding into the left ventricle	 <p>Transesophageal 4-chamber echocardiogram shows the left atrial mass protruding into the left ventricle and lodged in the mitral valve [9].</p>

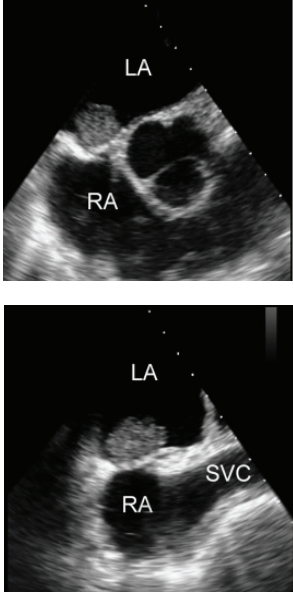
with cardiac myxomas over the years. Meir et al., encountered a left atrial myxoma in the echocardiography of a 51-year-old woman presenting with fever after receiving first chemotherapy session for invasive lobular adenocarcinoma [6]. The association between breast adenocarcinoma and cardiac myxoma was also reported by Kataoka et al. and Özer et al. [7,8]. Nuño et al. and Hajsadeghi et al., described synchronous colorectal carcinomas with a cardiac myxoma [9,10].

Lazos-Ochoa et al., detected a left atrial cardiac myxoma in the autopsy of a 60-year-old woman with hepatic cirrhosis and hepatocellular carcinoma [11]. Abdulmajid et al., retrospectively noted a left atrial myxoma when evaluating computed tomography scans of a 71-year-old man treated for transitional cell carcinoma of the bladder 6 years earlier [12]. Iltumur et al., found a large left atrial myxoma while performing preoperative echocardiography for non-cardiac surgery, in a 64-year-old man with coexisting cutaneous squamous cell carcinoma [13]. Van der Merwe et al. and Gopalakrishnan et al., reported cardiac myxomas in patients with pulmonary adenocarcinoma and renal cell carcinoma, respectively [14,15].

To the best of the authors' knowledge, no guides focusing on treating cardiac myxomas as a second primary tumor were identified in the literature. We propose that a two-way clinical relationship between myxoma and other primary cancers exists. On the one hand, these observations possibly emphasize the importance of echocardiography screening for patients diagnosed with cancer, especially specific types such as breast adenocarcinoma. On the other hand, this also raises the question whether patients diagnosed with myxoma should undergo screening for other primary cancers, and to what extent? Historically patients with myxoma underwent urgent surgery with no time to waste; however, nowadays this is not the case and we can use our time to screen these patients for other primary tumors. Depending on their underlying risk factors (e.g., age, smoking history,...) this could be limited to a thorough medical history and physical exam, or it could go as far as performing other paraclinical evaluations such as PET scan.

<p>2009</p>	<p>Ozer N, et al. [8]</p>	<p>Asymptomatic right atrial myxoma originating from the inferior vena cava and right atrium junction in a patient with breast ductal adenocarcinoma</p>	<p>Invasive Ductal Carcinoma of the breast</p>	<p>Right atrium at the junction of the inferior vena cava and right atrium</p>	 <p>A) Transthoracic apical four-chamber view showing the mass in the right atrium. Transesophageal echocardiography [8].</p> <p>B) Bicaval view showing the localization of the mass at the junction of the right atrium and inferior vena cava [8].</p> <p>C) Aortic view showing the heterogenous mass in the right atrium [8].</p>
<p>2010</p>	<p>Gopalakrishnan M, et al. [15]</p>	<p>Cardiac myxoma mimicking extension of renal cell carcinoma</p>	<p>Renal Cell Carcinoma</p>	<p>Right atrium at the interatrial septum</p>	 <p>Transthoracic echocardiogram (TTE) showing right atrial mass [15].</p>
<p>2011</p>	<p>Lazos-Ochoa M, et al. [11]</p>	<p>Synchronic hepatocellular carcinoma with atrial myxoma. A case report</p>	<p>Hepatocellular Carcinoma (HCC)</p>	<p>Left atrium</p>	
<p>2015</p>	<p>Van der Merwe J, et al. [14]</p>	<p>Single-Stage Minimally Invasive Surgery for Synchronous Primary Pulmonary Adenocarcinoma and Left Atrial Myxoma</p>	<p>Pulmonary Adenocarcinoma</p>	<p>Left atrium at the interatrial septum</p>	 <p>Transthoracic echocardiographic imaging of a synchronous intracardiac mass [14].</p>
<p>2015</p>	<p>Ittumur K, et al. [13]</p>	<p>Simultaneous occurrence of a large asymptomatic prolapsing left atrial myxoma with a cutaneous squamous cell carcinoma (SCC)</p>	<p>Cutaneous SCC (Sacral area)</p>	<p>Left atrial myxoma originating from the posterior wall and prolapsing into the left ventricular cavity</p>	

<p>2016</p>	<p>Hajsadeghi S, et al. [10]</p>	<p>Right ventricular myxoma originating from a papillary muscle: a case report</p>	<p>Rectal Adenocarcinoma</p>	<p>Right ventricle attached to the posteromedial papillary muscle</p>	 <p>A) Transthoracic Echocardiography (TTE) of RV inflow showing large mass (43mm x 37mm) in the RV attached to papillary muscle tissue or the tricuspid valve (TV) with a narrow stalk (white arrow). RA: Right Atrium; RV: Right Ventricle [10].</p>  <p>B) TTE in apical four-chamber view showing a large RV mass (white arrow) attached to papillary muscle tissue in the TV with involvement of anterior TV leaflet. LA: Left Atrium; LV: Left Ventricle; RA: Right Atrium; RV: Right Ventricle [10].</p>
<p>2016</p>	<p>Kataoka S, et al. [7]</p>	<p>Primary Multiple Cardiac Myxomas in a Patient without the Carney Complex</p>	<p>Carcinoma of Breast</p>	<p>4 tumors located in the left atrium and left ventricle</p>	 <p>A) Transesophageal echocardiography: An immobile tumor of size 15 x 15 mm at the interatrial septum (yellow arrow) [7].</p>  <p>B) Transesophageal echocardiography: A mobile tumor of size 24 x 6 mm (from the left atrium to the left ventricle) at the anterior mitral leaflet (yellow arrowhead) [7].</p>  <p>C) Transesophageal echocardiography: An immobile tumor of size 21 x 33 mm at the posterior mitral leaflet (white arrow) [7].</p>  <p>D) Transesophageal echocardiography: A mobile tumor of size 11 x 11 mm (from the left ventricular outflow tract to the aorta) at the left leaflet of the aortic valve (white arrowhead) [7].</p>

2021	Abdulmajid L, et al. [12]	Natural Growth of Left Atrial Myxoma	Bladder TCC (Transitional Cell Carcinoma)	Left atrium attached at the fossa ovalis of the interatrial septum	 <p>Transesophageal echocardiogram showing sessile tumor in the left atrium at the level of interatrial septum. LA: Left Atrium, RA: Right Atrium; SVC: Superior Vena Cava [12].</p>
------	---------------------------	--------------------------------------	---	--	---

Our observations indicate the need for further research to evaluate the significance and possible genetic basis of this finding. Furthermore, it calls for expert opinions on how to approach and treat a patient with a cardiac myxoma and other simultaneous primary tumor. Additionally, this matter draws clinicians' attentions towards cardiac myxomas when encountering nonspecific symptoms, not otherwise defined by other diagnoses, in patients treated for various cancers.

References

- Bossert T, Gummert JF, Battellini R, et al. Surgical experience with 77 primary cardiac tumors. *Interact Cardiovasc Thorac Surg.* 2005; 4: 311-315.
- Vander Salm TJ. Unusual primary tumors of the heart. *Semin Thorac Cardiovasc Surg.* 2000; 12: 89-100.
- Maisch B. Immunology of cardiac tumors. *Thorac Cardiovasc Surg.* 1990; 38: 157.
- Seino Y, Ikeda U, Shimada K. Increased expression of interleukin 6 mRNA in cardiac myxomas. *Br Heart J.* 1993; 69: 565.
- Kamilaris CDC, Faucz FR, Voutetakis A, Stratakis CA. Carney Complex. *Exp Clin Endocrinol Diabetes.* 2019; 127: 156-164.
- Meir K, Maly A, Doviner V, Maly B. Intraoperative cytologic diagnosis of unsuspected cardiac myxoma: a case report. *Acta Cytol.* 2004; 48: 565-568.
- Kataoka S, Otsuka M, Goto M, et al. Primary Multiple Cardiac Myxomas in a Patient without the Carney Complex. *J Cardiovasc Ultrasound.* 2016; 24: 71-74.
- Ozer N, et al. Asymptomatic right atrial myxoma originating from the inferior vena cava and right atrium junction in a patient with breast ductal adenocarcinoma. *Archives of the Turkish Society of Cardiology.* 2009; 37: 479-482.
- Nuño IN, Kang TY 4th, Arroyo H, Starnes VA. Synchronous cardiac myxoma and colorectal cancer: a case report. *Tex Heart Inst J.* 2001; 28: 215-217.
- Hajsadeghi S, Pazoki M, Moradians V, Iranpour A, Jebeli M, Babaheidarian P. Right ventricular myxoma originating from a papillary muscle: a case report. *Echocardiography.* 2016; 33: 1913-1915.
- Lazos-Ochoa M, Cruz-Gordillo AG, Murguía-Perez M. Carcinoma hepatocelular sincrónico con mixoma auricular. Informe de un caso [Synchronous hepatocellular carcinoma with atrial myxoma. A case report]. *Invest Clin.* 2011; 52: 170-174.
- Abdulmajid L, El Addouli H, Paelinck B, De Bock D. Natural Growth of Left Atrial Myxoma. *Ann Thorac Surg.* 2021; 111: e275-e277.
- Ittumur K, Demir T, Ariturk Z, Toprak N, Oto O. Simultaneous occurrence of a large asymptomatic prolapsing left atrial myxoma with a cutaneous squamous cell carcinoma. *Heart Surg Forum.* 2015; 18: E25-E27.
- Van der Merwe J, Beelen R, Martens S, Van Praet F. Single-Stage Minimally Invasive Surgery for Synchronous Primary Pulmonary Adenocarcinoma and Left Atrial Myxoma. *Ann Thorac Surg.* 2015; 100: 2352-2354.
- Gopalakrishnan M, Benjamin M, Kamath M, Thekkepurackal R. Cardiac myxoma mimicking extension of renal cell carcinoma. *Interact Cardiovasc Thorac Surg.* 2010; 10: 816-817.