

Review Article

Atrial Failure: Mechanisms, Diagnosis, and Potential Therapeutic Targets

Zi-Yuan Li[#]; Xi-Chen Liu[#]; Ran Yin; Xiao-Ping Peng;
Jian-Bing Zhu; Jia-Ling Yin; Yuan Shu; Ru Ying*

Department of Cardiology, the First Affiliated Hospital of Nanchang University, No.17, Yongwai Main Street, Donghu District, China

***Corresponding author: Ru Ying**

Department of Cardiology, the First Affiliated Hospital of Nanchang University, No.17, Yongwai Main Street, Donghu District, China.
Email: yingru2005@163.com

[#]These authors have been contributed equally to this article.

Received: November 15, 2023

Accepted: December 12, 2023

Published: December 19, 2023

Introduction

Previously, the importance of cardiomyocytes in heart failure was usually disregarded in favor of the notion that left ventricular dysfunction and neurohumoral factors were the main causes of heart failure [2]. The atria not only play an important role in storage, channeling, and pumping in the ventricular filling, but they also play a unique role in cardiac electrical activity, endocrine and regulation by pacing conduction, secretion of Atrial Natriuretic Peptide (ANP), feedback inhibition of sympathetic nerves [3,4]. Even without left ventricular dysfunction, heart failure can still happen [5,6]. Similar to ventricular failure, which eventually results in heart failure, atrial failure is an influencing factor that is even more important than previously thought [7]. Atrial failure, which generally refers to atrial dysfunction independent of Atrial Fibrillation (AF) and heart failure in the absence of obvious valvular abnormalities or ventricular dysfunction, due to atrial anatomical, mechanical, electrophysiological, and/or hemodynamic abnormalities, and the presence of clinical symptoms associated with cardiac insufficiency is currently not defined in a uniform way. This results in a decrease in quality of life and life expectancy [1]. The mechanical dysfunction of left atrial failure is accompanied by endocrine and/or atrial regulatory failure, which manifests as a lack of ANP synthesis, ANP resistance, the dominance of sympathetic nervous system excitation, excessive release of vasopressin, etc. This causes an excessive activation of neurohumoral fluids, vasoconstriction, and volume overload [8], which precipitates or exacerbates heart failure.

Abstract

The normal atrial function includes ventricular systolic storage function, early ventricular diastolic conduit function, and auxiliary pump function in late ventricular diastolic function, which assists in ventricular filling and maintaining cardiac output. Atrial dysfunction can result in or increase cardiac dysfunction, impacting the patient's quality of life and life expectancy, even in the absence of evident valve or ventricular problems. Atrial failure, which mostly refers to the left atrium, has recently been given new clinical meaning and is being treated as a separate condition [1]. The mechanism, diagnosis, and potential therapeutic targets of atrial failure will be discussed in this article to better comprehend and treat atrial failure in the future.

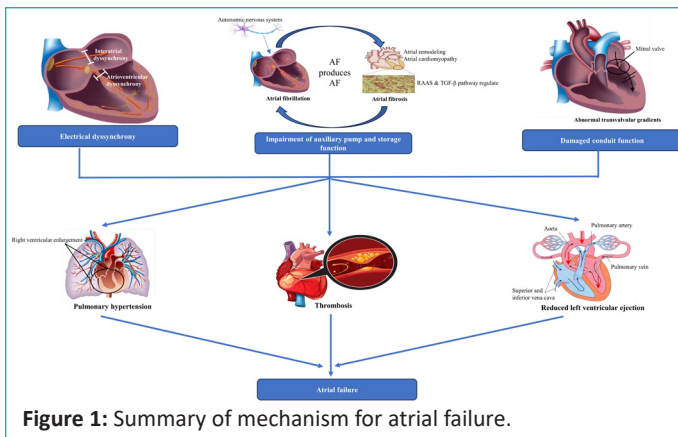
Keywords: Atrial failure; Mechanisms; Diagnosis; Therapeutic targets

Mechanisms of Atrial Failure

Many conditions can impair the atria by affecting the electrical coupling between the atrioventricular and the atrium, the hemodynamics or function of the atrium, thereby promoting thrombosis, causing pulmonary hypertension, and even heart failure. Atrial remodeling can increase a patient's susceptibility to AF, and the persistence of AF aggravates atrial remodeling and induces new atrial fibrillation, eventually forming a vicious circle. In addition, atrial failure may activate neuroendocrine pathways (renin-angiotensin-aldosterone system and sympathetic nervous system), which could result in atrial remodeling, and further impair atrial function.

Electrical Activity is Out of Synchronization

There are two main reasons why electrical activity is dyssynchrony: interatrial and atrioventricular dyssynchrony. When the mitral valve closes, left atrial agitation in the interatrial conduction block is delayed and even starts to contract, leading to an instantaneous increase in left atrial pressure and abnormal enlargement of the left atrium [9]. Pulmonary hypertension results from an increase in left atrial pressure that travels down the pulmonary veins and into the pulmonary capillary system [10]. Atrial enlargement predisposes to atrial rhythm disturbances, especially AF increasing the likelihood of thrombosis [11]. In the atrioventricular block, the atrial contracts ineffectively, and blood stasis in the atria leads to thrombosis, increasing the risk of stroke. Patients with cryptogenic stroke may have a severe atrial failure, according to research by Leong DP et al. [12]. In



addition, Additionally, the AV block results in a considerable reduction in cardiac output and the loss of the AV contraction sequence. Heart failure is more likely to occur if the heart already has underlying lesions.

Impairment of Auxiliary Pump and Storage Function

Whether it is rapid or disordered atrial arrhythmias (such as AF), or extensive atrial fibrosis caused by atrial remodeling and Atrial Cardiomyopathy (ACM), all impair the normal contraction and relaxation of the atrium, resulting in thrombosis, left ventricular hemodynamic damage, and clinical manifestations of cardiogenic stroke, myocardial ischemia, even heart failure. At the same time, atrial failure is accelerated by the simultaneous promotion and effect of AF and atrial fibrosis.

Atrial fibrillation: AF is the most common clinical persistent arrhythmia [13], and AF is associated with an increased risk of thromboembolic events, particularly cardiogenic stroke, as well as heart failure and all-cause mortality [14]. AF irregularly descends to excite the ventricles, impairs filling and contractile functions of the ventricles, as well as reducing ejection. The disorder of atrial rhythm in AF patients leads to ineffective contraction of the atrium, blood in the atrium cannot be effectively pumped into the ventricles, which causes blood stasis and aberrant intimal function, both of which make thrombus formation simple. Predisposing factors for AF include older age, left atrial enlargement, decreased left atrial function, left ventricular systolic dysfunction, and heart failure, as well as coronary artery disease, and pulmonary, or mitral valve disease [15]. Emerging evidence suggests that oxidative stress, calcium overload, inflammation, microRNAs, and myofibroblast activation are all thought to be associated with AF and AF-induced atrial remodeling [16]. Patients with chronic AF showed alterations in heart structure and function according to Fuchs et al. Compared with normal participants, patients with chronic AF have a larger left atrium and reduced left ventricular systolic and diastolic function [17]. In the development of atrial remodeling, AF can further impair the electrical activity and mechanical action of cardiomyocytes, which has a detrimental effect on the overall heart function [18]. In addition, studies have shown that the autonomic nervous system is also involved in the initiation and persistence of AF [19]. Its activation can cause significant and heterogeneous changes in atrial electrophysiology and induce atrial tachyarrhythmia, including atrial tachycardia (AT) and AF [20]. Increased sympathetic activity is the immediate response to the conflicting messages of increased cardiac filling pressure and decreased arterial blood pressure during AF, and long-term effects may impair cardiopulmonary pressure reflex gain, exacerbating AF [21]. In patients with chronic AF, Nguyen et al. demonstrated that the density of atrial sympathetic nerves in-

creases significantly [22]. Activation of parasympathetic components in the heart's intrinsic autonomic nervous system may lead to heterogeneous changes in atrial fibrillation cycle length (AFCL), enhancing pulmonary venous site receptor excitation [23]. Autonomic nervous system activity may also be the result of reflex excitation brought on by AF itself in a large proportion of AF patients, in addition to risk factors such as hypertension, obesity, and sleep-disordered breathing [19]. The occurrence of AF further impairs atrial function, forming a vicious circle of "AF producing AF" [24].

Atrial Remodeling, atrial cardiomyopathy, and atrial fibrosis: Atrial remodeling is an adverse structural, functional, and electrophysiological alteration of atrial myocytes as a result of arrhythmias or stress/volume overload [25]. Cardiomyocyte proliferation, hypertrophy, necrosis, apoptosis, extracellular stroma, energy metabolism, altered ion channel expression, atrial hormone secretion, and atrial fibrosis are histological features of atrial remodeling [9,26]. ACM is defined as a myocardial disorder associated with dysfunction of mechanical and/or electrical activity that usually, but not always, presents with atrial fibrosis, hypertrophy, or enlargement [27]. Markers of atrial stromal lesions were associated with an increased risk of stroke in a cohort of patients without a history of AF or stroke, [28]. ACM impairs the storage function of the atria and poor ventricular filling. The histological features of ACM are as follows: (1) cardiomyocytic lesions; (2) fibrosis; (3) Myocardial lesions combined with fibrosis; (4) Primary non-collagen infiltration (with or without cardiomyocyte changes) [29]. In atrial remodeling and ACM, atrial fibrosis is an important pathological manifestation of both.

Cardiac fibroblasts, which are inherently unexcitable cells but can transfer electrical currents between cardiomyocytes through connexins, are chiefly responsible for atrial fibrosis. Studies have shown that the RAAS and TGF β pathways significantly regulate the development of cardiac fibrosis [30]. Fibrosis leads to heterogeneity of current conduction, shortening action potential, depolarization of resting cardiomyocytes, and inducing stage 4 automatic depolarization of cardiomyocytes [31]. Atrial fibrosis slows local conduction and increases conduction heterogeneity in vitro, according to research from Li et al. and disruption of normal electrical conduction and the establishment of new circuits increase the incidence and duration of AF [32]. Whether atrial myocardial fibrosis is the cause or effect of AF is unclear. Previous studies have only shown that AF is inextricably linked to left atrial structural remodeling, which ultimately manifests as a reduction in atrial myocytes, an increase in interstitial collagen content, and atrial wall fibrosis. Oakes et al. found that the expansion of atrial fibrosis in patients six months after catheter ablation was associated with increased recurrence of arrhythmias [33]. In another study, persistent AF and left atrial fibrosis > 35% were associated with increased AF recurrence [34]. In a word, atrial fibrosis is a key factor in the development of atrial fibrillation based on heart failure [35]. Arrhythmias based on atrial fibrosis can develop changes in the cardiomyocyte matrix as part of atrial remodeling in AF patients. Atrial fibrosis causes atrial hemodynamic overload, which affects the extension of atrial tissue and causes atrial dysfunction.

Damaged Conduit Function

The so-called conduit function is that during the early and middle diastolic periods, the active diastolic of the left ventricle

draws blood from the left atrium that is passively emptied to fill the ventricle [36]. The mitral valve opens at this time. The left atrium is directly exposed to left ventricular pressure, and blood flow in the conduit is significantly affected by the diastolic properties of the left heart and the pressure gradient relative to the pulmonary veins [37]. Abnormalities in transvalvular pressure difference can affect conduit function [1]. As mentioned above, dilation and deformation of the atria predispose to AF. Once AF occurs, normal synchronous atrial contraction is lost [38]. Differences in transvalvular pressure often obstruct the left atrial empty, secondary to pulmonary hypertension. In patients with chronic thromboembolic pulmonary hypertension, storage, and conduit function in the right atrium are significantly impaired [39]. The left atrial conduit volume may even be a new indicator of the classification and grading of ventricular Diastolic Dysfunction (DD) and provide a sensitive but moderately specific parameter to distinguish between not DD or mild and severe DD, according to recent evidence, which suggests that altered atrial conduit function is a predictable and quantifiable response to DD [40]. The study by Raafset al. demonstrated that left atrial conduit strain can be a strong and independent predictor of prognosis for dilated cardiomyopathy [41]. A previous study by Tello et al. compared right atrial conduit strain with invasive pressure-volume loop curves in patients with pulmonary hypertension and found that right atrial conduit strain was associated with right ventricular diastolic capacity [42]. This is similar to what is observed in the left heart, where damage to conduit function mainly affects ventricular filling.

Diagnosis of Atrial Failure

Imaging Evaluation

In clinical practice, atrial size is often used as a surrogate marker of atrial function, with larger atria often considered "dysfunctional" atria [43]. Imaging is a convenient means to determine atrial size and function and to assess atrial fibrosis and hemodynamics.

Echocardiography: Echocardiography is the preferred method for evaluating atrial structure and function. Speckle Tracking Imaging (STI), Real-Time Three-Dimensional Echocardiography (RT3DE), and other new technologies can make up for the shortcomings of traditional ultrasound to a certain extent, which include geometric model assumptions and angle dependence.

Some studies suggest that left atrial dysfunction may precede changes in left atrial volume [44]. Changes in left atrial function may be more sensitive than those in volume, when detecting abnormal myocardial function and intervention effectiveness, so left atrial strain has important diagnostic and prognostic value [45]. Independent of lung blood flow, left atrial appendage, and angle, STI can track the relative movement of myocardial spots frame by frame during each cardiac cycle, accurately measure myocardial strain, and quantitatively evaluate cardiac function and wall movement. Two varieties are now available: two-dimensional and three-dimensional. Based on the original 2D-STI, 3D-STI tracks the movement trajectory of myocardial spot echoes in three-dimensional space, making up for the shortcomings of low spatial resolution of 2D-STI and the difficulty in fully reflecting the three-dimensional information of myocardium in three-dimensional space. Left atrial strain includes longitudinal, radial, and annular strains, but the overall longitudinal strain of the left atrium is the most diagnostic in evaluating left atrial structure and function due to the thinness of the left atrial myocardium [46]. According to the three-time

phases of the left atrium, the overall longitudinal strain of the left atrium is divided into left atrial storage phase strain (LASr), conduit stage strain (LAScd), and Systolic Phase Strain (LASct). Pathan F et al. included 2542 healthy subjects using STIs to propose a normal reference range for three important functional strains in the left atrium: storage strain of 39 percent, conduit strain of 23 percent, and systolic strain of 17 percent [47]. For patients with AF, the left atrial strain has been shown to provide stroke risk stratification independent of the CHA2DS2-VASc score and help guide anticoagulation [48,49]. Sarvari et al. used 2D-STI to take the standard deviation of the 18-segment systolic duration of the left atrial wall (systolic duration refers to the interval between the peak of the P wave on the ECG and the maximum shortening rate of the left atrium), that is, the Left Atrial Mechanical Dispersion (LAMMD) as the evaluation parameter. The evaluation of left atrial systolic synchronicity in 61 patients with normal or mildly enlarged left atrium showed that anterior descending branch (LAD) in patients with recurrent AF was significantly higher than in patients without recurrence, suggesting that LAD in patients with normal cardiac structure can be regarded as a useful indicator for predicting AF recurrence after ablation [50]. Mochizuki et al. evaluated 42 patients with paroxysmal AF and found that AF recurrence following ablation was better predicted by the global strain of the left atrium as measured by 3D-STI than 2D-STI [51]. Both 3D-STI and 2D-STI have the potential to evaluate the structure and function of the left atrium in patients with AF and even predict AF recurrence. It is still unknown whether technique is preferable.

While RT3DE displays the spatial structure, movement law, and adjacent relationship of the heart in real-time and 3D, with a focus on measuring the volume of the heart chamber, STI quantitatively analyzes atrial remodeling by measuring the strain and strain rate of the local atrial muscle. The value of RT3DE in evaluating the structure and function of the left atrium in patients with AF has been demonstrated, and the commonly used indicators evaluated are Left Atrial Volume (LAV), including minimum left atrium (LAV min), maximum (LAV max), and presystolic volume (LAV pre), left atrial volume index (LAVI) [52]. LAVI max > 34 mL/m² is regarded by the European Society of Cardiology (ESC) as a sign of increased LA [53]. The parameters obtained by calculating the volume changes can also reflect the left atrial function, mainly including the left atrial enlargement index (LAEI), which reflects the storage function, and the Left Atrial Active Ejection Fraction (LAAEF) and Total Ejection Fraction (LATEF) reflecting the auxiliary pump function, the Left Atrial Passive Ejection Fraction (LAPEF), which reflects conduit function, and the Left Atrial Function Index (LAFI), which reflects the overall function of the left atrium [54]. Jiang et al. combined 2D-STI with RT3DE to evaluate atrial remodeling and functional changes in patients with AF accompanied by essential hypertension. They found that LAVI, LAEI, and LATEF improved significantly with treatment [54]. Zhang et al. used the RT3DE method to evaluate left atrial end-diastolic volume index (ILAEDV), End-Systolic Volume Index (ILAESV), and Left Atrial Ejection Fraction (LAEF) in 50 pairs of AF patients and healthy individuals, then compared it with Two-Dimensional Echocardiography (2DE). The results showed that ILAED and ILAESV were significantly elevated in AF patients, but overall LAEF was reduced. The conclusions reached by the two methods were consistent. These studies demonstrate that RT3DE is a feasible and accurate method for assessing left atrial volume and function in patients with AF [55]. In addition, RT3DE is valuable in assessing AF recurrence. Hongning et al. included

88 patients with AF who calculated the left atrial volume (max, min, and pre) and functional parameters by RT3DE and evaluated the left atrium of AF patients with the minimum systolic volume time standard deviation (Tmsv-SD) at the end-diastolic stage synchronization. Results showed that whereas Tmsv-SD was significantly different in patients with AF recurrence, left atrial volume and functional parameters were not associated with AF recurrence. Thus, when we used RT3DE to evaluate left atrial, Tmsv SD in patients with normal left ventricular function and normal left atrium was a valid predictor of AF recurrence after radiofrequency ablation [56].

Cardiac Magnetic Resonance (CMR): Myocardial fibrosis is a significant marker of atrial structural remodeling. Advanced gadolinium-enhanced cardiac magnetic resonance (LGE-CMR) is the gold standard for evaluating myocardial fibrosis. Marrouche et al. apply LGE imaging to conduct a multicenter prospective study among patients with persistent and paroxysmal AF. According to the percentage of atrial wall fibrosis as a percentage of the total atrial wall, the degree of left atrial fibrosis is divided into four grades (grade I: <10%, II: ≥10% and <20%, III: ≥20% and <30%, and IV: ≥30%), showing that for every 1% increase in fibrosis, the risk of AF recurrence increases by 6% [57]. Other studies have shown that for every 10 percent increase in LA-LGE, the risk of AF recurrence is 1.5-fold higher [58]. Crochet et al. found that even years after successful resolution of persistent atrial fibrillation, the contractility and compliance of the left atrium were significantly impaired, and left atrial dysfunction was associated with atrial scar detected by LGE-CMR [59]. As for catheter ablation, the degree of atrial pre-fibrosis determines intervention success [60]. For the diagnosis and prognosis of atrial fibrillation, early and correct assessment of atrial fibrosis is crucial. A more complete picture of atrial hemodynamic features is provided by four-dimensional magnetic resonance of the left atrial blood flow, which also helps in the prediction of intra-atrial thrombosis [61].

Electrocardiogram (ECG)

Left atrial abnormalities are associated with ischaemic stroke, and ECG can be noninvasive for assessment, especially as the P-wave index is valuable in predicting stroke. The detection indicators include P-wave duration, the morphology of P waves in lower wall leads (II, III, aVF), the terminal potential of P-wave in V1 lead (PtFV1) reflecting atrial enlargement, and P-wave area [62]. Specifically, the P-wave duration ≥120 ms, the occurrence duration of a non-biphasic P wave or biphasic P wave ≥120 ms in the lower wall leads [63], PtFV1 < -40 ms·mm [64]. The maximum P wave area quantified by ECG (max PWA) can be used as an index of left atrial remodeling, suggesting that left atrial enlargement is associated with a high risk of stroke [65]. In addition, P-Wave Dispersion (PWD) is also an ECG marker of atrial remodeling reflecting the heterogeneity and discontinuity of intra-atrial and interatrial conduction, which has great potential in the field of atrial fibrillation prediction [66].

Natriuretic Peptide family (NPs).

At present, some biomarkers are increasingly emerging diagnostic and prognostic tools, but we focus on NPs. NPs are a group of polypeptide hormones with similar structures but different origins, mainly including Atrial Natriuretic Peptide (ANP), Brain Natriuretic Peptide (BNP), and C-type Natriuretic Peptide (CNP), which can well predict ischemia, bleeding risk, the prognosis of atrial fibrillation and the presence of myocardial fibrosis.

ANP known as cardiac natriuretic, is mainly secreted by atrial muscle cells. Mid-anterior precordial natriuretic peptide (MR-pro ANP) has been identified as a biomarker of cardioembolism and can be used to distinguish the origin of ischemic stroke from other subtypes [67]. Its stable nature can indicate an episode of atrial fibrillation at a high level [68]. Although ANP increases in AF patients, studies have found that ANP level is low in patients with long-term AF [69], so its clinical application is worth further studying.

BNP and NT-pro BNP are mainly secreted by ventricular myocytes when pro BNP divides with a ratio of 1:1. Their values are elevated in patients with atrial fibrillation, perhaps due to loss of ordered atrial contraction and increased atrial pressure leading to ventricular filling disorder. At the same time, elevated ventricular rate leads to myocardial ischemia and uneven distribution of blood oxygen, which stimulates ventricular-producing BNP [70]. Since NT-pro BNP has a longer half-life than BNP, higher levels better reflect the high risk of stroke and cardiovascular death? BNP level >251.2 pg/mL is an independent predictor of left atrial thrombosis [71]. Given the potential ability of NPs to reflect a dysfunctional atrial environment, it has been proposed that if NT-pro BNP is identified as a biomarker of ACM, it will further assist in the stratification of patients at risk of cardiovascular events [72].

Besides, experiments have shown that CNP can inhibit cardiac fibroblast proliferation, collagen synthesis, and myocardial fibrosis. Therefore it is inferred that elevated CNP may be considered as a compensatory mechanism for reversing myocardial fibrosis in atrial fibrillation [73].

Potential Therapeutic Targets and Therapeutic Approaches

Reverse left atrial remodeling can be defined as a reduction in left atrial volume and an improvement in left atrial strain function, which is also the goal of treating atrial failure [74]. In theory, the treatment method only needs to be able to fight any link in the mechanism of occurrence.

Left atrial or biatrial pacing corrects electrical activity out of synchronization. Cardioversion, rhythm control, anticoagulation, radiofrequency ablation, left atrial appendage embolization for atrial fibrillation, thrombosis prevention, and ischemic stroke [75]. RAAS inhibitors (e.g. ACE inhibitors, ARBs, aldosterone receptor antagonists) and inhibition of the TGFβ signaling pathway can effectively reduce cardiac fibrosis [30]. Cell transplantation, alternative biomaterials, and direct reprogramming of fibroblasts to induce Cardiomyocytes (CMs) have shown efficacy in animal models [30]. Bode et al. found that the SGLT-1&2 inhibitor sotagliflozin can improve ACM-related LA remodeling and arrhythmias by constructing a rat model of metabolic syndrome-associated ejection fraction-preserved heart failure (HFpEF), but the safety and efficacy of these results for human therapy require further clinical exploration [76]. The most crucial thing is to prevent or correct risk factors that share common pathogenic conditions with atrial failure, such as hypertension, obesity, sleep apnea, diabetes, etc. [77,78]. Therefore, we should incorporate primary and secondary preventive measures such as blood pressure control, weight loss, and physical exercise into the basic management of atrial failure [77].

Conclusion and Outlook

Atrial failure has become a new clinical concept and is the result of any structural and functional abnormalities of the atrium, including but not limited to primary atrial disease. The

development of atrial failure is significantly influenced by atrial fibrillation and atrial fibrosis. Recent advances in cardiac imaging, electrophysiology, and biomarkers have improved our comprehension the complex anatomy and functional characteristics of the atria. They are important tools for assessing atrial structure and function. Atrial failure can be utilized as an early indicator of heart failure, because atrial remodeling and dysfunction are independently associated with heart failure and predate the onset of clinical heart failure symptoms [79]. We should realize that early identification and treatment of atrial failure have great potential in managing early heart failure. The current therapeutic strategy focuses on primary and secondary prevention, eliminating the cause, managing atrial fibrillation, and inhibiting fibrosis. As for other new therapeutic targets and approaches, we still need to explore them further. However, we believe that by deepening our understanding of atrial failure, we can better define and manage it in the future, and provide heart failure patients with timely-effective diagnosis and treatment.

Author Statements

Competing Interests

The authors declare that they have no competing interests.

Availability of data and Materials

Available under request.

Ethics Approval and Consent to Participate

The study was performed in accordance with the ethical guidelines of the Institutional Animal Care and Use committee of Nan Chang University.

Funding

This research work was financially supported by grants: the National Natural Science Foundation of China (Nos.: 82200363, 81960093), Science and Technology Program of Jiangxi Province (No. 20171BAB215003), Science and Technology Plan of Jiangxi Provincial Health Commission (No. 202130208 and SKJP_220211623).

References

- Bisbal F, Baranchuk A, Braunwald E, Bayés de Luna A, Bayés-Genís A. Atrial failure as a clinical entity: JACC review topic of the week. *J Am Coll Cardiol.* 2020; 75: 222-32.
- Carpenito M, Fanti D, Mega S, Benfari G, Bono MC, Rossi A, et al. The central role of left atrium in heart failure. *Front Cardiovasc Med.* 2021; 8: 704762.
- Kebed KY, Addetia K, Lang RM. Importance of the left atrium: more than a bystander? *Heart Fail Clin.* 2019; 15: 191-204.
- Delgado V, Di Biase L, Leung M, Romero J, Tops LF, Casadei B, et al. Structure and function of the left atrium and left atrial appendage: AF and stroke implications. *J Am Coll Cardiol.* 2017; 70: 3157-72.
- Nagueh SF. Heart failure with preserved ejection fraction: insights into diagnosis and pathophysiology. *Cardiovasc Res.* 2021; 117: 999-1014.
- Pagel PS, Tawil JN, Boettcher BT, Izquierdo DA, Lazicki TJ, Crystal GJ, et al. Heart failure with preserved ejection fraction: A comprehensive review and update of diagnosis, pathophysiology, treatment, and perioperative implications. *J Cardiothorac Vasc Anesth.* 2021; 35: 1839-59.
- Rossi A, Gheorghiadu M, Triposkiadis F, Solomon SD, Pieske B, Butler J. Left atrium in heart failure with preserved ejection fraction: structure, function, and significance. *Circ Heart Fail.* 2014; 7: 1042-9.
- Triposkiadis F, Pieske B, Butler J, Parissis J, Giamouzis G, Skoularigis J, et al. Global left atrial failure in heart failure. *Eur J Heart Fail.* 2016; 18: 1307-20.
- Akiyama T, Eichelberger JP. Interatrial block vs left atrial enlargement. *J Electrocardiol.* 2012; 45: 452-3.
- Reddy YNV, Borlaug BA. Pulmonary hypertension in left heart disease. *Clin Chest Med.* 2021; 42: 39-58.
- Seko Y, Kato T, Haruna T, Izumi T, Miyamoto S, Nakane E, et al. Association between atrial fibrillation, atrial enlargement, and left ventricular geometric remodeling. *Sci Rep.* 2018; 8: 6366.
- Leong DP, Joyce E, Debonnaire P, Katsanos S, Holman ER, Schaliq MJ, et al. Left atrial dysfunction in the pathogenesis of cryptogenic stroke: novel insights from speckle-tracking echocardiography. *J Am Soc Echocardiogr.* 2017; 30: 71-79.e1.
- Margulescu AD, Mont L. Persistent atrial fibrillation vs paroxysmal atrial fibrillation: differences in management. *Expert Rev Cardiovasc Ther.* 2017; 15: 601-18.
- Stewart S, Hart CL, Hole DJ, McMurray JJV. A population-based study of the long-term risks associated with atrial fibrillation: 20-year follow-up of the Renfrew/Paisley study. *Am J Med.* 2002; 113: 359-64.
- Oikonomou E, Zografos T, Papamikroulis GA, Siasos G, Vogiatzi G, Theofilis P, et al. Biomarkers in atrial fibrillation and heart failure. *Curr Med Chem.* 2019; 26: 873-87.
- Jalife J, Kaur K. Atrial remodeling, fibrosis, and atrial fibrillation. *Trends Cardiovasc Med.* 2015; 25: 475-84.
- Fuchs T, Baron EL, Leitman M, Burgsdorf O, Torjman A, Vered Z. Does chronic atrial fibrillation induce cardiac remodeling? *Echocardiography.* 2013; 30: 140-6.
- Ling LH, Kistler PM, Ellims AH, Iles LM, Lee G, Hughes GL, et al. Diffuse ventricular fibrosis in atrial fibrillation: noninvasive evaluation and relationships with aging and systolic dysfunction. *J Am Coll Cardiol.* 2012; 60: 2402-8.
- Linz D, Elliott AD, Hohl M, Malik V, Schotten U, Dobrev D, et al. Role of autonomic nervous system in atrial fibrillation. *Int J Cardiol.* 2019; 287: 181-8.
- Chen J, Wasmund SL, Hamdan MH. Back to the future: the role of the autonomic nervous system in atrial fibrillation. *Back to the Future. Pacing Clin Electrophysiol.* 2006; 29: 413-21.
- Chen PS, Chen LS, Fishbein MC, Lin SF, Nattel S. Role of the autonomic nervous system in atrial fibrillation: pathophysiology and therapy. *Circ Res.* 2014; 114: 1500-15.
- Nguyen BL, Fishbein MC, Chen LS, Chen PS, Masroor S. Histopathological substrate for chronic atrial fibrillation in humans. *Heart Rhythm.* 2009; 6: 454-60.
- Lim PB, Malcolm-Lawes LC, Stuber T, Kojodjojo P, Wright IJ, Francis DP, et al. Stimulation of the intrinsic cardiac autonomic nervous system results in a gradient of fibrillatory cycle length shortening across the atria during atrial fibrillation in humans. *J Cardiovasc Electrophysiol.* 2011; 22: 1224-31.
- Kerr B, Brandon L. Atrial fibrillation, thromboembolic risk, and the potential role of the natriuretic peptides, a focus on BNP and NT-proBNP - A narrative review. *Int J Cardiol Heart Vasc.* 2022; 43: 101132.

25. Goette A, Kalman JM, Aguinaga L, Akar J, Cabrera JA, Chen SA, et al. EHRA/HRS/APHS/SOLAECE expert consensus on atrial cardiomyopathies: definition, characterization, and clinical implication. *Europace*. 2016; 18: 1455-90.
26. Delgado V, Di Biase L, Leung M, Romero J, Tops LF, Casadei B, et al. Structure and function of the left atrium and left atrial appendage: AF and stroke implications. *J Am Coll Cardiol*. 2017; 70: 3157-72.
27. Nattel S, Harada M. Atrial remodeling and atrial fibrillation: recent advances and translational perspectives. *J Am Coll Cardiol*. 2014; 63: 2335-45.
28. Kamel H, Bartz TM, Elkind MSV, Okin PM, Thacker EL, Patton KK, et al. Atrial cardiopathy and the risk of ischemic stroke in the CHS (cardiovascular health study). *Stroke*. 2018; 49: 980-6.
29. Baman JR, Cox JL, McCarthy PM, Kim D, Patel RB, Passman RS, et al. Atrial fibrillation and atrial cardiomyopathies. *J Cardiovasc Electrophysiol*. 2021; 32: 2845-53.
30. Park S, Nguyen NB, Pezhouman A, Ardehali R. Cardiac fibrosis: potential therapeutic targets. *Transl Res*. 2019; 209: 121-37.
31. Andrade J, Khairy P, Dobrev D, Nattel S. The clinical profile and pathophysiology of atrial fibrillation: relationships among clinical features, epidemiology, and mechanisms. *Circ Res*. 2014; 114: 1453-68.
32. Li D, Fareh S, Leung TK, Nattel S. Promotion of atrial fibrillation by heart failure in dogs: atrial remodeling of a different sort. *Circulation*. 1999; 100: 87-95.
33. Oakes RS, Badger TJ, Kholmovski EG, Akoum N, Burgon NS, Fish EN, et al. Detection and quantification of left atrial structural remodeling with delayed-enhancement magnetic resonance imaging in patients with atrial fibrillation. *Circulation*. 2009; 119: 1758-67.
34. Khurram IM, Habibi M, Gucuk Ipek E, Chrispin J, Yang E, Fukumoto K, et al. Left atrial LGE and arrhythmia recurrence following pulmonary vein isolation for paroxysmal and persistent AF. *JACC Cardiovasc Imaging*. 2016; 9: 142-8.
35. Ma J, Chen Q, Ma S. Left atrial fibrosis in atrial fibrillation: mechanisms, clinical evaluation and management. *J Cell Mol Med*. 2021; 25: 2764-75.
36. Marino PN. Left atrial conduit function: A short review. *Physiol Rep*. 2021; 9: e15053.
37. Kono T, Sabbah HN, Rosman H, Alam M, Stein PD, Goldstein S. Left atrial contribution to ventricular filling during the course of evolving heart failure. *Circulation*. 1992; 86: 1317-22.
38. Benussi S, de Maat GE. Atrial remodelling and function: implications for atrial fibrillation surgery. *Eur J Cardiothorac Surg*. 2018; 53: i2-i8:i2-8.
39. Yamasaki Y, Abe K, Kamitani T, Hosokawa K, Kawakubo M, Sagiya K, et al. Balloon pulmonary angioplasty improves right atrial reservoir and conduit functions in chronic thromboembolic pulmonary hypertension. *Eur Heart J Cardiovasc Imaging*. 2020; 21: 855-62.
40. Nappo R, Degiovanni A, Bolzani V, Sartori C, Di Giovine G, Cerini P, et al. Quantitative assessment of atrial conduit function: a new index of diastolic dysfunction. *Clin Res Cardiol*. 2016; 105: 17-28.
41. Raafs AG, Vos JL, Henkens MTHM, Slurink BO, Verdonchot JAJ, Bossers D, et al. Left atrial strain has superior prognostic value to ventricular function and delayed-enhancement in dilated cardiomyopathy. *JACC Cardiovasc Imaging*. 2022; 15: 1015-26.
42. Tello K, Dalmer A, Vanderpool R, Ghofrani HA, Naeije R, Roller F, et al. Right ventricular function correlates of right atrial strain in pulmonary hypertension: a combined cardiac magnetic resonance and conductance catheter study. *Am J Physiol Heart Circ Physiol*. 2020; 318: H156-64.
43. Chen C, Yang Y, Ma W, Qi L, Zhang B, Zhang Y. Left atrial phasic function remodeling during its enlargement: a two-dimensional speckle-tracking echocardiography study. *BMC Cardiovasc Disord*. 2022; 22: 231.
44. Morris DA, Takeuchi M, Krisper M, Köhncke C, Bekfani T, Carstensen T, et al. Normal values and clinical relevance of left atrial myocardial function analysed by speckle-tracking echocardiography: multicentre study. *Eur Heart J Cardiovasc Imaging*. 2015; 16: 364-72.
45. Kupczyńska K, Mandoli GE, Cameli M, Kasprzak JD. Left atrial strain - a current clinical perspective. *Kardiol Pol*. 2021; 79: 955-64.
46. Badano LP, Koliaas TJ, Muraru D, Abraham TP, Aurigemma G, Edvardsen T, et al. Standardization of left atrial, right ventricular, and right atrial deformation imaging using two-dimensional speckle tracking echocardiography: a consensus document of the EACVI/ASE/Industry Task Force to standardize deformation imaging. *Eur Heart J Cardiovasc Imaging*. 2018; 19: 591-600.
47. Pathan F, D'Elia N, Nolan MT, Marwick TH, Negishi K. Normal ranges of left atrial strain by speckle-tracking echocardiography: A systematic review and meta-analysis. *J Am Soc Echocardiogr*. 2017; 30: 59-70.e8.
48. Sonaglioni A, Lombardo M, Nicolosi GL, Rigamonti E, Anzà C. Incremental diagnostic role of left atrial strain analysis in thrombotic risk assessment of nonvalvular atrial fibrillation patients planned for electrical cardioversion. *Int J Cardiovasc Imaging*. 2021; 37: 1539-50.
49. Liao JN, Chao TF, Kuo JY, Sung KT, Tsai JP, Lo CI, et al. Global left atrial longitudinal strain using 3-beat method improves risk prediction of stroke over conventional echocardiography in atrial fibrillation. *Circ Cardiovasc Imaging*. 2020; 13: e010287.
50. Sarvari SI, Haugaa KH, Stokke TM, Ansari HZ, Leren IS, Hegbom F, et al. Strain echocardiographic assessment of left atrial function predicts recurrence of atrial fibrillation. *Eur Heart J Cardiovasc Imaging*. 2016; 17: 660-7.
51. Mochizuki A, Yuda S, Fujito T, Kawamukai M, Muranaka A, Nagahara D, et al. Left atrial strain assessed by three-dimensional speckle tracking echocardiography predicts atrial fibrillation recurrence after catheter ablation in patients with paroxysmal atrial fibrillation. *J Echocardiogr*. 2017; 15: 79-87.
52. Yagmur J, Cansel M, Kurtoglu E, Hidayet S, Acikgoz N, Ermis N, et al. Assessment of left atrial volume and function by real time three-dimensional echocardiography in obese patients. *Echocardiography*. 2017; 34: 210-6.
53. Lang RM, Badano LP, Mor-Avi V, Afilalo J, Armstrong A, Ernande L, et al. Recommendations for cardiac chamber quantification by echocardiography in adults: an update from the American Society of Echocardiography and the European Association of Cardiovascular Imaging. *J Am Soc Echocardiogr*. 2015; 28: 1-39.e14.
54. Jiang F, Chen Y, Wu L, Zhang Y, Liu J, Sun X, et al. Left heart function evaluation of patients with essential hypertension and paroxysmal atrial fibrillation by two-dimensional speckle tracking imaging combined with real-time three-dimensional ultrasound imaging. *J Thorac Dis*. 2021; 13: 322-33.
55. Zhang Q, Wang JF, Dong QQ, Yan Q, Luo XH, Wu XY, et al. Evaluation of left atrial volume and function using single-beat real-time three-dimensional echocardiography in atrial fibrillation patients. *BMC Med Imaging*. 2017; 17: 44.

56. Hongning Y, Ruiqin X, Jing W, Gaojie H, Xuqian Z, Hong Z, et al. Assessment of left atrial function and dyssynchrony by real time three-dimensional echocardiography predicts recurrence of paroxysmal atrial fibrillation after radiofrequency ablation. *Eur Rev Med Pharmacol Sci*. 2018; 22: 3151-9.
57. Habibi M, Lima JA, Khurram IM, Zimmerman SL, Zipunnikov V, Fukumoto K, et al. Association of left atrial function and left atrial enhancement in patients with atrial fibrillation: cardiac magnetic resonance study. *Circ Cardiovasc Imaging*. 2015; 8: e002769.
58. Floria M, Radu S, Gosav EM, Cozma D, Mitu O, Ouatu A, et al. Left atrial structural remodelling in non-valvular atrial fibrillation: what have we learnt from CMR? *Diagnostics (Basel)*. 2020; 10: 137.
59. Cochet H, Scherr D, Zellerhoff S, Sacher F, Derval N, Denis A, et al. Atrial structure and function 5 years after successful ablation for persistent atrial fibrillation: an MRI study. *J Cardiovasc Electrophysiol*. 2014; 25: 671-9.
60. Kallistratos MS, Poulimenos LE, Manolis AJ. Atrial fibrillation and arterial hypertension. *Pharmacol Res*. 2018; 128: 322-6.
61. Markl M, Lee DC, Ng J, Carr M, Carr J, Goldberger JJ. Left atrial 4-dimensional flow magnetic resonance imaging: stasis and velocity mapping in patients with atrial fibrillation. *Invest Radiol*. 2016; 51: 147-54.
62. Lacalzada-Almeida J, Izquierdo-Gómez MM, Laynez-Cerdeña I, García-Niebla J, Bruña V, Bayés de Luna A, et al. Electrocardiogram and left atrial abnormality: design of an observational study to clarify diagnostic criteria. *Ann Noninvasive Electrocardiol*. 2020; 25: e12770.
63. Alexander B, Mildren J, Hazim B, Haseeb S, Bayes-Genis A, Elosua R, et al. New electrocardiographic score for the prediction of atrial fibrillation: the MVP ECG risk score (morphology-voltage-P-wave duration). *Ann Noninvasive Electrocardiol*. 2019; 24: e12669.
64. Batra MK, Khan A, Farooq F, Masood T, Karim M. Assessment of electrocardiographic criteria of left atrial enlargement. *Asian Cardiovasc Thorac Ann*. 2018; 26: 273-6.
65. Weinsaft JW, Kochav JD, Kim J, Gurevich S, Volo SC, Afroz A, et al. P wave area for quantitative electrocardiographic assessment of left atrial remodeling. *PLOS ONE*. 2014; 9: e99178.
66. Pérez-Riera AR, de Abreu LC, Barbosa-Barros R, Grindler J, Fernandes-Cardoso A, Baranchuk A. P-wave dispersion: an update. *Indian Pacing Electrophysiol J*. 2016; 16: 126-33.
67. Shibazaki K, Kimura K, Iguchi Y, Okada Y, Inoue T. Plasma brain natriuretic peptide can be a biological marker to distinguish cardioembolic stroke from other stroke types in acute ischemic stroke. *Intern Med*. 2009; 48: 259-64.
68. Legallois D, Sorbets E, Chenevier-Gobeaux C, Hallouche M, Bou-baya M, Charnaux N, et al. Score using measurements of plasma midregional pro-atrial natriuretic peptide to estimate the duration of atrial fibrillation. *J Appl Lab Med*. 2017; 1: 522-31.
69. Zografos TA, Katritsis DG. Natriuretic peptides as predictors of atrial fibrillation recurrences following electrical cardioversion. *Arrhythm Electrophysiol Rev*. 2013; 2: 109-14.
70. Mahajan R, Lau DH, Sanders P. Biomarkers and atrial fibrillation: is it prime time yet? *Heart*. 2014; 100: 1151-2.
71. Ochiuni Y, Kagawa E, Kato M, Sasaki S, Nakano Y, Itakura K, et al. Usefulness of brain natriuretic peptide for predicting left atrial appendage thrombus in patients with unanticoagulated nonvalvular persistent atrial fibrillation. *J Arrhythm*. 2015; 31: 307-12.
72. Kerr B, Brandon L. Atrial fibrillation, thromboembolic risk, and the potential role of the natriuretic peptides, a focus on BNP and NT-proBNP - A narrative review. *Int J Cardiol Heart Vasc*. 2022; 43: 101132.
73. Sangaralingham SJ, McKie PM, Ichiki T, Scott CG, Heublein DM, Chen HH, et al. Circulating C-type natriuretic peptide and its relationship to cardiovascular disease in the general population. *Hypertension*. 2015; 65: 1187-94.
74. Thomas L, Abhayaratna WP. Left atrial reverse remodeling: mechanisms, evaluation, and clinical significance. *JACC Cardiovasc Imaging*. 2017; 10: 65-77.
75. Gutierrez C, Blanchard DG. Diagnosis and treatment of atrial fibrillation. *Am Fam Phys*. 2016; 94: 442-52.
76. Bode D, Semmler L, Wakula P, Hegemann N, Primessnig U, Beindorff N, et al. Dual SGLT-1 and SGLT-2 inhibition improves left atrial dysfunction in HFpEF. *Cardiovasc Diabetol*. 2021; 20: 7.
77. Chung MK, Eckhardt LL, Chen LY, Ahmed HM, Gopinathannair R, Joglar JA, et al. Lifestyle and risk factor modification for reduction of atrial fibrillation: A scientific statement from the American Heart Association. *Circulation*. 2020; 141: e750-72.
78. McGann C, Akoum N, Patel A, Kholmovski E, Revelo P, Damal K, et al. Atrial fibrillation ablation outcome is predicted by left atrial remodeling on MRI. *Circ Arrhythm Electrophysiol*. 2014; 7: 23-30.
79. Eicher JC, Laurent G, Mathé A, Barthez O, Bertaux G, Philip JL, et al. Atrial dyssynchrony syndrome: an overlooked phenomenon and a potential cause of 'diastolic' heart failure. *Eur J Heart Fail*. 2012; 14: 248-58.