

## Case Report

# Acute Pericardial Tamponade Associated with Myopericarditis due COVID-19 in a Pediatric Patient

**Balakumar N<sup>1\*</sup>, Lee J<sup>2</sup>, Appachi E<sup>1</sup> and Bautista V<sup>2</sup>**<sup>1</sup>Division of Critical Care Medicine, Children's Hospital of San Antonio, Baylor College of Medicine, TX, USA<sup>2</sup>Division of Cardiology and Cardiothoracic surgery, Children's Hospital of San Antonio, Baylor College of Medicine, TX, USA**\*Corresponding author:** Niveditha Balakumar, Division of Critical Care Medicine, Children's Hospital of San Antonio, Baylor College of Medicine, TX, USA**Received:** October 14, 2021; **Accepted:** November 05, 2021; **Published:** November 12, 2021**Abstract**

We report of a 4-year-old asthmatic female presenting with severe respiratory failure and multi-system inflammatory condition in the setting of acute COVID-19 infection. Despite mechanical ventilation and vasoactive support, she showed hemodynamic instability. Cardiomegaly was evident on chest X-ray and significantly depressed left ventricular function with a large pericardial effusion and signs of tamponade were seen on echocardiography. The effusion was successfully drained percutaneously and her clinical condition improved progressively. Our patient got extubated and discharged home, 4 and 8 days after initial presentation, respectively, with an echocardiogram depicting normal left ventricular function and no recurrent pericardial effusion. Acute cardiac tamponade after COVID-19 infection is rare in pediatric patients but can be life threatening. In our patient, high suspicion of myopericarditis and pericardial effusion led to early intervention and fast recovery on a critically ill patient.

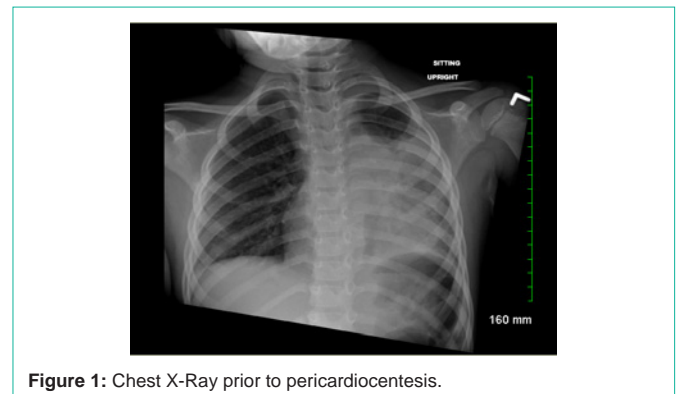**Keywords:** COVID-19; MIS-C; Tamponade; SARS-CoV-2**Case Presentation**

We present a 4-year-old female with a history of mild, intermittent asthma who presented with COVID-19 related Multisystem Inflammatory Syndrome in Children (MIS-C) with perimyocarditis and pericardial tamponade.

Patient was well until about 10 days before presentation when she started having tactile fevers and runny nose. Parents treated her at home with antipyretics. She was doing relatively well until she began having progressively worsening shortness of breath, accompanied by daily fevers, vomiting and diarrhea roughly six days prior to presentation. She was seen at her pediatrician's office at which time she was found to be COVID-positive, which is 5 days prior to presentation at our facility. She was sent home with supportive care including bronchodilator therapy with albuterol from Pediatrician's office.

The patient was brought to our facility where she was found to be critically ill with significant work of breathing with oxygen saturation of 98, sinus tachycardia at 190 bpm and hypotension. She had facial swelling, but no mucocutaneous changes, conjunctivitis or cutaneous rash.

She was intubated and placed on a mechanical ventilator, received fluid resuscitation and inotropic support. In addition to lung findings, a chest X ray was concerning for enlargement of the cardiac silhouette (Figure 1) and therefore an echocardiogram was requested which showed a large pericardial effusion (Figure 2) with clinical tamponade and (Figure 3) moderately to severe decreased left ventricular systolic function with a large circumferential effusion, largest pocket measuring ~22mm. There was partial right atrial collapse. Pericardiocentesis was performed emergently and 160ml approximately of yellow serous fluid were drained (Figure 4). Hemodynamic condition and LV function by echocardiography

**Figure 1:** Chest X-Ray prior to pericardiocentesis.

improved immediately after evacuation of the effusion and recovered progressively so we were able to extubate and discharge her on the 4<sup>th</sup> and 8<sup>th</sup> post admission days. She received IVIG and methyl prednisone during the course of her stay.

Patient had a positive nasopharyngeal SARS-CoV-2 PCR. Patient also tested positive for SARS-CoV-2 IgM and IgG antibodies. BNP and troponin at the time of admission were 2800pg/ml and 1.70ng/ml, respectively. Rest of the infectious workup was negative.

**Discussion**

Ever since coronavirus disease 2019 (COVID-19) pandemic began, there have been reports of severe complications in healthy children who were observed to be hospitalized with cardiogenic shock secondary to myocarditis or Kawasaki disease-like illness associated with COVID-19 infection [1-3]. Definition for Multi System Inflammatory Condition (MIS-C) was established by CDC. The criteria included any patient aged <21 years presenting with fever, laboratory evidence of inflammation, and evidence of clinically severe illness requiring hospitalization, with multisystem

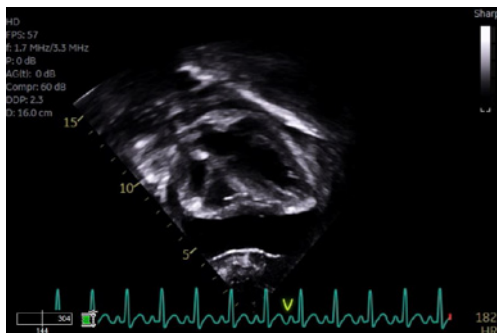


Figure 2: Pericardial Effusion.

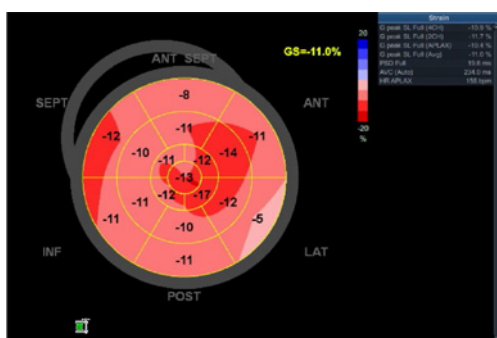

Figure 3: Left ventricular systolic function.

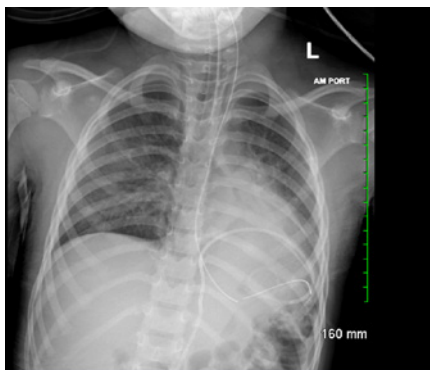


Figure 4: Post Pericardiocentesis.

organ involvement (cardiac, renal, respiratory, hematologic, gastrointestinal, dermatologic or neurological) with no other alternative diagnoses and tests positive for current or recent SARS-CoV-2 infection by RT-PCR, serology, or antigen test; or COVID-19 exposure within the 4 weeks prior to the onset of symptoms [4]. Our patient had predominantly cardiac involvement with secondary respiratory failure requiring mechanical ventilation.

Cardiac involvement is common in children with multisystem inflammatory syndrome associated with the Covid-19. The majority of children have significantly raised levels of N-terminal pro B-type natriuretic peptide, ferritin, D-dimers, and cardiac troponin in addition to high C-reactive protein and procalcitonin levels. In our patient both BNP and troponin were elevated. In comparison with adults with COVID-19, mortality in children with

multisystem inflammatory syndrome associated with COVID-19 is uncommon despite multisystem involvement, very elevated inflammatory markers, and the need for intensive care support [5]. Specific complications from this viral infection include ventricular dysfunction, rhythm disturbances and coronary artery aneurysms [6-9]. Treatments recommendations have included immunomodulators including Intravenous Immunoglobulin (IVIG), steroids and biologics, which our patient received [10].

Pericardial effusion is a rare complication COVID-19 infection in children. There have been several case reports in adults and once case report in pediatrics of patients presenting with acute pericarditis and pericardial tamponade [11]. Our patient is the youngest patient to be reported affected by COVID-19 to have developed pericardial effusion requiring pericardiocentesis. In our critically ill patient with COVID-19 early MIS-C early diagnosis and treatment of cardiac tamponade lead to uneventful recovery. In children with COVID-19 and MIS-C having high level of suspicion of cardiac complications, especially pericardial effusion may improve outcomes and save lives.

## References

1. NYC Health. 2020 Health alert 13: pediatric multi-system inflammatory syndrome potentially associated with COVID-19. 2020.
2. Riphagen S, Gomez X, Gonzalez-Martinez C, Wilkinson N, Theocharis P. Hyperinflammatory shock in children during COVID-19 pandemic. *Lancet*. 2020; 395: 1607-1608.
3. Verdoni L, Mazza A, Gervasoni A, et al. An outbreak of severe Kawasaki-like disease at the Italian epicentre of the SARS-CoV-2 epidemic: an observational cohort study. *Lancet*. 2020; 395: 1771-1778.
4. Centers for Disease Control and Prevention. Emergency preparedness and response: HAN00432. 2020.
5. Valverde I, Singh Y, Sanchez-de-Toledo J, Theocharis P, Chikermane A, Di Filippo S, et al; AEPC COVID-19 Rapid Response Team\*. Acute Cardiovascular Manifestations in 286 Children With Multisystem Inflammatory Syndrome Associated With COVID-19 Infection in Europe. *Circulation*. 2021; 143: 21-32.
6. Feldstein LR, Rose EB, Horwitz SM, et al. Overcoming COVID-19 Investigators; CDC COVID-19 Response Team. Multisystem inflammatory syndrome in US children and adolescents. *N Engl J Med*. 2020; 383: 334-346.
7. Dufort EM, Koumans EH, Chow EJ, et al; New York State and Centers for Disease Control and Prevention Multisystem Inflammatory Syndrome in Children Investigation Team. Multisystem inflammatory syndrome in children in New York State. *N Engl J Med*. 2020; 383: 347-358.
8. Sperotto F, Friedman KG, Son MBF, VanderPluym CJ, Newburger JW, Dionne A. Cardiac manifestations in SARS-CoV-2-associated multisystem inflammatory syndrome in children: a comprehensive review and proposed clinical approach. *Eur J Pediatr*. 2021; 180: 307-322.
9. Swann OV, Holden KA, Turtle L, et al; ISARIC4C Investigators. Clinical characteristics of children and young people admitted to hospital with covid-19 in United Kingdom: prospective multicentre observational cohort study. *BMJ*. 2020; 370: m3249.
10. Henderson LA, Canna SW, Friedman KG, et al. American College of Rheumatology clinical guidance for pediatric patients with multisystem inflammatory syndrome in children (MIS-C) associated with SARS-CoV-2 and hyperinflammation in COVID-19: version 2. *Arthritis Rheumatol*. 2020.
11. Raymond TT, Das A, Manzuri S, Ehrett S, Guleserian K, Brenes J. Pediatric COVID-19 and Pericarditis Presenting With Acute Pericardial Tamponade. *World J Pediatr Congenit Heart Surg*. 2020; 11: 802-804.