

Case Report

Anesthesia Management of Two Operations for Nonfunctional Bladder Paraganglioma

Wang LL¹; Liang ZL^{2*}¹Medical College of Yanbian University, China²Department of Anesthesiology, Yanbian University, China***Corresponding author: Liang ZL**

Department of Anesthesiology, Yanbian University, 1327 Juzi St, China.

Tel: 15526770727

Email: zliang@ybu.edu.cn

Received: November 21, 2023**Accepted:** December 16, 2023**Published:** December 22, 2023**Abstract**

Nonfunctional paragangliomas are perioperatively hemodynamically unstable and prone to lethal complications, making anesthesia a high surgical risk. We report the perioperative management of an unanticipated paraganglioma of the bladder over two surgical procedures. The patient developed a hypertensive crisis during the first intraoperative electrodesiccation of the tumor, and the surgeon stopped the operation and sent intraoperative cryopreservation, which was considered a paraganglioma of the bladder. Postoperative histopathological and immunohistochemical results confirmed the case as a paraganglioma of the bladder. Because of the high risk of continuing the surgery, a second surgery was performed after perfecting the preoperative preparation. The patient's vital signs were stable during the second surgery and the patient's prognosis was good after the surgery. An unanticipated intraoperative paraganglioma is a major perioperative challenge for anesthesiologists, and the improvement of its outcome is mainly due to good preoperative preparation, intraoperative hemodynamic monitoring, and the application of rapid, potent, and short-acting vasoactive drugs.

Keywords: Paraganglioma; Anesthesia**Introduction**

Bladder Paraganglioma (BPG) is a rare bladder tumor that accounts for approximately 0.06% of bladder tumors. Depending on the level of catecholamines and the patient's presentation, BPG can be classified as functional or nonfunctional [1]. Nonfunctional BPG is a major perioperative challenge for anesthesiologists only when the tumor suddenly releases large amounts of catecholamines triggering hypertension and tachycardia during examination or anesthesia procedures [2]. To our knowledge, there are many case reports in the previous literature describing the anesthetic management of paragangliomas, but there are very limited reports on the anesthetic management of nonfunctional paragangliomas. Here, we present a case of an unanticipated patient with nonfunctional BPG who developed a hypertensive crisis during the first surgery. After rapid judgment and secondary preoperative preparation, the patient eventually completed the second surgery with a good prognosis.

Case Presentation (Report)

The patient was a 54-year-old male, weighing 62 kg, with a BMI of 18.21 kg/m². He was admitted to the hospital for 2 days because of a bladder mass found on physical examination. He had a history of hypertension for 5 years, with a maximum blood pressure of 140/100 mmHg. He took oral antihypertensive drugs regularly and complained of fair blood pressure control. On admission: BP 134/84 mmHg; abdomen flat and soft, both kidneys

symmetrical, not palpable, no pressure pain and percussion pain, no pressure pain along the ureteral travel area; no obvious elevation in the bladder area. Laboratory tests: occult blood +2, urine red blood cells 92.50/ul, red blood cells (high magnification field) 16.65/HPF; normal liver and kidney function and coagulation function tests. Chest CT showed: bilateral septal parapneumonic. Cardiac ultrasound and electrocardiogram findings were normal. Urological ultrasound showed that the bladder was occupied, and the posterior wall of the bladder was about 26*20mm weak strong echogenicity near the right ureter. Abdominal CT showed fair bladder filling, and wall thickening, and a soft tissue density shadow was seen in the right lower wall of the bladder, protruding into the lumen, with a long diameter of about 2.4 cm, with significant and sustained enhancement (Figure 1). The cystoscopy showed a mass with a size of about 5*5 cm in the right parietal wall of the bladder near the internal urethral orifice. its surface mucosa was smooth, and the mucosa of the right wall, right posterior wall, and right parietal wall of the bladder were congested and edematous. the rest of the bladder wall showed no abnormality, and the bilateral ureteral openings were normal. The clinical diagnosis was: a bladder tumor. Due to the large size of the tumor, surgical treatment was required. Trans-urethral bladder tumor plasmapheresis was proposed to be performed under general anesthesia at an elective stage.

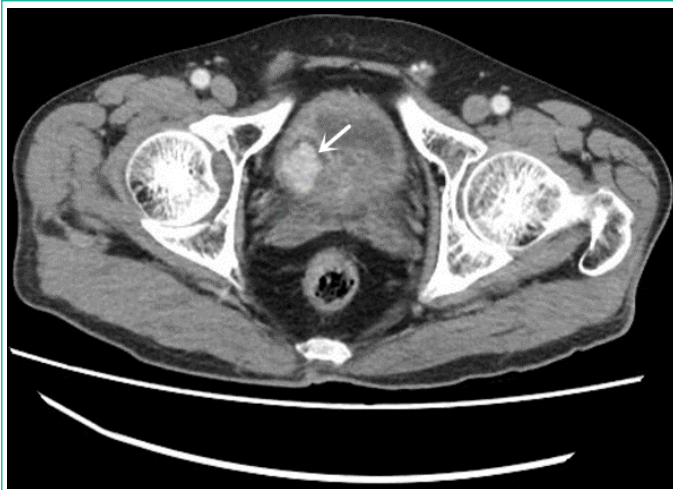

Figure 1: Intensified CT image of the abdomen (White arrow, the bladder occupancy shows significant enhancement after enhancement).

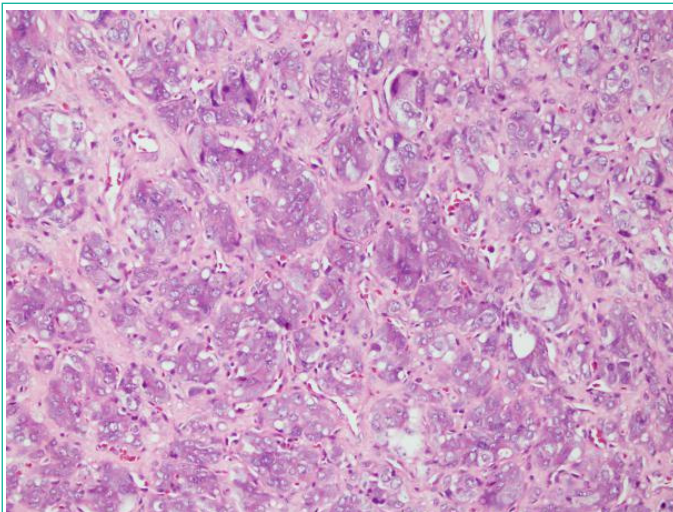


Figure 2: Pathological staining map (HE X200) Microscopically, the tumor cells are distributed in a nested pattern, and more thin-walled blood vessel formation is seen in the interstitium, and the cytoplasm of the tumor cells is rich and transparent or finely granular.

Procedure

The patient was admitted to the operating room and NIBP, ECG, and SpO₂ were monitored. The patient was not given any preoperative medication, and BP 124/82 mmHg, HR 78 beats/min, and SpO₂ 98% were measured on admission monitoring. After preoxygenation for 3min, midazolam 2 mg, 2% lidocaine 5ml, sufentanil 15µg, propofol 80mg, rocuronium bromide 50mg, and hydrogen prednisone 10mg were given intravenously for induction. After about 3min, the 4.0# laryngeal mask was inserted smoothly. Vital signs were stable after induction and intraoperative maintenance anesthesia was maintained by static inhalation compound: propofol 4-6mg·kg⁻¹·h⁻¹, remifentanil 0.05-0.1µg·kg⁻¹·min⁻¹, 1%~1.5% sevoflurane.

The patient was placed in the lithotomy position, and the blood pressure was maintained at about 120/80 mmHg from sterilization to preoperative. The electrocardiogram showed supraventricular arrhythmia when the bladder tumor was halfway through the electrode section, at which time the blood pressure suddenly rose to 204/136 mmHg and the heart rate was 128 beats/min. The surgeon was notified to stop the operation, and about 1 minute later the ECG resumed sinus rhythm with a blood pressure of 108/69 mmHg and a heart rate of 79 beats per minute. The surgeon stopped the wound completely and

then sent the flushed-out tissue fragments for rapid intraoperative frozen section pathology, which returned: (bladder mass) morphology was considered paraganglioma, pending further clarification of the routine. Because of the high risk of continuing surgery, the second stage of surgical treatment was awaited after good preoperative preparation such as volume expansion. The laryngeal mask was removed after the indications for extubation were met, and the patient was sent to the ward for observation for 30 minutes. The pathological specimens and immunohistochemistry: S-100(+), Syn(+), CgA(+), CK(-), Ki-67 (index <2%+) confirmed that it was a paraganglioma of the bladder (Figure 2). No further blood and urine catecholamine measurements were performed on the ward, indicating that it was not yet clear which hormone caused the sudden rise in blood pressure during the first surgery. The patient was then given colloid augmentation, and adrenergic alpha-blocker (phentolamine) in the ward for phase II preoperative preparation and a partial cystectomy was proposed 10 days later. Because the type of hormone secreted by the tumor was unknown, vasoactive drugs such as phenylephrine, norepinephrine, dopamine, nitroglycerin, esmolol, and uradil were prepared before the second-stage surgical anesthesia. The patient was given routine monitoring after admission. To observe the changes in the patient's blood pressure promptly, radial artery puncture placement was performed after local anesthesia, and the preoperative invasive arterial blood pressure fluctuated between 120/70 mmHg and 150/90 mmHg. The induction drug and dose were the same as before. Unlike the first induction, tracheal intubation was performed after the second induction at a sufficient depth of anesthesia and after the full onset of inotropy, and the process of anesthesia maintenance was the same as before. From the induction of anesthesia until the patient was discharged from the operating room with the tracheal tube removed, the hemodynamics was very smooth throughout the second-stage procedure, and the patient was in good postoperative condition and was discharged 10 days later in good condition.

Discussion

This patient is a non-functional Bladder Paraganglioma (BPG), and although there is a previous history of hypertension, the patient's low and asymptomatic blood pressure level, combined with the extremely low incidence of these tumors, makes it difficult to routinely suspect BPG. Assessment of urinary vanilloid mandelic acid in a 24-hour urine sample is helpful in the preoperative diagnosis of functional BPG, however, in the absence of characteristic symptoms of excess catecholamines in the absence of characteristic symptoms of excessive catecholamines, urologists do not favor routinely performing such tests before surgery [3]. The preoperative anesthesia visit did not pay attention to the correlation between the endocrine origin of the urological tumor and the history of hypertension, and there was a lack of preoperative assessment, which was associated with surgical suspension. According to previous studies, significant intraoperative blood pressure fluctuations occur in nonfunctional BPG [4], and the key to intraoperative anesthetic management is the timely detection of abnormal monitoring and effective regulation of blood pressure and heart rate. In this case, the patient's emergence was consistent with the reported literature. Although the patient was not adequately prepared preoperatively, timely intraoperative detection prevented the surgeon from continuing to improperly touch the tumor, releasing large amounts of hormones into the bloodstream.

Perioperative management of BPG patients benefits from

two main aspects: preoperative evaluation and intervention, and intraoperative monitoring and treatment [4]. Although anesthesiologists are not usually involved in preoperative diagnosis, preoperative anesthetic evaluation relies on specific biochemical (urinary catecholamines and metabolite vanilloid) and laboratory tests (CT, ¹³¹I-MIBG) in this patient population [5]. A sound preoperative evaluation facilitates the surgeon and anesthesiologist to medically intervene in the patient's blood pressure and heart rate and replenish chronic hypovolemia to prevent intraoperative adverse events. It has been reported in the literature that, despite the lack of preoperative diagnosis of paraganglioma and inadequate preparation that forced the interruption of the procedure, reoperation after adequate preparation was uncomplicated and intraoperative hemodynamics, were smooth [6]. In our patient, the second-stage procedure went smoothly after dilation and symptomatic treatment with vasoactive drugs before the second-stage surgery. Although the surgery ended successfully, unfortunately, an abnormal electrocardiogram was not collected due to emergency treatment when a hypertensive crisis occurred. At the same time, it is regrettable that the blood and urine catecholamines (epinephrine, norepinephrine, dopamine) were not reviewed before the second-stage procedure to determine which endocrine factor caused the sudden rise in blood pressure in the first procedure and to prepare for the second procedure. The importance of preoperative evaluation and intervention in patients with BPG is exemplified by previous studies as well as this case experience. Intraoperative monitoring is performed by placing an arterial catheter whenever possible, always paying attention to hemodynamic changes, immediately informing the surgeon to stop the operation if hypertensive crisis and malignant arrhythmias occur, and according to the ABP, the use of vasoactive drugs (α -blockers - phentolamine or uradil, β -blockers - esmolol, etc.) should be rationalized according to the changes in ABP.

Conclusion

Patients with BPG are undoubtedly a challenge for anesthesiologists, and our experience should remind all surgeons and anesthesiologists to pay attention to the differential diagnosis of BPG, enhance preoperative screening, and improve intraoperative anesthetic management to provide better anesthesia for these patients. Although being a rare disease limits the abil-

ity of large randomized controlled trials to determine the best treatment strategy, high-quality guidelines for the perioperative management of patients with this disease have been developed based on previous observational studies [7,8], and further improvements and developments in the perioperative management of BPG are expected.

Author Statements

Acknowledgments

Published with the written consent of the patients. No external funding or competing interests were declared.

References

1. Araujo-Castro M, Pascual-Corrales E, Nattero Chavez L, Martínez Lorca A, Alonso-Gordoa T, Molina-Cerrillo J, et al. Protocol for presurgical and anesthetic management of pheochromocytomas and sympathetic paragangliomas: a multidisciplinary approach. *J Endocrinol Invest*. 2021; 44: 2545-55.
2. Calissendorff J, Juhlin CC, Bancos I, Falhammar H. Pheochromocytomas and abdominal paragangliomas: A practical guidance. *Cancers*. 2022; 14: 917.
3. Challis BG, Casey RT, Simpson HL, Gurnell M. Is there an optimal preoperative management strategy for phaeochromocytoma/paraganglioma? *Clin Endocrinol (Oxf)*. 2017; 86: 163-7.
4. Godoroja-Diarto D, Moldovan C, Tomulescu V. Actualities in the anaesthetic management of pheochromocytoma/ paraganglioma. *Acta Endocrinol (Buchar)*. 2021; 17: 557-64.
5. Liu L, Qin YC, Wang GL, Zhang SD, Hou XF, Ma LL. [Strategy of reoperation for pheochromocytoma and paraganglioma]. *Beijing Da Xue Xue Bao Yi Xue Ban*. 2021; 53: 793-7.
6. Tu X, Zhang N, Zhuang X, Chen S, Luo X. Incidental diagnosis of nonfunctional bladder paraganglioma: a case report and literature review. *BMC Urol*. 2021; 21: 98.
7. Zhai H, Ma X, Nie W, Li H, Peng C, Li X, et al. Paraganglioma of the urinary bladder: A series of 22 cases in a Single Center. *Clin Genitourin Cancer*. 2017; 15: e765-71.
8. Zhang B, Fu Z, Liu L, Qiao B, Liu C. Non-functional paraganglioma of urinary bladder managed by transurethral resection. *Int Braz J Urol*. 2019; 45: 910-5.