

## Mini Review

# Mini Review Study of Acetaminophen Overdose Poisoning and Associated Factors in Cases from Poison

Al-Farga Ammar<sup>1\*</sup>, Mohammed Alkhuzae<sup>1</sup>,  
Naji Alsulami<sup>1</sup>, Anas Bushah<sup>1</sup>, Ali Almalki<sup>1</sup>,  
Abdulahkim Torkistani<sup>1</sup> and Mohamed Afifi<sup>1</sup>

<sup>1</sup>Department of Biochemistry, University of Jeddah, Saudi Arabia

<sup>2</sup>Department of Biology, University of Jeddah, Saudi Arabia

\*Corresponding author: Al-Farga Ammar,  
Department of Biochemistry, University of Jeddah, Saudi Arabia

Received: February 04, 2019; Accepted: May 02, 2019;

Published: May 09, 2019

## Abstract

Acetaminophen (APAP) poisoning is among the most common causes of medication-related poisoning and death. Acetaminophen poisoning may occur following a single acute ingestion or through the repeated ingestion of supratherapeutic amounts. The management of the acetaminophen-poisoned patient may include stabilization, decontamination, and administration of N-acetylcysteine, a specific antidote. The duration of N-acetylcysteine treatment is determined by the type of ingestion and the presence or absence of elevated serum Alanine Aminotransferase (ALT) concentrations. Acetaminophen toxicity is one of the most common causes of both intentional and unintentional poisoning in the whole world. Acetaminophen is often recommended by doctors and highly utilized by patients in both prescription and OTC products for a variety of conditions. The FDA has long been updating its recommendations regarding acetaminophen use to help improve patient safety. Acetaminophen is often recommended by doctors and highly utilized by patients in both prescription and OTC products for a variety of conditions, making it undoubtedly one of the most common drugs encountered by pharmacists. This article reviews the etiology, signs, and symptoms of acetaminophen toxicity and associated factors in cases from Poison.

Keywords: Mini review; Acetaminophen; Poisoning

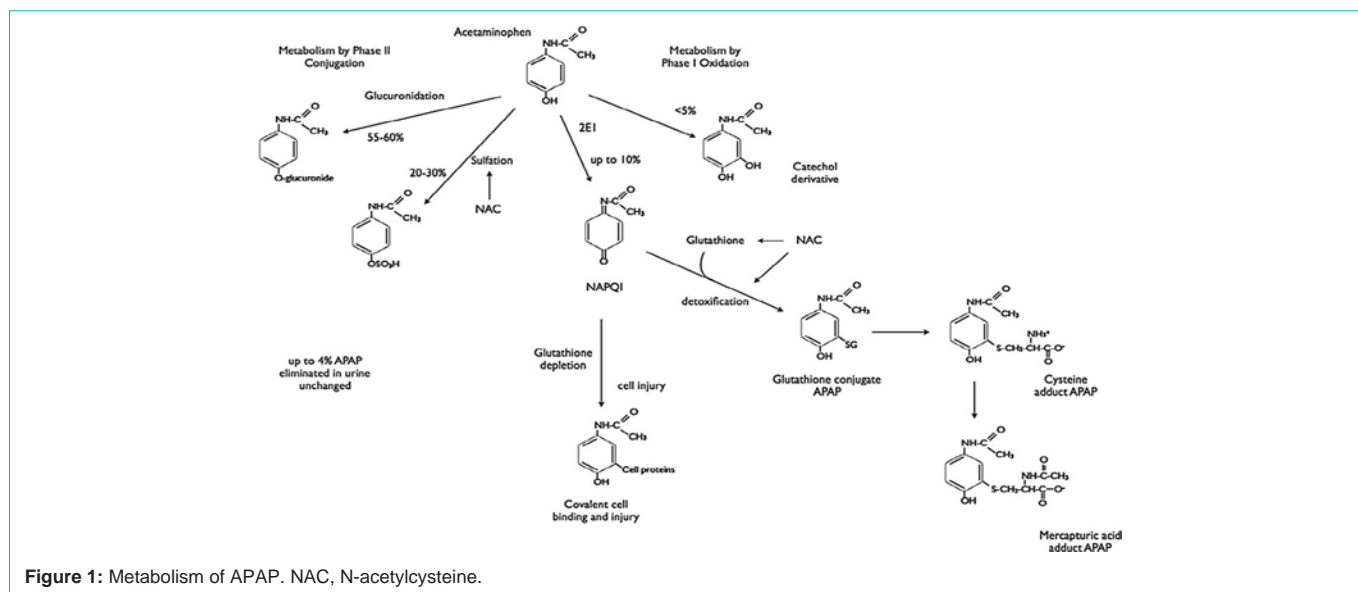
## Introduction

Paracetamol, a first-line therapy for mild-to-moderate pain due to its efficacy, tolerability, and affordability [1]. Acetaminophen (Paracetamol) is utilized worldwide for its pain relieving and antipyretic properties. It is broadly accessible and present in numerous medical and non-remedy prescription. Paracetamol (acetaminophen) is a mellow pain relieving and antipyretic specialist, which is ordinarily utilized around the world [2]. In remedial dosages (for grown-ups 500 mg to 1000 mg, three or four times each day), paracetamol has a couple of unfavorable occasions. Paracetamol is ordinarily taken in overdose either unintentionally or purposefully, [3] and in numerous nations, it is the most widely recognized single compound taken in overdose. In general, a single dose of more than 10g or 150 mg/kg to 200 mg/kg of paracetamol conveys a risk of liver damage [3], yet little portions may also cause liver harm, [4] especially in individuals with constant liquor misuse or anorexia. Paracetamol lethality is the main source of intense liver disappointment in some high-salary nations [5-7]. One huge forthcoming observational companion investigation of 31 liver infection and transplant focuses in the US, enlisting 2070 members with intense liver disappointment somewhere in the range of 1998 and 2013, found that paracetamol harming was the reason in half of the members [8]. It was not until the 1970s that several antidotes that recharge glutathione and detoxify N-Acetyl-P-Benzoquinone Imine (NAPQI) were produced; these included methionine, cysteine, cysteamine, and dimercaprol. Oral methionine and intravenous acetylcysteine have been utilized as counteractants in the UK from this time onwards [9]. In one observational investigation from Edinburgh, intravenous acetylcysteine first-line was professed to be similarly as powerful as cysteamine and methionine and free of

unfavorable impacts. From that point onward, acetylcysteine has been acknowledged as a counteractant for paracetamol overdose either intravenously or orally. A great part of the proof for its utilization and efficacy comes from observational thinks about. Acetylcysteine has now turn into the backbone and standard treatment for paracetamol harming and can either be directed as a 20-to 21-hour intravenous acetylcysteine routine or an oral acetylcysteine routine [10,11,12]. Acetaminophen (N-acetyl-para-Aminophenol, Paracetamol, APAP) toxicity is common especially due to the fact the remedy is so quite simply reachable and there is an appreciation that it is very safe. More than 60 million consume acetaminophen on a weekly basis [13]. Acetaminophen is used in many products in aggregate with other preparations, especially with opioids and diphenhydramine. Many people are not conscious that it is contained in these mixture medicinal drugs [14]. Acetaminophen (APAP) is one of the most often used oral analgesics and antipyretics. It has an excellent security profile when administered in suited therapeutic doses [15]. Acetaminophen poisoning is among the most frequent reasons of medication-related poisoning and death. Acetaminophen poisoning might also manifest following a single acute ingestion or thru the repeated ingestion of supratherapeutic amounts. The acetaminophen products are extensively used as OTC drug so the opportunity of toxicity by means of overdosing of this drug is high.

## Acetaminophen Toxicity Symptoms and Treatment

Acetaminophen toxicity or overdose can occur purposefully (when a person knowingly takes more than the recommended maximum daily dose) or accidentally (when a person is unaware



they are taking multiple products containing acetaminophen and exceeds the recommended maximum daily dose). The maximum recommended acetaminophen dosage is 4 grams/day in an adult and 90 mg/kg/day in children [14]. People with underlying liver disease or those with chronic alcohol consumption are at an increased risk of developing hepatotoxicity (liver damage from chemicals) with use of acetaminophen

## Acetaminophen Toxicity Diagnosis

A doctor's first step in diagnosing acetaminophen toxicity is to get a complete history, including the time the medication was ingested, the amount of medication that was ingested, and what form of the medication was ingested. A diagnosis of acetaminophen toxicity is usually confirmed through diagnostic tests, including an acetaminophen level, electrolytes, kidney function tests, amylase, lipase, liver function tests, complete blood count, and coagulation factors. Imaging studies, such as an ultrasound may be used to assess liver enlargement. A liver biopsy may also be ordered [16].

## Acetaminophen Toxicity Treatment

Timing is a vital factor in the treatment of acetaminophen toxicity, and therefore doctors attempt to begin treatment of acetaminophen overdose within eight hours of ingestion in order to achieve the best possible outcome for the patient. The majority of patients survive acetaminophen toxicity with supportive care such as intravenous fluids and anti-nausea medication, activated charcoal, if used within one hour after ingestion, and antidotal therapy, including N-acetylcysteine [13]. For patients who fail the above therapies and develop liver failure, liver transplantation may be the only treatment option. Doctors will determine if transplantation is necessary if the above tests are significantly abnormal and the patient has developed hepatic encephalopathy, a disorder of the brain caused by a dysfunctional liver.

## Clinical Presentation of Paracetamol Toxicity

The clinical signs, as a rule, don't wind up clear for the initial 24-48

hours after an intense overdose of paracetamol. Liver disappointment may happen between 2-7 days following the ingestion. The clinical course of paracetamol harmfulness is commonly separated into 4 stages. Stage 1 (0-24 hrs) The patient is generally asymptomatic or may give highlights like anorexia, sickness, regurgitating and disquietude. The Liver Function Tests demonstrates a mellow increment in the serum transaminase level (starts to rise around 12 hours after intense ingestion). Stage 2 (18-72 hrs) the patient for the most part encounter sickness, retching, stomach torment (right upper quadrant). On examination, delicacy is available on the correct upper quadrant; tachycardia and hypotension are generally present. Serum transaminase level keeps on rising. Stage 3 (72-96 hrs) Hepatic stage This is the most basic stage. The patient is seriously sick. Jaundice, coagulopathy with draining inclinations, hypoglycemia, hepatic fold, and hepatic encephalopathy happen because of hepatic rot and brokenness. Metabolic acidosis with intense renal disappointment (due to hepatorenal disorder) may create. Demise typically happens as an outcome of multi-organ disappointment. Stage (4 days-3 weeks) Recovery stage Patients who endure the basic ailment of stage 3, are bound to enhance with goals of the indications and organ disappointment.

## Investigation

The examinations incorporate the coordinated serum paracetamol fixation, liver capacity tests (counting prothrombin time or universal standardized proportion) and kidney work tests. These tests are expected to survey hazard and screen advance. The plasma centralization of paracetamol has prescient esteem, on the off chance that it lies over a semi-logarithmic chart, which is acquired by joining the focuses between 1.32 mmol/L at 4 hours after ingestion to 0.33 mmol/L at 12 hours, at that point forecast is poor and genuine hepatic harm is probably going to happen.

## Pharmacology and Toxicity

Acetaminophen is rapidly absorbed from the gastrointestinal (GI) tract with peak concentrations achieved within 90 minutes of a therapeutic dose. The presence of food in the stomach may delay the

peak but not the extent of absorption [17]. Distribution is rapid with a Volume of Distribution (Vd) of about 0.9 L/kg and minimal protein binding at therapeutic concentrations [18]. The half-life of APAP is 2.0 to 2.5 hours. With hepatic injury, the half-life is prolonged to more than 4 hours [18]. Acetaminophen undergoes extensive hepatic metabolism. Approximately 85% of a therapeutic dose undergoes phase II conjugation to sulfated and glucuronidated metabolites that are renally eliminated. Of these two pathways, glucuronidation is predominant in adults, whereas sulfation predominates in children up to about 12 years of age [19]. Up to 10% of APAP undergoes phase I oxidation to a reactive intermediate, N-Acetyl-Para-Benzoquinone Imine (NAPQI), which is normally conjugated with glutathione to nontoxic cysteine and mercapturate metabolites [20]. Cytochrome 2E1 is the Primary Cytochrome p450 (CYP) enzyme responsible for this oxidation. At supratherapeutic doses of APAP (>4 g), sulfation becomes saturated with proportional increases in both glucuronidations and, more significantly, oxidation to NAPQI [20]. Smaller proportions of APAP are eliminated unchanged in the urine and by ring oxidation to a catechol derivative (Figure 1) [20].

## Acknowledgement

The authors would like to acknowledge the Priority Academic Program Development of Jiangsu, Higher Education Institutions, Wuxi city, Jiangsu province, People's Republic of China. We are also grateful to all the staff and students of the Research Centre of Functional Ingredients and Healthy Foods laboratory, and who helped us to bring the raw materials to China.

## References

- Hopkins RE, Dobbin M, Pilgrim JL. Unintentional mortality associated with paracetamol and codeine preparations, with and without doxylamine, in Australia. *Forensic Science International*. 2018; 282: 122-126.
- O'Grady JG. Paracetamol-induced acute liver failure. *Journal of Hepatology*. 1997; 26: 41-6.
- Buckley N, Eddleston M. Paracetamol (acetaminophen) poisoning. *BMJ Clinical Evidence*. 2007; 2007: 2101.
- Kwan D, Bartle WR, Walker SE. Abnormal serum transaminases following therapeutic doses of acetaminophen in the absence of known risk factors. *Digestive Diseases and Sciences*. 1995; 40: 1951-1955.
- Lee WM. Acetaminophen and the U.S. Acute Liver Failure Study Group: lowering the risks of hepatic failure. *Hepatology*. 2004; 40: 6-9.
- Morgan O, Griffiths C, Majeed A. Impact of paracetamol pack size restrictions on poisoning from paracetamol in England and Wales: an observational study. *Journal of Public Health*. 2005; 27: 19-24.
- Bernal W, Hyrylainen A, Gera A, Audimoolam VK, McPhail MJW, Auzinger G, et al. Lessons from look-back in acute liver failure? A single centre experience of 3300 patients. *Journal of Hepatology*. 2013; 59: 74-80.
- Reuben A, Tillman H, Fontana RJ, Davern T, McGuire B, Stravitz RT, et al. Outcomes in adults with acute liver failure between 1998 and 2013: an observational cohort study. *Annals of Internal Medicine*. 2016; 164: 724-32.
- McElhatton PR, Sullivan FM, Volans GN. Paracetamol overdose in pregnancy analysis of the outcomes of 300 cases referred to the Teratology Information Service. *Reproductive Toxicology*. 1997; 11: 85-94.
- Smilkstein MJ, Bronstein AC, Linden C, Augenstein WL, Kulig KW, Rumack BH. Acetaminophen overdose: a 48hour intravenous N-acetylcysteine treatment protocol. *Annals of Emergency Medicine*. 1991; 20: 1058-1063.
- Woo OF, Mueller PD, Olson KR, Anderson IB, Kim SY. Shorter duration of oral N-acetylcysteine therapy for acute acetaminophen overdose. *Annals of Emergency Medicine*. 2000; 35: 363-8.
- Williamson K, Wahl MS, Mycyk MB. Direct comparison of 20-hour IV, 36-hour oral, and 72-hour oral acetylcysteine for treatment of acute acetaminophen poisoning. *American Journal of Therapeutics*. 2013; 20: 37-40.
- Athersuch TJ, Antoine DJ, Boobis AR, Coen M, Daly AK, Possamai L, et al. Paracetamol metabolism, hepatotoxicity, biomarkers and therapeutic interventions: a perspective. *Toxicol Res (Camb)*. 2018; 7: 347-357.
- Jasani B, Weisz DE, McNamara PJ. Evidence-based use of acetaminophen for hemodynamically significant ductus arteriosus in preterm infants. *Semin Perinatol*. 2018; 42: 243-252.
- Graham GG, Davies MJ, Day RO, Mohamudally A, Scott KF. The modern pharmacology of paracetamol: therapeutic actions, mechanism of action, metabolism, toxicity and recent pharmacological findings. *Inflammopharmacology*. 2013; 21: 201-232.
- Bunchorntavakul C, Reddy KR. Acetaminophen-related Hepatotoxicity. *Clin Liver Dis*. 2013; 17: 587-607.
- Anon, editor. Tylenol professional product information. McNeil Consumer Healthcare, Division of McNEIL-PPC Inc Fort Washington PA 19034, USA. 2010.
- Forrest JA, Clements JA, Prescott LF. Clinical pharmacokinetics of paracetamol. *Clin Pharmacokinet*. 1982; 7: 93-107.
- Prescott LF. Kinetics and metabolism of paracetamol and phenacetin. *Br J Clin Pharmacol*. 1980; 10: 291S-298S.
- Gelotte CK, Auiler JF, Lynch JM, Temple AR, Slattery JT. Disposition of acetaminophen at 4, 6, and 8 g/day for 3 days in healthy young adults. *Clin Pharmacol Ther*. 2007; 81: 840-8.