

## Case Report

# A Case of Fusarium Keratitis Developing after Contact with Animal Faeces

Ardic B<sup>1\*</sup>, Uslu H<sup>1</sup>, Aytekin M<sup>2</sup>, Ates O<sup>2</sup> and Celebi O<sup>1</sup>

<sup>1</sup>Department of Microbiology, Atatürk University Faculty of Medicine, Turkey

<sup>2</sup>Department of Ophthalmology, Atatürk University Faculty of Medicine, Turkey

\*Corresponding author: Ardic B, Department of Medical Microbiology, Kackar State Hospital, Hamidiye Mucavir Kackar Street No: 27, Pazar/Rize/Turkey

Received: May 18, 2021; Accepted: June 28, 2021;

Published: July 05, 2021

## Abstract

Fungal agents come second after bacteria in the etiology of keratitis. Fusarium species also have an important place among keratitis agents. Among the factors that predispose to fungal keratitis, traumas constitute the most important place. Traumas occurring especially with organic materials are among the most common causes in the development of fungal keratitis. Fusarium species are difficult to treat due to the high antifungal resistance rate. In our study, a case of Fusarium-induced keratitis, which started after contact with animal feces and progressed to endophthalmitis during the follow-up, was presented in a woman who does not have a known disease and is engaged in agriculture. The patient was treated with topical and systemic voriconazole therapy and co-administration of keratoplasty operation.

## Introduction

Keratitis is a severe infection of the cornea that leads vision loss. This infection mainly caused by bacteria beside fungi, parasites and viruses. The second most common reason is fungi [1]. Fungal keratitis also named as keratomycosis. More than hundred fungi species are isolated from the mycotic keratitis; Most frequent ones are Aspergillus and Fusarium which are filamentous fungi and Candida which is a yeast fungus [2,3].

Trauma, using contact lenses, topical antibiotic and steroids, variety of corneal diseases, previous eye surgeries, immunodeficiencies and various systemic diseases such as diabetes are the leading factors of the fungal keratitis. Trauma is the most important reason among them. In several researches, traumas caused by herbal and organic materials are detected as the most common reasons of the keratomycosis [3,4]. Gray-white colored cotton like infiltrates and satellite lesions can be seen. Sometimes, hypopyon and inflammatory membranes can develop in the anterior chamber [5,6].

Fusarium species are the filamentous fungi which are found in soil and on plants, and can be widely encountered all over the world. The most common infectious agents are *F. Solani* and *F. Oxysporum*. They can cause systemic and superficial infections in humans. The most frequent forms of superficial Fusarium infections are keratitis and onychomycosis. Their resistance to many antifungal agents, is the most outstanding feature of the Fusarium species in the sense of infections [6,7]. The incidence of fusarium keratitis varies according to climatic conditions. Generally it can be commonly seen in tropical and subtropical locations and it is seen less often in temperate zones such as our country [3,8].

## Case Presentation

A 29 years old female presented at the emergency medicine department due to discomfort, pain in her left eye and fatigue, a day after the contamination of her left eye with the feces of an animal. Four times a day dexamethasone ophthalmic drops and twice a day hydrocortisone pomade were prescribed. Even though she applied

the medications for 2 days, due to increase in her complaints, she presented at Ophthalmology Department. The previous treatment was cancelled and three times a day 800 mg acyclovir, five times a day synthetic tears and five times a day ofloxacin ophthalmic solution were prescribed instead. Due to absence of any improvement, the patient presented at the outpatient clinics of ophthalmology department in our hospital, in September 23, 2019. It was found out that she lived in a village and she was engaged in farming after the medical history of the patient was questioned. She hadn't any chronic illnesses and she wasn't on medication. According to her ophthalmic examination, conjunctival hyperemia, ciliary ejection, corneal edema, blur on cornea and 3x4 mm focus of keratitis on the inferior nasal of the cornea were detected (Figure 1).

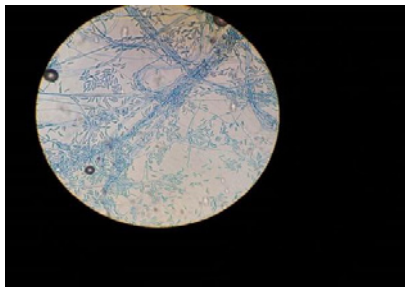
The patient hospitalized based on the initial diagnosis; keratitis. The obtained corneal material from smear was analysed *via* direct microscopic examination and fungal hyphae were seen. Following this, the patient's new therapy determined as hourly voriconazole ophthalmic solution, eight times a day moxifloxacin ophthalmic solution, five times a day synthetic tears, twice a day cyclopentolate (Figure 2). The patient was consulted to Infectious Diseases Department after the growth of Fusarium spp. in culture. Due to minimal improvement to the existing therapy, voriconazole optimised to twice a day 6 mg/kg intravenous therapy as a loading dose and twice a day 4 mg/kg intravenous therapy as a maintenance dose.

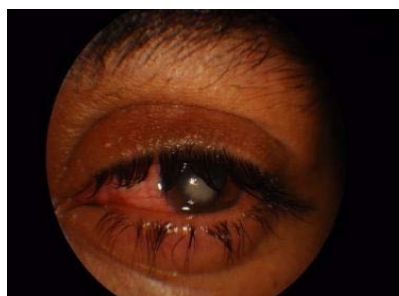
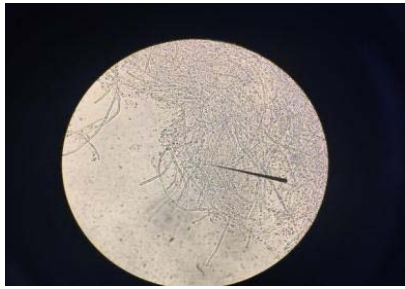
Figure 1: The patient's eye in the acute phase.



**Figure 2:** Microscopic view of corneal scraping material.



**Figure 3:** Banana-shaped fusarium macroconidia stained with lactophenol cotton blue.

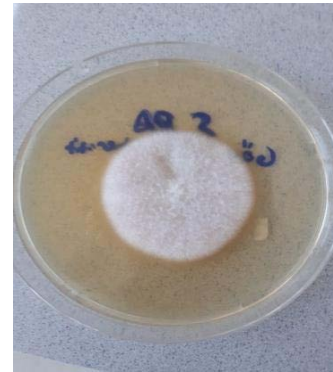Thirteen days after the patient was hospitalized, the complaints of the patient were increased and the patient was dispatched due to fungal endophthalmitis prediagnosis. Afterwards, the patient underwent a keratoplasty operation and her medical treatment completed.

### Microbiological Examination

The corneal scrapings that are sent to the microbiology laboratory was examined as microscopic in 100x and 400x view after they prepared with physiological saline solution. The wide fungal hyphae were observed. Then the specimen was inoculated in Sabouraud dextrose agar plates, Potato dextrose agar plates, Microbiotic agar plates and they were left for incubation at 30°C. After incubation for four days, the velvety colony growth is observed which yellow-orange colored on the base and white colored on the top. For a further investigation, the colonies are dyed with lactophenol cotton blue stain and crescent shaped, banana shaped macroconidias with septas are detected; thus the *Fusarium* spp. diagnosed (Figure 3,4).

### Discussion and Conclusion

Microbial keratitis which is a corneal pathology, is one of the most frequent causes of vision loss, especially in developing countries. The etiology of keratitis varies by the climatic conditions and development levels of the countries. In tropical regions, the fungal agents are prevalent since the bacterial agents are the predominant microbial reason in the temperate zone. In Lalitha's and his colleagues' study, they researched the keratitis cases that are encountered in a large Ophthalmology Department in the south region of India for 11 years and in 8.206 out of 14.738 collected specimens, fungal growth was observed (34,4%) while in 5.912 specimens showed bacterial growth (24,7%). *Fusarium* species are the most frequent species that are isolated from the fungal agents (14,5%) [9].



**Figure 4:** *Fusarium* colony on mycobiotic agar.

In Yılmaz's and his colleague's research that has been carried out in our country where is in temperate zone, they studied 620 keratitis cases for 16 years and culture of the 225 specimens were positive. In 175 of them bacterial growth (77,7%) observed while in 50 cultures showed fungal growth (22,3%). *Fusarium* species were observed as the most frequent fungal agents [10]. In Ong's and his colleague's study, United Kingdom, they obtained 79 culture positive in corneal scrapings among fungal keratitis and 33 of them detected as *Fusarium* spp. (41,8%), the predominant species [11].

The history of trauma is one of the most important predisposing factors concerning fungal keratitis. In Yılmaz's and her colleagues' study, 72% of 630 patients' histories were including at least 1 predisposing factor and traumas with the 36% ratio were the most frequent ones. 63% of them were caused by organic traumas [10]. In Ong's and his colleagues' study, they detected that the most frequent predisposing factor of the fungal keratitis was using contact lenses and they stated that the traumas were at the fourth place on the list [11]. Since the agricultural activity and inhabiting on the countryside in Turkey are common considering United Kingdom, the difference between those studies can be explained by these reasons. In our case, the patient stated that she was living in the countryside and she was contaminated by the animal feces.

The corneal scrapings and direct microscopy is very important for early diagnosis of keratitis. Manikandan and his friends studied 500 corneal scrapings with KOH with the help of direct microscopy and they stated that 96,1% of their observations were correlated with the results of the cultures [12]. And also, Altunok's and his friends' research stated that the fungal keratitis cases can be detected 91% by direct microscopy with the existance of KOH [4]. In our case, the fungal structure was detected by virtue of the direct microscopy and until the results of cultures have been arrived, the therapy was put in order.

Even though microbial keratitis varies according to regional and climatic changes, it is a disease that is commonly seen. But its progression to the endophthalmitis is a rare condition. Henry and his friends stated that only 49 patient's keratitis out of 9.934 progressed to endophthalmitis according to their infectious keratitis study that continued 15 years. Result of the study, 0,5% of the keratitis cases progressed to endophthalmitis. The most frequent isolate of the keratitis induced endophthalmitis was fungal agents, 26 cases [13].

In an other research, Dursun and his friends studied the fusarium keratitis that leads endophthalmitis through 13 years. 10 out of 159 fusarium keratitis cases progressed to endophthalmitis which the ratio is 6,29% [14]. In our case, after 13 days the patient was hospitalized, endophthalmitis was clinically diagnosed.

Even though the topical and systemic antifungal agents are used along with surgical techniques, depending on the severity of the infection's treatment may be challenging [15]. Due to the resistance of Fusarium species to the most of the antifungal agents, success of the treatment can be affected [7]. Voriconazole, an azole, can be used as topical and systematic antifungal in Fusarium infections. There are some studies show that voriconazole can treat the fusarium keratitis successfully. These studies emphasise the importance of surgical techniques with voriconazole for the infection [15-19]. Our case also a patient whose infection was treated by topical and systematic voriconazole treatment beside the kertosplasty.

Fungal keratitis is an important cause of blindness and death, even though there are developing medical techniques and newly invented antifungal agents. Early diagnosis is the key to treat the infection properly. The collaboration of the physicians and the microbiology laboratories accelerates the process of the diagnosis and the treatment. We presented a case, whose initial diagnosis was fungal keratitis, diagnosed early by virtue of the direct microscopy which is progressed into endophthalmitis during the treatment, and be treated with topical-systemic vorinocazole and keratoplasty successfully.

## References

- Mandell G, et al. Mandell, Douglas, and Bennett's principles and practice of infectious diseases. 7<sup>th</sup> edition. Philadelphia: Elsevier. 2010.
- Kumari R, Jain SB, Ranjan N. Microbiological and Epidemiological Profile of Keratomycosis in a Tertiary Care Hospital-a Prospective Analysis. Indian Journal of Applied Research. 2019; 9.
- Doczi I, Gyetval T, Kredics L, et al. Involvement of Fusarium spp. in fungal keratitis. Clin Microbiol Infect. 2004; 10: 773-776.
- Altınok AA, Özdal PÇ, Fırat E. Fungal keratitler (Epidemiyoloji, etiyoloji, tanı ve tedavi). Türkiye Klinikleri Journal of Ophthalmology. 2006; 15: 87-96.
- Thomas PA, Kaliyamurthy J. Mycotic keratitis: epidemiology, diagnosis and management. Clinical Microbiology and Infection. 2013; 19: 210-220.
- Do Carmo A, et al. Fusarium dimerum species complex (Fusarium penzigii) keratitis after corneal trauma. Mycopathologia. 2016; 181.11-12: 879-884.
- Çuhadar T, et al. Keratit Olgularından Elde Edilen Fusarium İzolatlarının Virülans Faktörlerinin ve Antifungal Duyarlılıklarının Belirlenmesi. Mikrobiyol Bul. 2018; 52: 247-258.
- Çorabatır C, et al. Korneal abse kültüründen Fusarium oxysporum izole edilen bir olgu. Mersin Üniversitesi Sağlık Bilimleri Dergisi. 2013; 6.1: 26-29.
- Lalitha P, et al. Trends in bacterial and fungal keratitis in South India, 2002–2012. British Journal of Ophthalmology. 2015; 99.2: 192-194.
- Yılmaz S, et al. Mikrobiyal keratit tedavisinde 16 yıl. Türkiye Klinikleri Journal of Ophthalmology. 2000; 17.1: 1-6.
- Ong HS, et al. Altered patterns of fungal keratitis at a London ophthalmic referral hospital: an eight-year retrospective observational study. American journal of ophthalmology. 2016; 168: 227-236.
- Manikandan P, et al. Fungal Keratitis: Epidemiology, Rapid Detection, and Antifungal Susceptibilities of Fusarium and Aspergillus Isolates from Corneal Scrapings. BioMed research international. 2019; 2019.
- Henry CR, et al. Infectious keratitis progressing to endophthalmitis: a 15-year study of microbiology, associated factors, and clinical outcomes. Ophthalmology. 2012; 119.12: 2443-2449.
- Dursun D, et al. Advanced Fusarium keratitis progressing to endophthalmitis. Cornea. 2003; 22.4: 300-303.
- Thomasa PA, Geraldineb P. Enfeksiyöz keratit. Current Opinion in Infectious Diseases. 2007; 2.2: 89.
- Consigny S, et al. Successful voriconazole treatment of disseminated fusarium infection in an immunocompromised patient. Clinical infectious diseases. 2003; 37.2: 311-313.
- Reis A, et al. Successful treatment of ocular invasive mould infection (fusariosis) with the new antifungal agent voriconazole. British Journal of Ophthalmology. 2000; 84.8: 928-928.
- Klont RR, et al. Successful treatment of Fusarium keratitis with cornea transplantation and topical and systemic voriconazole. Clinical Infectious Diseases. 2005; 40.12: 110-112.
- Berkem R, et al. Fusarium solani'nin etken olduğu fungal keratit olgusu. FLORA. 2016; 21.1: 33-37.