

## Case Report

# A Case Report of *Coenurus Cerebralis* in a Goat at Dembecha District of Amhara Region, Ethiopia

**Abdi Ahmed Umer\***; Shubisa Abera; Tsion Bilata

Animal Health Institute (AHI), Microbiology Research Laboratory, P.O. Box 04, Sebeta, Ethiopia

**\*Corresponding author: Abdi Ahmed Umer**

Animal Health Institute (AHI), Microbiology Research Laboratory, P.O. Box 04, Sebeta, Ethiopia.

Email: abdivet2014@gmail.com

**Received:** July 25, 2023**Accepted:** September 06, 2023**Published:** September 13, 2023**Abstract**

The Animal Health Institute received a report of an outbreak from Amhara Regional State, West Gojam zone, Dembecha district, with an unknown etiological agent on caprine death in February 2023. With the objective to conduct investigations and ascertain the reason for the caprine death, a team of experts was deputed to the affected area. Goat exhibiting seizures, lateral recumbency, and appetite loss during a clinical examination, symptoms of a central nervous system disorder including paddling, convulsions, and unconsciousness were noted. Based on clinical sign and presence of definitive hosts at the area the case has been defined for coenurosis cerebralis. For further confirmatory diagnosis postmortem inspection for the brain was undertaken. Cysts were found during necropsy in the left hemisphere's occipital lobe. The cysts were filled with a clear fluid, and the inner layer of the cysts had several clusters of scolices growing out of it. Larval form of *Taenia multiceps*, known as *Coenurus cerebralis*, is found in the small intestines of dogs and other carnivores in the wild. Worldwide, coenurosis is endemic, and it is particularly prevalent in Ethiopia's highlands, where there are many sheep.

Commonly occurs in the life cycle of dogs and small ruminants. The larvae of this parasite are found in the brain and spinal cord of intermediate hosts, while the adult stage of the parasite lives in the small intestine of dogs, foxes, coyotes, and jackals. The intermediate hosts become infected when the dog eats the brain containing the *Coenurus* cyst, which then develops into *Taenia multiceps* and begins to pass proglottids containing eggs on pasture. If a person accidentally consumes a parasite egg, they become infected with coenurosis.

The primary method of controlling coenurosis is the regular administration of canine anthelmintics and the proper disposal of sheep and goat brain.

**Keywords:** Coenurosis cerebralis; Post mortem; Goats; Dembecha, Gojam

**Introduction**

Coenurosis cerebral is important disease that affects sheep and goats and results in significant economic loss in their production [1]. Dogs and other wild carnivores serve as the larval hosts for *Coenurus cerebralis*, a species of *Taenia multiceps* that lives in the small intestine. Gid, also known as sturdy, is a disease that primarily affects the Central Nervous Systems (CNS) of sheep and goats and, to a lesser extent, cattle, buffalo, camels, pigs, deer, horses, yaks, and wild sheep, as well as humans [2]. In addition to being a serious health concern for sheep and goats everywhere, this disease could have important economic repercussions. The location, size, and extent of the cysts as well as the degree of brain compression all affect the symptoms [3].

When the cyst in *Coenurus cerebralis* grows, it causes CNS disorders that may be fatal. *Coenurus cerebralis* causes purulent meningoencephalitis [4]. Animals that have been infected display ataxia, blindness, circling, convulsions, teeth grinding, head tilting, lack of coordination, uncontrolled movements, salivation, paresis, and cerebral atrophy. Typically, 2–8 months after ingesting the pathogen, the majority of the clinical symptoms are seen [5]. Aside from the peritoneal and pelvic cavities, liver, intramuscular, tongue, parotid, lung, perineal fat, tunica adventitia of the aorta, and lungs, extracranial locations in goats have also been reported to harbor *Coenurus* cysts [6].

Radiology, ultrasonography, and computed tomography are imaging techniques that are rarely used to diagnose coenurosis instead of a clinical examination. Necropsy results are typically used to confirm the diagnosis [7].


### Objective

The main goal of the investigation was to determine what caused an outbreak of caprine deaths and to gather samples and other data in the outbreak area.

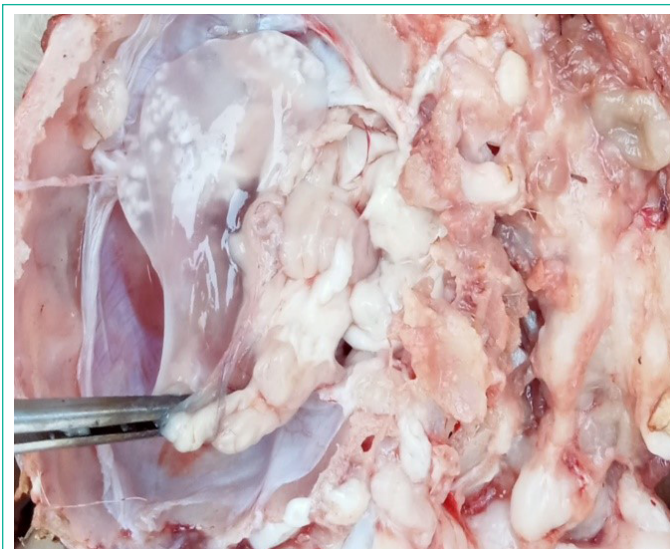
### Case Description

The owner of Zangar Agricultural Development was the first to report the disease's incidence, and AHI received the information by using the correct channels of communication. The team, which included different experts from Animal Health Institute (AHI) laboratories, traveled to Amhara Regional State, West Gojam, Dembecha district, and Makar lega bedessa kebele to look into the origin of the outbreaks. Interviews with animal attendants and the farm manager for the Zangar Agricultural Development were done to find out the size and timing of the outbreak.

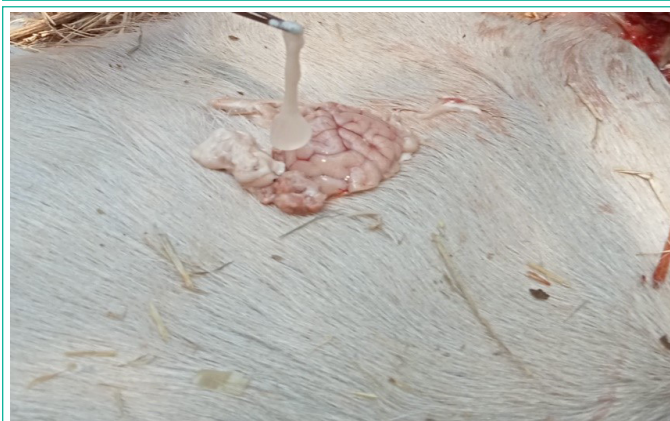In the last year, the outbreak has resulted in the deaths of 20 goats, the farm owner reported. The information provided by the animal attendant showed that depression, circling to the left, altered head position, uncoordinated movement (ataxia), paralysis, inability to browse properly, and death within a week. All age groups were affected, but the young were more affected than the older generation. The team tentatively defined for coenurosis cerebri and the confirmatory diagnosis for the disease was recommended by necropsy finding of the cyst. During a clinical examination, symptoms of a CNS disorder including paddling, convulsions, and unconsciousness were noted. Conjunctival hyperemia and keratitis were visible, and convulsion episodes were accompanied by opisthotonus, orthotonus, paddling, and oral foaming every 4-5 minutes. After the animal finally passed away from severe symptoms, a necropsy was carried out. We discussed a case of coenurosis in goats in this report, which was characterized by depression, circling to the left, altered head position, uncoordinated movement (ataxia), paralysis, inability to browse properly, and death within a week (Figure 1).



**Figure 1:** Typical symptoms of coenurosis cerebri.



**Figure 2A:** A cyst settled in the left cerebral hemisphere.



**Figure 2B:** A cyst after protruded from the brain.

### Methodology

#### Outbreak Areas

Dembecha is one of the woredas in the Amhara Region's West Gojjam Zone. Bure is to its west, Jabi Tehnan is to its northwest, Dega Damot is to its north, and the Misraq Gojjam Zone is to its east and south. The town is located 352 kilometers from Addis Abeba at latitude 10°33'N and longitude 37°29'E, with an elevation of 2083 meters above sea level. The outbreak took place on a private farm owned by Zangar Agricultural Development that is situated in a low land close to the Abay River in the Dembecha district's Makar lega bedessa kebele. Farm of Zangar Agricultural Development is located 70 kilometers from woreda town.

#### Results

Following the fieldwork, insightful conversations on the outbreak's cause were had with every staff. According to the attendant's information, villages where dogs and domestic animals coexist closely with domestic animals are much more likely to have the disease. Additionally, the majority of small ruminants are still slaughtered at home, and dogs in the village typically receive uncooked offal and carcass wastes. Finally, the team came up with a case definition for coenurosis cerebri, and after performing a necropsy, the disease was definitively diagnosed. Goats with coenurosis cerebri cysts were found to have them in their brains (Figure 2).

The necropsy finding of the cysts confirmed the case at the field level. Cysts were found during necropsy in the occipital lobe of the left cerebral hemisphere of the brain. The cysts had

a translucent fluid inside of them, and the inner layer of the cysts had numerous scolices growing out of it. The cysts' inner layer was distinguished by a thin transparent wall, while the outer layer had a thick fibrotic capsule. The parenchyma close to the cysts thinned, the cerebral gyri close to the cyst's superficial compartment flattened, and pressure atrophy took place.

### Discussion

Globally, coenurosis is a serious issue with sheep and goats. Numerous clinical symptoms, such as ataxia, blindness, circling, unsteadiness, drowsiness, head pressing, hind leg paralysis, and coma, have been reported in other studies [8] and were also seen in the current case. According to some evidence, goats are less likely than sheep to develop coenurosis. This might be because goats spend less time grazing on the ground than sheep do. Since they tend to eat more specialized foods than sheep and typically eat the leaves that are on top of shrub and tree branches. Sheep are also effective hosts for the development of *T. multiceps* and coenurosis [9].

One of the cysts in the current report was located on the left hemisphere's occipital lobe which similar with previous case [10]. Cysts interfere with CSF absorption as occupying masses and can raise intracranial pressure. Depending on the location, size, and level of pressure in the cerebral tissue, the clinical signs can vary [11]. Animals that are affected hardly ever exhibit clinical symptoms, and the cyst is typically only discovered after death or accidentally being killed. Finally, we described the discovery of CNS in *C. cerebralis* in a goat.

### Conclusion and Recommendation

Coenurosis disease occurs in brain and spinal cord of sheep and Goats caused by the intermediate stage of *Taenia multiceps* which inhabits the intestine of dogs, cats and wild carnivores. The best way of confirming the case was through clinical inspection and necropsy. The presence of free extending dogs and wild carnivores can worsen the spread of the parasite over a wide grazing land. Outbreak situation at about 20 goats were dead in the time outbreak, and daily goat deaths are occurring because there is no intervention. *Coenurus cerebralis* was identified in the outbreak case on the scene, and necropsies are typically used to confirm diagnoses.

The recommendations that follow were made in light of the aforementioned conclusion.

- The neighborhood residents should restrict dog access to pasture, and practice good hygiene to avoid ingesting *T. Multiceps* eggs.

- After slaughter, burn or bury the heads of small ruminants; do not give this part to dogs unless the owner is unsure of the effectiveness of deworming. Animal owners should properly dispose dead animals

- Entire communities should band together to regularly deworm all dogs using potent cestode medications (every three months).

- Community education Programs, need to show that the neglected tapeworm *T. multiceps* poses a threat to humans and livestock.

### Author Statements

#### Acknowledgments

I want to express my gratitude to the Animal Health Institute's expert team on behalf of this case investigation.

#### Conflict of Interest

The authors declare that there is no conflict of interest

#### References

1. Ajaj EA, Mohammad HA, Gharban HAJ. First molecular confirmation of *Coenurus cerebralis* in sheep and goats with neurological behaviors in Iraq. *Vet World*. 2021; 14: 1420-5.
2. Dubey JP, Sykes JE. 5<sup>th</sup> ed. 2022 'Sarcocystosis', *Greene's Infectious Diseases of the Dog and Cat*. 2022; 3: 1172-8.
3. Evangelisti MA, et al. Case Report Clinical evolution of cerebral coenurosis from invasive to chronic infection in sheep and a goat. 2016.
4. Gashe M, Sewalem M. Review on cerebral coenurosis in small ruminants. *Acta Parasitol Globalis*. 2017; 8: 130-8.
5. Ozmen O, Sahinduran S, Haligur M, Sezer K. Clinicopathologic observations on *Coenurus cerebralis* in naturally infected sheep. *Schweiz Arch Tierheilkd*. 2005; 147: 129-34.
6. Reza M, et al. A report on *Coenurus cerebralis* infection in a wild goat (*Capra aegagrus*). 2019; 10: 85-8.
7. Shiferaw A, Abdela N. Public health and economic significance cerebral coenurosis in sheep and goat: a review. 2018; 7: 54-65.
8. Soundararajan C, Sivakumar T, Balachandran C. *Coenurus cerebralis* and its pathology in an organized farm of Tamil Nadu. *J Parasit Dis*. 2017; 41: 510-3.
9. Varcasia A, et al. *Taenia multiceps* coenurosis: a review. *Parasites Vectors*. 2022: 1.
10. Zewde D, Ashagrie T. Coenurosis cerebralis case investigation in indigenous goat at Womberema District of North Western Ethiopia. *Austin J Vet Sci & Anim Husband*. 2022; 9.
11. Zone S, Diba S, Garoma A. Epidemiology and economic loss of coenurosis in small Ruminants slaughtered at mojo halal export abattoir, Oromia regional state, East. 2021; 7: 127-37.