

Clinical Image

Plantar Angioleiomyoma

Boussaidane M*, Boukhriss J, Chafry B, Benchebba D and Boussouga M

Department of Traumatology and Orthopedics, Military Hospital Mohammed V, Faculty of Medicine and Pharmacy of Rabat, University Mohammed V, Rabat, Morocco

***Corresponding author:** Boussaidane Mohammed, Department of Traumatology and Orthopedics, Military Hospital Mohammed V Rabat, Morocco

Received: November 08, 2021; **Accepted:** December 29, 2021; **Published:** January 05, 2022

Clinical Image

We report the case of a 47-year-old patient, with no particular pathological history, who had a subcutaneous mass on the plantar surface of the left foot for 9 months. The consultation was motivated by the inconvenience of the mass and the pain when walking. The examination found a plantar swelling of the left foot, 3cm long, of hard consistency, sensitive, well limited, and without modification of the opposite skin. MRI demonstrated the presence of a deep mass compared to the plantar fascia, well limited, hypointense in T1, T2 hypersignal, measuring 28x25x21 mm (Figure 1).

The patient underwent a complete resection of the mass. Macroscopic examination showed a well-defined, indurated mass of white color (Figure 2). Pathological examination of the surgical specimen confirmed the diagnosis of angioleiomyoma; with the presence of a leiomyomatous component and a vascular component. No recurrence was objectified with a follow-up of 1-year.

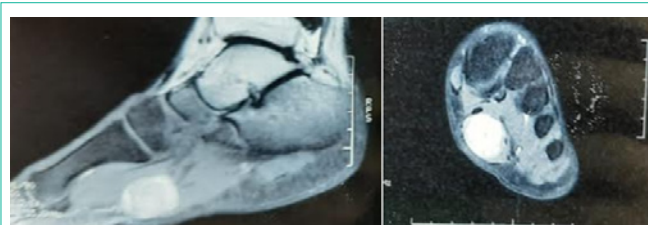


Figure 1: MRI of the left foot showing a tumor mass under the aponeurosis in T2 hypersignal.

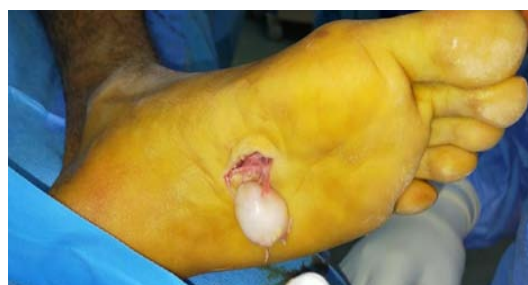

Figure 2: Intra operative appearance showing a whitish tumor formation at the plantar level.