

Case Report

Ocular Ophthalmomyiasis: Illuminating an Enigmatic Infection

Tlemcani Y^{1*}; Zaza Q²; Boujaada A¹; Robbana L¹; Elmajdoubi K¹; Abdallah Eh¹

¹Department of Ophthalmology B, Faculty of Medicine, Mohammed V University Rabat, Morocco

²Department of Parasitology-Myology, Mohammed V Military Training Hospital, Faculty of Medicine, Mohammed V University Rabat, Morocco

*Corresponding author: Tlemcani Y

Ophthalmology B department, Faculty of Medicine, Mohammed V University Rabat, Morocco
Email: Yns.tlemcani@gmail.com

Received: April 13, 2024

Accepted: May 07, 2024

Published: May 14, 2024

Introduction

Myiasis is a term that defines a condition characterized by infestation with fly larvae of the order Diptera affecting the living and dead tissues of humans and vertebrate animals. [1] Ophthalmomyiasis is the infestation of any anatomical structure of the eye. It is further subdivided into external ophthalmomyiasis and internal ophthalmomyiasis. [2] Fly species such as *Hypoderma*, *Calliphora*, *Sarcophaga*, *Gasterophilus*, *Cuterebra*, *Dermatobia* are known to cause ophthalmomyiasis. *Oestrus ovis* (*O. ovis*) is one of the most common causes of ophthalmomyiasis worldwide. Sheep and goats are the main hosts of this parasite, with humans being accidental hosts. [3] External ophthalmomyiasis refers to a superficial infestation of eye tissues. Conjunctival myiasis is the most common form. [2] Although it is cosmopolitan, the majority of reported cases are found in the Mediterranean basin and the Middle East. Morocco has reported numerous cases, especially in the northern regions and rural areas. We report a case of external human ophthalmomyiasis; the uniqueness of this case is the occurrence of the infection outside of a farming environment. We discuss the life cycle, clinical presentation, and therapeutic modalities of this infection and its complications.

Case Report

A 60-year-old urban patient presented to the ophthalmological emergency department with a sensation of a foreign body, pruritus and acute unilateral tearing.

Abstract

Ophthalmomyiasis is an infestation of the eye by fly larvae. *Oestrus ovis* is the most common causal agent of external ophthalmomyiasis worldwide. We report the case of an external ophthalmomyiasis caused by *Oestrus ovis* in a 60-year-old man living in an urban environment, with no history of contact with animals.

Keywords: External ophthalmomyiasis; *Oestrus ovis*; Conjunctivitis

The history-taking did not reveal any history of visits to rural areas. Visual acuity was 20/20 in each eye. Biomicroscopic examination of his left eye showed conjunctival hyperaemia without purulence and a normal anterior chamber and fundus. It also revealed the presence of small white, translucent larvae with a small head and blackish hooks that were highly mobile and photophobic, measuring approximately 1.5 mm in length, on the cornea, bulbar conjunctiva and upper and lower conjunctival fornix. (Figure 1) The larvae tried to disappear towards the fornixes under the slit lamp light. There was no intraocular or retinal involvement. A diagnosis of external ophthalmomyiasis was made.

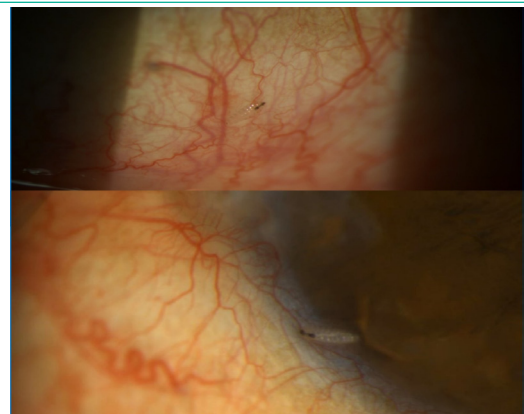


Figure 1: Slit-lamp photographs (magnified) view of conjunctiva showing first instar larvae (L1) of *Oestrus ovis*.

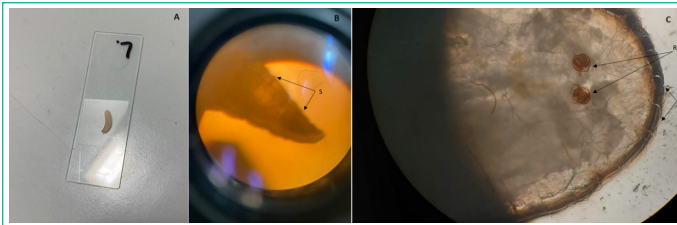


Figure 2: A- *Oestrus ovis* larvae between slide and coverslip; B- Observation of spines (S) throughout the body using x40 objective; C- Observation of respiratory stigma (RS) and bristles (B) using x100 objective.

Under local anaesthetic, the larvae were carefully extracted using a Bonn hook forceps, followed by an abundant rinse with physiological serum. After extraction, the larvae were placed in 70°C alcohol and sent to the laboratory for identification. The patient was put on topical antibiotic and steroid drops, as well as moistening and eyewash agents. The patient was recalled the following day for a check-up and no new larvae were observed. After 1 week, all symptoms regressed and clinical improvement was achieved. On direct microscopic examination, the larvae were all identified as first instar (L1) *Oestrus ovis* larvae (Figure 2).

Discussion

Ophthalmomyiasis is caused by the larvae of a cosmopolitan diptera called *Oestrus ovis*. The larvae develop on intermediate hosts: goats and sheep. Infestation of humans occurs accidentally when the larvae are deposited directly on the eye by a female fly in flight. Humans are only an accidental host, creating a parasite impasse. As the main hosts of *Oestrus ovis* are sheep and goats, ophthalmomyiasis is more commonly reported in people living in rural areas and among veterinarians working in these areas [3]. However, numerous cases of ophthalmomyiasis from different classes of society have been reported in the literature. [1], [3], [4] In accordance with the literature, our patient lived in an urban environment with no history of contact with animals.

External ophthalmomyiasis due to *Oestrus ovis* generally manifests as a clinical presentation similar to conjunctivitis. Symptoms include a sensation of a foreign body, excessive watering, conjunctival hyperaemia, pruritus, mild ocular pain and blepharospasm. These larvae have been reported to cause significant conjunctival eosinophilic infiltration resulting in non-necrotic granulomatous inflammation and eosinophilic degranulation that can lead to epithelial cell damage and calciform cell secretion [5]. The disease can then easily be misdiagnosed as conjunctivitis.

Treatment consists of gentle extraction of all larvae using a forceps after topical anaesthesia, followed by eyewash. Antibiotic eye drops and corticosteroids are prescribed to prevent infection and reduce inflammation. The condition generally

improves within 48 hours of treatment. *Oestrus ovis* larvae are unable to penetrate the cornea or sclera because they lack the ability to secrete proteolytic enzymes [6]. However, cases of internal ophthalmomyiasis due to *Oestrus ovis* have been reported [7], [8]. Early removal of the larvae is therefore very important, as if not treated, there is a risk of internal ophthalmomyiasis, a serious condition that can be life-threatening. Other species are capable of penetrating ocular tissues, so identification of isolated larvae is of crucial importance for a better understanding of the damage they can inflict to the eye. Hypoderma species are often presented as the main cause of internal ophthalmomyiasis [9].

Conclusion

Although symptomatically noisy, *Oestrus ovis* external ophthalmomyiasis remains benign if treated promptly. This condition can also be observed in people living in large cities, in which case immediate and careful examination is essential, in order to make the diagnosis by visualising the larvae and extracting them quickly.

References

1. Martinez-Rojano H, Huerta H, Sámano R, Chico-Barba G, Mier-Cabrera J, Plascencia-Nieto ES. Ophthalmomyiasis Externa and Importance of Risk Factors, Clinical Manifestations, and Diagnosis: Review of the Medical Literature. *Diseases*. 2023; 11: 180.
2. Francesconi F, Lupi O. Myiasis. *Trop Dermatology*. 2th Ed. Elsevier. 393–400.
3. Kunduracı MS, Kutlutürk I, Tanındı Duman G, Polat E. Ophthalmomyiasis Externa: A Case Report. *Turkiye Parazitoloj Derg*. 2020; 44: 261-263.
4. Carrillo I, Zarratea L, Suárez MJ, Izquierdo C, Garde A, Bengoa A. External ophthalmomyiasis: a case series. *Int Ophthalmol*. 2013; 33: 167-169.
5. Dutta Majumder P, Jeswani P, Jeyathilakan N, Biswas J. External ophthalmomyiasis due to *Oestrus ovis*. *Indian J Ophthalmol*. 2019; 67: 404-405.
6. Pather S, Botha LM, Hale MJ, Jena-Stuart S. Ophthalmomyiasis Externa: Case Report of the Clinicopathologic Features. *Int J Ophthalmic Pathol*. 2013: 2.
7. Parikh V, Biswas J, Vijayanthi K, Das D, Raval V. Bilateral ocular myiasis interna caused by botfly (*Oestrus ovis*): a case report. *Ocul Immunol Inflamm*. 2011; 19: 444-447.
8. Jenzeri S, Ammari W, Attia S, Zaouali S, Babba H, Messaoud R, et al. External ophthalmomyiasis manifesting with keratouveitis. *Int Ophthalmol*. 2009; 29: 533-535.
9. Lagacé-Wiens PR, Dookeran R, Skinner S, Leicht R, Colwell DD, Galloway TD. Human ophthalmomyiasis interna caused by *Hypoderma tarandi*, Northern Canada. *Emerg Infect Dis*. 2008; 14: 64-66.