

## Case Report

# Endogenous Endophthalmitis in a Patient with Colorectal Cancer: A Case Report

Homaide S<sup>1,2\*</sup>; Cheikh Z<sup>1,2</sup>; Hidan Y<sup>1,2</sup>; Mchachi A<sup>1,2</sup>;  
Benhmidoune L<sup>1,2</sup>; Rachid R<sup>1,2</sup>; Elbelhadji M<sup>1,2</sup>

<sup>1</sup>Faculty of Medicine and Pharmacy, Hassan II University of Casablanca, Casablanca Morocco

<sup>2</sup>Department of Ophthalmology, Hospital 20 August 1953, CHU Ibn Rochd, Morocco

\*Corresponding author: Soukaina Homaide

Faculty of Medicine and Pharmacy, Hassan II University of Casablanca, Casablanca Morocco.

Email: Salma\_moataz@hotmail.fr

Received: May 25, 2023

Accepted: June 23, 2023

Published: June 30, 2023

## Introduction

Endogenous Endophthalmitis (EE) is a relatively rare intraocular infection caused by hematogenous spread from distant foci. It is a diagnostic challenge engaging severally both, functional and vital prognosis. Early and prompt diagnosis and treatment in early stage are crucial to prevent blindness and lethal complications

## Case Report

A 58 years-old woman with a history of type 2 diabetes mellitus on oral medications, and recently diagnosed with a rectal Adenocarcinoma which was planned to be treated with chemotherapy and surgery. She presented with acute loss of vision and pain in her right eye for four days. There was no history of surgery or trauma and she was afebrile with no other systemic symptoms. Her ophthalmologic examination revealed a visual acuity at hand movement in the right eye and 10/10 in the left eye, with dense vitritis, eye fundus was not accessible (Figure 1). The left eye was normal. laboratory investigations showed: white cell count  $11.11 \times 10^3/\mu\text{l}$ , neutrophils  $7.41 \times 10^3/\mu\text{l}$ , lymphocytes  $2.56 \times 10^3/\mu\text{l}$ , C-Reactive Protein 80mg/L. Ocular ultrasound showed vitreous membranous debris, suggestive of endophthalmitis associated with subconjunctival abscess and choroidal detachment (Figure 2), Cranial and orbital MRI showed the presence of diffuse thick enhancement of the uveal layer, with increased signal intensity within the vitreous, with 20mm/11mm subconjunctival abscess, and abnormal enhancement of optic nerve (Figure 3). The patient was treated with intravenous and intravitreal injection of antibiotics, 1mg/0.1ml vancomycin, 2.25mg/0.1ml ceftazidime, fortified

## Summary

A 58 year-old woman with a history of diabetes mellitus and rectal Adenocarcinoma presented with acute loss of vision and pain in the left eye with hypopyon with no systemic symptoms at presentation. Diagnosis of endogenous endophthalmitis was made. Treatment was medical by topical, intravitreal and systemic antibiotics, with poor visual outcome. This case reminds ophthalmologists that endogenous endophthalmitis might be associated with underlying malignancy.

**Keywords:** Endogenous endophthalmitis; Diabetes mellitus; Visual acuity; Intravitreal injections; Vitrectomy

antibiotics eye drops, the evolution is marked by spontaneous drainage of sub conjunctival abscess (Figure 4) and regression of pain. She was later transferred to Oncology department for the treatment and follow up of her cancer.

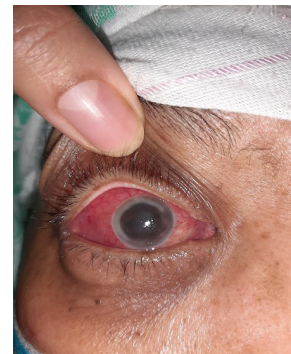

Figure 1: Right eyelid swelling, sub conjunctival abscess, corneal injection, and anterior chamber hypopyon.

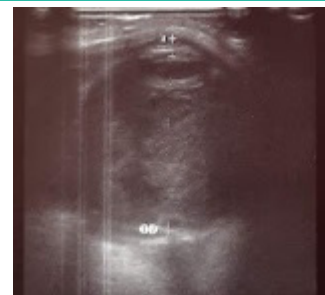
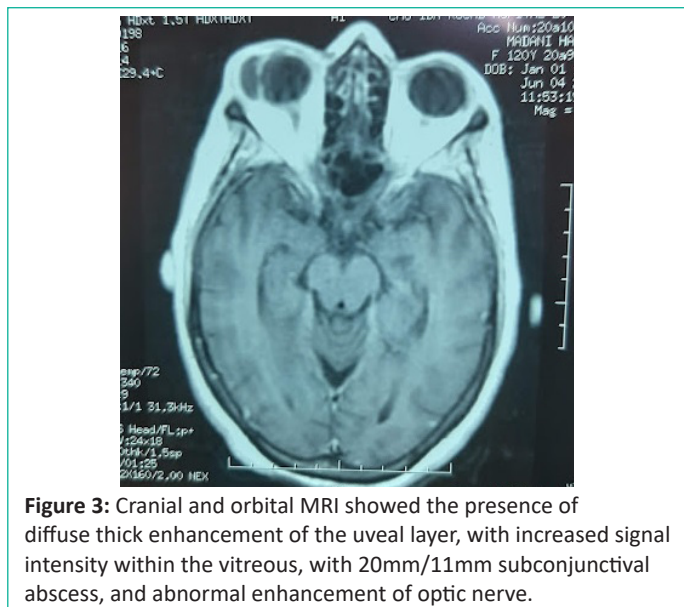


Figure 2: Right ocular ultrasound: vitreous membranous debris, suggestive of endophthalmitis associated with subconjunctival abscess and choroidal detachment.



**Figure 3:** Cranial and orbital MRI showed the presence of diffuse thick enhancement of the uveal layer, with increased signal intensity within the vitreous, with 20mm/11mm subconjunctival abscess, and abnormal enhancement of optic nerve.

### Discussion

Endogenous Endophthalmitis (EE) is an intraocular infection caused by the hematogenous spread of infectious agents from distant foci. It is a rare, but sight threatening condition, it represents 2–8% of all cases of Endophthalmitis [1] and most commonly reported in association with infectious endocarditis and liver abscesses [2,3] among male patients aged 50 years and above [4]. Multiple risk factors were described, such as: compromised immune system (cancer, acquired immunodeficiency syndrome, organ transplants), renal or hepatic diseases, endocarditis, urinary tract infections, catheters, intravenous drug abuse [5,6]. In our case, the main factors were rectal cancer and diabetes mellitus, Ciprian and al. found in their review of cases published between 2011 and 2022 that diabetes mellitus was a risk factor in 9.3% to 85.7% of patients, while malignancies were reported in 21.4% to 69.7% of cases [1]. The mechanism may be Mucosal defects on the tumour allowing bacteria to enter the blood circulation, and a compromised immunity by diabetes mellitus which compromises leucocyte functions and facilitate dissemination of the infection [7,8]. The clinical presentation is usually unilateral, but can be bilateral in 19–33% of cases [9,10], and associate systemic signs such as fever, chills, nausea, and vomiting caused by sepsis, to ocular finding including decreased vision, pain and redness, eyelid swelling, hypopyon, conjunctival and corneal injection, iritis, vitritis and retinitis [10,11]. Bacteriology of EE is variable predominated by Gram negative infections and *K. pneumoniae* is the most frequent microorganism (26.8% to 53% of patients) [12–14]. Management of endogenous endophthalmitis includes systemic and intravitreal antibiotics (or antifungals) and in some cases intravitreal corticosteroids [15]. Vitrectomy, for diagnosis or as a therapeutic option, may be performed in patients whose general states can support surgery, The indications are important vitreous opacities, diffuse retinal infiltration, poor initial visual acuity and in cases with no evident clinical improvement [14]. Prognosis of endogenous endophthalmitis is poor, especially if there is an important retinal involvement, a virulent organism, immunodeficiency, delayed diagnosis or complications [18]. Factors associated with good visual outcomes are a good initial visual acuity [16,17], early vitrectomy [14], intravitreal injection in the first 24 hours after diagnosis, and the presence of a focal type of EE [1].

### Conclusion

Endogenous endophthalmitis is a very serious condition, with poor final visual outcome. Early diagnosis and treatment are essential to prevent severe visual loss.

### Author Statements

#### Conflict of Interest

The authors declare no conflict of interest.

#### Contribution of the Authors

All the authors participated in the care of the patient and the writing of the manuscript. All authors have read and approved the final version of the manuscript.

### References

1. Ciprian Danielescu, Nicoleta Anton, Horia Tudor Stanca, Mihnea Munteanu. Endogenous Endophthalmitis: A Review of Case Series. *Hindawi Journal of Ophthalmology*. 2020; 2020: 8869590.
2. S Quill, N McEvoy, A Gabr, G Govender, O Ali. Endophthalmitis, *Clostridium Septicum* Bacteraemia and the Search for Colonic Malignancy. *Irish Medical Journal*. 2021; 114: P276.
3. Yue Wang, Xue Wang and Yu Di. Surgery combined with antibiotics for the treatment of endogenous endophthalmitis caused by liver abscess. *BMC Infectious Diseases*. 2020; 20: 661.
4. Wong JS, Chan TK, Lee HM, Chee SP. Endogenous bacterial endophthalmitis: an east Asian experience and a reappraisal of a severe ocular affliction *Ophthalmology*. 2000; 107: 1483-1491.
5. Maryama El Kaddoumi; Amazouzi Abdellah, Samira tachfouti; Ouafa Cherkaoui. WHEN AN ENDOGENOUS ENDOPTHALMITIS REVEALS COLON CANCER: A NEW GERM FOR SCREENING?!. *International Journal of advanced research (IJAR)*. 2019; 7: 1145-1149.
6. Seyedeh Maryam Hosseini, Ali Ahmadabadi, Seyed Hassan Tavousi, Majid Khadem Rezaian. Endogenous Endophthalmitis after Severe Burn:A Case Report. *Journal of Ophthalmic and Vision Research*. 2017; 12: 228-231.
7. Matsushita M, Hajiro K, Okazaki K, et al. Endophthalmitis with brain, lung, and liver abscesses associated with an occult colon cancer. *American Journal of Gastroenterology*. 2000; 95: 3664–5.
8. Chun Yue Mak, Helena Pui-yee Sin, Vesta Cheuk-ki Chan, Alvin Young. *Klebsiella* endophthalmitis as the herald of occult colorectal cancer: Case report. *BMJ Case Reports*. 2018; 2018: bcr2017223400.
9. Connell P, O'Neill E, Fabinyi D, Islam F, Buttery R, et al. Endogenous endophthalmitis: 10-year experience at a tertiary referral centre. *Eye (Lond)*. 2011; 25: 66-72.
10. Chung KS, Kim YK, Song YG, Kim CO, Han SH, et al. Clinical review of endogenous endophthalmitis in Korea:A 14-year review of culture positive cases of two large hospitals. *Yonsei Med J*. 2011; 52: 630-634.
11. Jackson TL, Paraskevopoulos T, Georgalas I. Systematic review of 342 cases of endogenous bacterial endophthalmitis. *Surv Ophthalmol*. 2014; 59: 627-635.
12. T Nishida, K Ishida, Y Niwa. An eleven-year retrospective study of endogenous bacterial endophthalmitis. *Journal of Ophthalmology*. 2015; 2015.

13. H Cho, YU Shin, NH Siegel, Yu HG, Sobrin L, et al. Endogenous endophthalmitis in the American and Korean population: an 8-year retrospective study. *Ocular Immunology and Inflammation*. 2018; 26: 496–503.
14. R Muda, V Vayavari, D Subbiah, H Ishak, A Adnan, et al. Endogenous endophthalmitis: a 9-year retrospective study at a tertiary referral hospital in Malaysia. *Journal of Ophthalmic Inflammation and Infection*. 2018; 8: 14.
15. D Ching, Wen Ho, A Agarwal, CS Lee, et al. Review of the role of intravitreal corticosteroids as an adjuvant to antibiotics in infectious endophthalmitis. *Ocular Immunology and Inflammation*. 2018; 26: 461–468.
16. Lim HW, Shin JW, Cho HY, Kim HK, Kang SW, et al. Endogenous endophthalmitis in Korea, a six-year retrospective study. *Retina*. 2014; 34: 592–602.
17. Nishida T, Ishida K, Niwa Y, Kawakami H, Mochizuki K, et al. An eleven-year retrospective study of endogenous endophthalmitis. *J Ophthalmol*. 2015; 2015: 261310.
18. Wu ZH, Chan RP, Luk FO, Liu DTL, Chan CKM, et al. Review of clinical features, microbiological spectrum and treatment outcomes of endogenous endophthalmitis over an 8-year period. *J Ophthalmol*. 2012; 2012: 265078.