

## Clinical Image

# Flower Iris: When an Ocular Blunt Trauma Leaves Its Mark

**Hnich H\*, Tazi H, Serghini L, Elhassan A, Boulanouar A and Berraho A**

Ophtalmology B Department, Hospital of Specialities, Rabat, Morocco

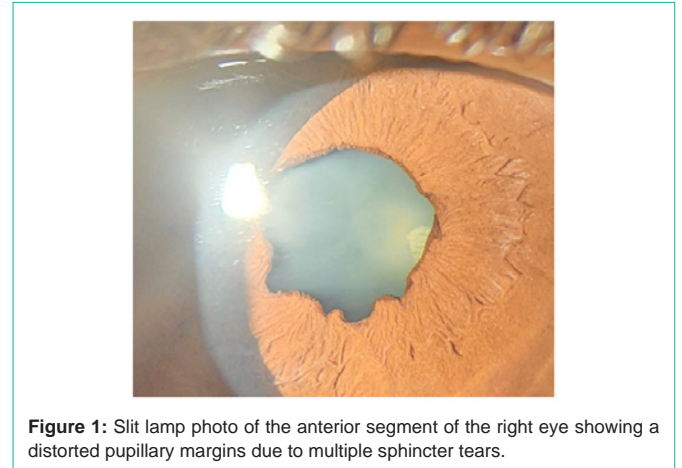
**\*Corresponding authors:** Hajar Hnich, Ophtalmology B Department, Hospital of Specialities, Rabat, Morocco

**Received:** April 11, 2022; **Accepted:** April 27, 2022;

**Published:** May 04, 2022

## Clinical Image

A 67 years old patient who denies any specific medical history, presented to ophtalmological consultation with decreased visual acuity in her right eye along with a chronic onset of photophobia, the best corrected visual acuity at snellen chart was 5/10 in the right eye and 8/10 in the left eye; the slit lamp examination of the right eye surprisingly found multiple sphincter tears giving a specific shape of the iris with a nuclear cataract (Figure 1). No angle recession or retinal tears were found. The patient underwent a surgical procedure for her cataract with a good visual outcome.



**Figure 1:** Slit lamp photo of the anterior segment of the right eye showing a distorted pupillary margins due to multiple sphincter tears.