

Clinical Image

Subluxation of the Crystalline Lens in Marfan Syndrome

Tazi H*, Hnich H, Naya K, Serghini L, Elhassan A and Amina B

Ophthalmology B, Ibn-Sina University Hospital, Rabat, Morocco

*Corresponding authors: Habiba Tazi, Ophthalmology B, Ibn-Sina University Hospital, Rabat, Morocco

Received: February 04, 2022; Accepted: February 25, 2022; Published: March 04, 2022

Clinical Image

A 17-year-old patient with Marfan syndrome consulted in the emergency department for sudden onset of bilateral ocular pain, with no history of previous trauma, associated with severe headaches and vomiting [1].

His uncorrected visual acuity was reduced to “counting fingers” in the right eye, slit lamp examination of the same eye showed major anterior dislocation (Figure 1) of a clear crystalline lens, with visible stretched zonules seen temporally.

Intraocular pressure obtained with aplanation tonometry was 35mmHg explaining the symptomatology. The patient was treated immediately with local and general hypotensive therapy [2].

Under general anesthesia, a phacoemulsification of the dislocated lens with pars plana vitrectomy was performed. Postoperatively, the intraocular pressure was normal, the cornea was clear, and no damage of the optic disc was noticed.

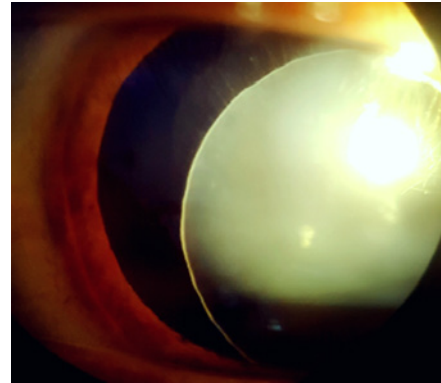


Figure 1: Slit lamp photograph of the right eye showing the subluxated crystalline with weakened zonules in patient with Marfan syndrome.

References

1. Dietz HC, Pyeritz RE. Mutations in the human gene for fibrillin-1 (FBN1) in the Marfan syndrome and related disorders. *Hum Mol Genet.* 1995; 4: 1799-1809.
2. De Paepe A, Devereux RB, Dietz HC, Hennekem RCM, Pyeritz RE. Revised diagnostic criteria for the Marfan syndrome. *Am J Med Genet.* 1996; 62: 417-426.