

Clinical Image

A Neonate with Acute Dacryocystitis

Tazi H*, Hnich H, Naya K, Serghini L, Elhassan A and Amina B

Ophthalmology B, Ibn-Sina University Hospital, Rabat, Morocco

*Corresponding authors: Habiba Tazi, Ophthalmology B, Ibn-Sina University Hospital, Rabat, Morocco

Received: February 04, 2022; Accepted: February 25, 2022; Published: March 04, 2022

Clinical Image

Acute dacryocystitis in neonates is an emergency condition that should be taken seriously [1]. We report a case of a 25-day-old male newborn with inflammatory swelling of the inner canthus of the left eye. The ophthalmological examination revealed unilateral lacrimal sac abscess with compression of the lacrymal sac (Figure 1). Orbital CT scan confirmed the presence of abscess, with mild preseptal cellulitis (Figure 2), no signes of ethmoidal sinusitis were shown. The newborn

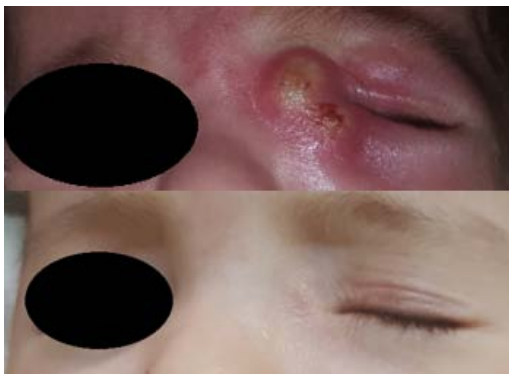

Figure 1: The clinical photograph of the face at the time of presentation showing unilateral acute dacryocystitis with lacrimal abscess formation. Note the regression of the collection after traitement.

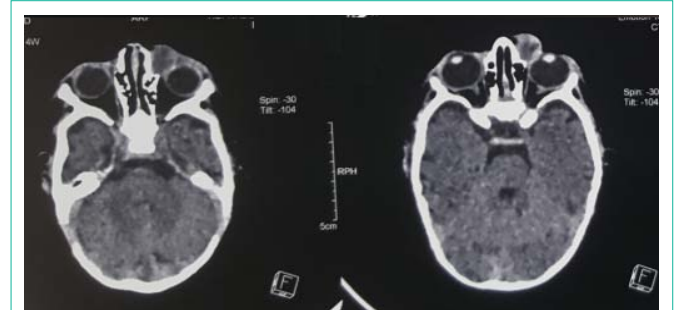


Figure 2: Axial orbito cerebral CT showing the abscess collection in the left eye.

was hospitalized and intravenous C3G antibiotherapy was started. Over the next day, we noticed an external fistula formation. General and local antibiotic therapy was continued for a short time, with a gentle massage of the lacrimal sac [2]. The evolution was marked by a progressive regression of the swelling as showed, and no recurrence of the condition was diagnosed in the follow up (Figure 1). This case is a reminder for our clinical practice to think of the presence of a potentiel dacryocystocele in every acute dacryocystitis in neonates.

References

1. Gregg T. Lueder. The association of neonatal dacryocystoceles and infantile dacryocystitis with nasolacrimal duct cysts (ana american ophthalmological society thesis). *Trans Am Ophthalmol Soc.* 2012; 110.
2. Evelyn A. Paysse. Management and complications of congenital dacryoceles with concurrent intranasal mucocele. *Journal of AAPOS.* 2000; 4.