

Clinical Image

Best Disease in 11 Years Old Boy

Tazi H*, Naya K, Serghini L, Elhassan A and Amina B

Ophthalmology B, Ibn-Sina University Hospital, Rabat, Morocco

*Corresponding authors: Habiba Tazi, Ophthalmology B, Ibn-Sina University Hospital, Rabat, Morocco

Received: February 04, 2022; Accepted: February 25, 2022; Published: March 04, 2022

Clinical Image

Best disease is a hereditary-degenerative macular dystrophy. In this case, we will describe an 11 year-old boy with no medical history presenting progressive decrease of visual acuity for 6 months without associated signs [1].

Ophthalmologic examination showed corrected visual acuity 5/10 in the right and 3/10 in the left eye; P4 near in both eyes. The examination of the anterior segment was normal. Intraocular pressure of both eyes was within the standards. In addition, fundus examination in the right eye showed a yellow macular lesion, with a large vertical axis, measuring about 2 papillary diameters with a fibrotic aspect [2]. However, in the left eye, we observed a similar lesion, oval, but with horizontal long axis, measuring about 3/2 papillary diameters with a grayish and irregular aspect in the center (Figure 1). The fluorescein angiography test showed in the right eye a hyperfluorescence surrounding an area of hypofluorescence confirming the appearance of fibrosis seen on fundus of the eye. In the left eye, the hyperfluorescence is limited to the lesion and irregular in the center (Figure 2). The patient was diagnosed Best Vitelliform macula.

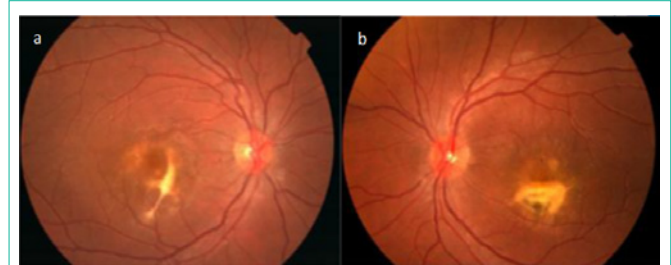

Figure 1: Right and left fundus showing yellow macular lesion.

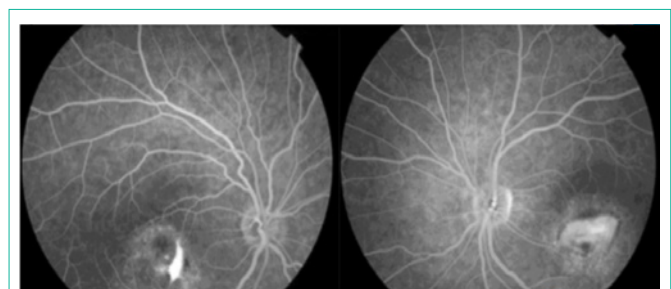


Figure 2: Right and left eyes fundus under fluorescein angiography.

References

1. Deutman AF, Hoyng CB. Macular Dystrophies. In: Schachat AP, Hengst TC. (eds.) Medical Retina. 3rd ed. London: Mosby. 2001: 1225.
2. Querques G, Zerbib J, Santacroce R, Margaglione M, Delphin N, Rozet JM, et al. Functional and clinical data of Best vitelliform macular dystrophy patients with mutations in the BEST1 gene. Mol Vis. 2009; 15: 2960-2972.