

Case Report

Displacement of Ex-PRESS Shunt Head Outside the Conjunctiva in a Uveitis Patient: A Case Report

Mohamed Osman¹, Ehab Y Alsirhy², Sulaiman M Altariqi² and Essam A Osman^{2*}

¹Department of Urgent and Emergency Care, Rotherham General Hospital, Rotherham, UK

²Department of Ophthalmology, King Abdulaziz University Hospital, King Saud University Medical City, Riyadh, Saudi Arabia

*Corresponding authors: Essam A Osman, Department of Ophthalmology, King Abdulaziz University Hospital, King Saud University Medical City, PO Box 245, Riyadh, 11411, Saudi Arabia

Received: September 24, 2021; Accepted: October 14, 2021; Published: October 21, 2021

Abstract

Ex-PRESS mini shunt is recently involved in trabeculectomy surgery with a good outcome. We present a 14-year-old male with a history of juvenile idiopathic arthritis, non-granulomatous anterior uveitis, and secondary glaucoma operated with trabeculectomy Ex-PRESS shunt in his right eye. The patient developed extrusion of the implant head outside the conjunctiva after 4 years of surgery. The patient admitted to the hospital with removal of Ex-PRESS shunt under general anesthesia with the suturing of the scleral defect and closure of the conjunctiva.

Keywords: Uveitis; Glaucoma; Ex-PRESS Mini Shunt

Introduction

Glaucoma filtration surgery is designated to reduce Intraocular Pressure (IOP) when maximal medical therapy fails to lower IOP sufficiently and prevent optic nerve damage [1]. Trabeculectomy surgery is the most common procedure for glaucoma filtration surgery since 1968 [2]. The placement of the Ex-PRESS glaucoma filtration device (Alcon, Fort Worth, TX) under a partial thickness scleral flap is one of the adjustments of glaucoma filtration surgery. The Ex-PRESS glaucoma filtration device is stainless steel (biocompatible, magnetic resonance imaging-compatible) non-valved device that shifts aqueous humor from the anterior chamber to the subconjunctival space and forms a filtration bleb, as seen in standard trabeculectomy [3]. The Ex-PRESS device eradicates the need for both peripheral iridectomy and removal of a deep corneoscleral tissue block compared with trabeculectomy, but these rewards require aligning the device properly to avoid contact with either the cornea or the iris. Evidence suggests that adding trabeculectomy using the Ex-PRESS device leads to a lower complication rate and a faster visual recovery [4]. We present a rare complication of displacement of the Ex-PRESS shunt head outside the conjunctiva with successful removal and wound closure without complications.

Case Presentation

A 14-year-old male with juvenile idiopathic arthritis and non-granulomatous anterior uveitis under treatment of mycophenolate mofetil and Prednisolone eye drops. The patient developed secondary angle-closure glaucoma in both eyes with Intraocular Pressure (IOP) of 41mmHg right eye and 24mmHg left eye, treated medically by combined Dorzolamide and Timolol eye drops. The history of this patient started in January 2015, his visual acuity was counting fingers (CF) right eye and 20/200 left eye, posterior subcapsular cataract both eyes, posterior synechiae and no fundus view (Figure 1).

In February 2016, the patient had trabeculectomy with Mitomycin C in his right eye in superior nasal quadrant, but the surgery failed after one month. Subsequently, repeated trabeculectomy with Ex-PRESS mini shunt under sclera flap had been done. One month later,

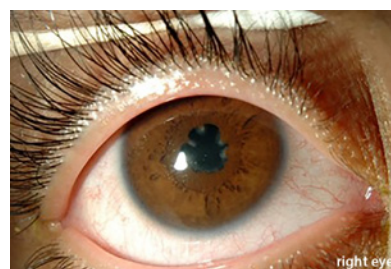


Figure 1: Posterior synechiae (OD).

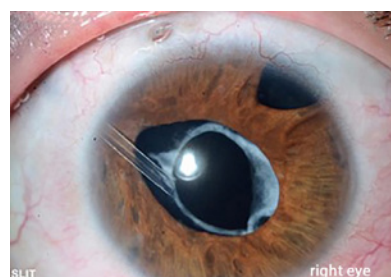


Figure 2: An exposed head of Ex-PRESS shunt outside the conjunctiva without an aqueous leak (OD).

the patient presented with an IOP of 35mmHg right eye, Suture lysis was done to control IOP and Brimonidine eye drop was started in his right eye which resulted in good IOP control. In 2017, lensectomy with anterior vitrectomy was done in both eyes with best corrected visual acuity was CF right eye and 20/25 left eye with healthy discs on funduscopy. Three months after lensectomy, the IOP raised again in the right eye, and Ahmed valve glaucoma surgery was done, and IOP was controlled until this date.

On December 2020, the patient presented for follow-up with an exposed head of Ex-PRESS shunt outside the conjunctiva without an aqueous leak in his right eye (Figure 2). His best corrected visual acuity of CF right eye and 20/25 left eye, IOP of 16mmHg right eye

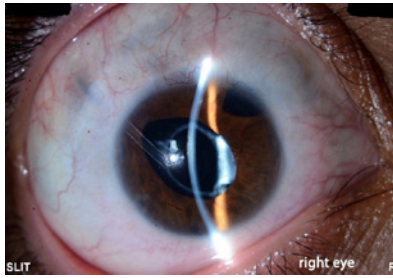


Figure 3: One-month follow-up (OD).

and 15mmHg left eye, and the patient was admitted to the hospital. Ex-PRESS was removed with suturing of scleral wound using vicryl 8-0. The conjunctiva over it undermined, approximated, and sutured postoperatively right eye, the wound covered well, IOP 10mmHg on no medication, no bleb leak, deep and formed anterior chamber. The patient was discharged from the hospital and seen after one week and one month without any complications, with controlled IOP and closed wound (Figure 3).

Discussion and Conclusion

Glaucoma is one of the leading causes of blindness worldwide is, and it continues to be a significant challenge in public health [5]. The rate of failure of trabeculectomy in uveitis glaucoma is high due to intraocular inflammation. In our patient, a decision taken to repeat the surgery of trabeculectomy with Ex-PRESS Minishunt despite closed angle is the extreme deep anterior chamber and possible less inflammation as no iridectomy.

When the Ex-PRESS shunt operation is placed under the conjunctiva, it can have complications such as hypotony, conjunctival erosion, shunt extrusion, or exposure. Dahan and Carmichael performed implantation under the scleral flap to prevent such complications [6]. Yong Ju Song presented impending extrusion of Ex-PRESS shunt in a 56-year-old Asian woman that after seven months of surgery, the internal opening was tilted to the corneal endothelium obliquely in the anterior chamber, and the external plate was prominent in the subconjunctival space [7]. Stein JD et al.'s recognized eight eyes of Ex-PRESS shunt exposure; two had been implanted under the scleral flap, and six others under the conjunctiva [8]. Kourin AS et al. reported one case of Ex-PRESS shunt scleral-flap implantation required shunt removal [9].

In our case, the Ex-PRESS shunt head was protruded outside the conjunctiva after four years of implantation. Removal of the shunt was a mandatory decision to avoid intraocular infection.

Extrusion and exposure of Ex-PRESS Minishunt is not a common complication. In our patient, the head of an implant was seen outside the conjunctiva. The removal of the shunt was mandatory to avoid endophthalmitis.

Declaration

Statement of Ethics: The authors adhered to the tenets of the 1964 Declaration of Helsinki. Written informed consent from the patient for the publication of this report were obtained. We asked the institutional review board (We need IRB approval).

Acknowledgment: The authors thank Mrs. Crimalis Longanilla-Bautista of the Department of Ophthalmology, King Abdulaziz University Hospital, King Saud University Medical City for the editing, image processing, and formatting of the manuscript.

Author contributions: In the Author Contributions section, a short statement detailing the contributions of each person named as an author should be included. Contributors to the paper who do not fulfil the ICMJE Criteria for Authorship should be credited in the Acknowledgement section.

References

- Hendrick AM and MY Kahook. Ex-PRESS mini glaucoma shunt: surgical technique and review of clinical experience. *Expert Rev Med Devices*. 2008; 5: 673-677.
- Shaarawy T, I Goldberg and R Fechtner. EX-PRESS glaucoma filtration device: Review of clinical experience and comparison with trabeculectomy. *Surv Ophthalmol*. 2015; 60: 327-345.
- Nyska A, et al. Biocompatibility of the Ex-PRESS miniature glaucoma drainage implant. *J Glaucoma*. 2003; 12: 275-280.
- Netland PA, et al. Randomized, prospective, comparative trial of EX-PRESS glaucoma filtration device versus trabeculectomy (XVT study). *Am J Ophthalmol*. 2014; 157: 433-440.e3.
- Salim S, et al. Surgical outcomes of the Ex-PRESS glaucoma filtration device in African American and white glaucoma patients. *Clin Ophthalmol*. 2012; 6: 955-962.
- Dahan E and TR Carmichael. Implantation of a miniature glaucoma device under a scleral flap. *J Glaucoma*. 2005; 14: 98-102.
- Song YJ, S Kim and GJ Yoon. Impending extrusion of Ex-PRESS shunt treated by shunt-position adjustment: a case report. *BMC Ophthalmol*. 2018; 18: 4.
- Stein JD, et al. Exposure of Ex-PRESS Miniature Glaucoma Devices: case series and technique for tube shunt removal. *J Glaucoma*. 2007; 16: 704-706.
- Khoury AS, et al. Technique for removal of malpositioned Ex-PRESS glaucoma device. *J Glaucoma*. 2014; 23: 435-436.