

Clinical Image

Juvenile Ankylosing Spondylitis - Associated Uveitis

Naya K*, Lidya I, Hasnaoui I, Tazi H, Erradi A, Bardi C, Abdallah E and Berraho A

Department of Ophthalmology B, Ibn-Sina University Hospital, Rabat, Morocco

***Corresponding authors:** Kaoutar Naya, Department of Ophthalmology B, Ibn-Sina University Hospital, Rabat, Morocco

Received: May 25, 2021; **Accepted:** June 05, 2021;

Published: June 12, 2021

Clinical Image

Juvenile ankylosing spondylitis is a chronic arthropathy that predominantly affects boys after the age of 10 years. We report a clinical case of a 16 years old aged male, who presented in the emergency room with a painful red eye, severe photophobia, and tearing right eye. The slit lamp examination was showing unusual anterior uveitis with hypopyon. The visual acuity was 2/10 in the right eye. The slit lamp examination of the left eye was unremarkable. The clinical results were in favour of Juvenile ankylosing spondylitis (Figure 1).

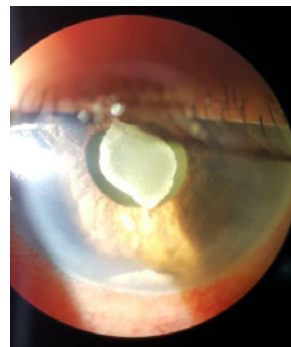


Figure 1: Unusual anterior uveitis with hypopyon.