

Clinical Image

Conservative Management of Persistent Pupillary Membranes in Young Adult

Khanaouchi N*, Abdellaoui T, bougguar M, Mouzarii Y, Reda K and Oubaaz A

Department of Ophthalmology, Military Instruction Hospital Mohammed V, Rabat, Morocco

*Corresponding authors: Nawal khanaouchi, Department of Ophthalmology, Military Instruction Hospital Mohammed V, Rabat, Morocco

Received: May 11, 2021; **Accepted:** May 28, 2021;

Published: June 04, 2021

Abstract

Pupillary membranes are mostly encountered in infant. They present the remnants of anterior tunica vasculosa lentis which nourishes the lens during fetal life, their regression generally begins from the sixth month of gestation. However in some cases they may persist and cause a visual impairment. The management of PPM depends on the size of pupillary aperture, the extent of the membrane, and its visual impact.

Keywords: Pupillary membranes; Tunica vasculosa lentis; Conservative management

Introduction

Persistent Pupillary Membranes (PPM) are congenital abnormalities which results from an incomplete involution of tunica vasculosa lentis, and are uncommonly seen in adults. We report a case of a 33 years old man treated, successfully, with conservative management, to emphasize the importance of this therapeutic option, which is even recommended, recently in cases with dense PPMs with good visual acuity.

Clinical Image

We report a case of a thirty-three year-old man who complained of low vision. Slit lamp examination revealed thick pigmented Persistent Pupillary Membrane (PPM) in the left eye (Figure 1). There were some points of attachment between membranes and lens. His Visual Acuity (VA) was 20/25 OD and 20/50 OS without correction of the refractive error, 20/20 with correction, in both eyes. With acceptable correction of VA by mydriatics and refractive correction, we opted for a conservative management of this case.

Discussion

Pupillary membranes persistence represents a frequent congenital ocular anomaly seen in 95% of neonates and 20% of adult population [1]. It is thought to be derived from the Tunica Vasculosa Lentis (TVL) that nourishes the lens during first 6 months of fetal life [2]. This normally atrophies in the third trimester to form the pupillary aperture.

Pigmented strands persist on the anterior iris surface when the tissue fails to regress during late fetal or early neonatal development. Usually PPM had no clinical significance [3]. They can be unilateral or bilateral and can be variable in appearance, size, configuration, and density. Most of the times, it can be seen as thin, lacy strands of iris tissue running from the collarette.

Treatment of PPM depends on the extent of the membrane, and consequently the size of the pupillary aperture [1]. Small PPMs can be followed up without any intervention, there for some cases may require employment of mydriatics, refractive correction and patch-therapy for preventing amblyopia in enfant (Figure 2).

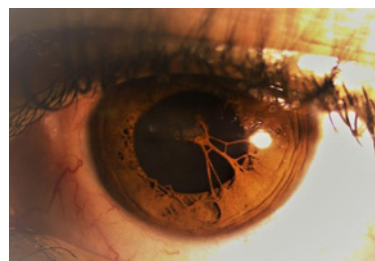


Figure 1: Thick pigmented Persistent Pupillary Membrane (PPM) in the left eye with points of attachment between membranes and lens.

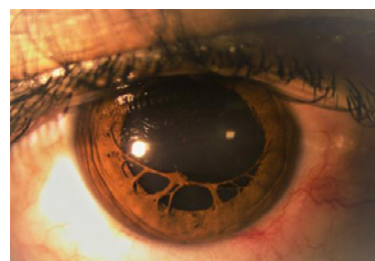


Figure 2: Liberation of the attachment between the lens and PPM after treatment with mydriatics.

Other ways, if the pupillary aperture is less than 1.5 mm, it may decrease retinal illumination and diffraction results in impaired vision. In this case, Nd:YAG laser can be applied for the disruption of the PPM, however because of the probability of the presence of blood vessels it is associated with the risk of developing hyphema and subsequently cataract [2,4]. Finally, in some cases surgical excision of the membrane may be mandatory.

Conclusion

PPMs in adults are uncommon, conservative medical management is the mainstay treatment, in case of small membranes with sufficient pupillary opening.

References

1. A rare case of persistent pupillary membrane: Case-based approach and

-
- management. Indian J Ophthalmol. 2018; 66: 1480–1483.
 2. Burton BJL, Adams GGW. Persistent pupillary membranes. British Journal of ophthalmology. 1998.
 3. Persistent pupillary membrane Successful Medical Management. 1979.
 4. Vega LF, Sabates R. Neodymium: YAG laser treatment of persistent pupillary membrane. Ophthalmic Surg. 1987; 18:452–454.