

Clinical Image

Upside Down Hypopyon

Tamym B*, Chabbar I, Bouzouba T and Berraho A
Service d'ophtalmologie B, hôpital de spécialités de rabat,
Morocco

***Corresponding authors:** Tamym Bouchra, Service
d'ophtalmologie B, hôpital de spécialités de rabat,
Morocco

Received: February 17, 2020; **Accepted:** April 16,
2020; **Published:** April 23, 2020

Clinical Image

We report the case of an inverted hypopyon following a rhegmatogenic retinal detachment surgery, in a 50-year-old patient, benefiting from a vitrectomy with tamponade in silicone oil. Slit lamp examination revealed a “reverse hypopyon” in the right eye, which was in fact emulsified silicone oil that had migrated from the posterior chamber into the anterior chamber accumulating in a superior manner (Figure 1).

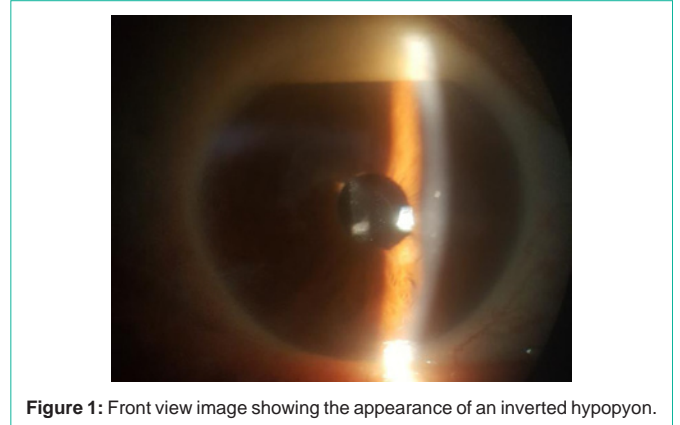


Figure 1: Front view image showing the appearance of an inverted hypopyon.