

Case Report

A Rare Case of Paediatric Interstitial Linear Keratitis

Vadboncoeur J^{1*}, Hassanaly S¹, Fortin E², Fallaha N² and Choremis J²

¹Department of Ophthalmology, Université de Montréal, Montreal, Quebec, Canada

²Department of Ophthalmology, Montreal, Quebec, Canada

*Corresponding authors: Vadboncoeur Julie, Department of Ophthalmology, Université de Montréal, Montreal, Quebec, Canada

Received: October 26, 2017; Accepted: November 21, 2017; Published: November 28, 2017

Abstract

Background: Linear interstitial keratitis is a rare clinical entity of unknown etiology. A handful of cases have been detailed in the last 30 years.

Methods: Case report with clinical and optical coherence tomography correlation.

Results: We present a case of unilateral, recurrent linear corneal infiltrate in a teenage girl. Response to topical therapy was favorable and visual prognosis remained excellent throughout both documented episodes. Extensive systemic workup failed to clarify a specific causative agent.

Conclusion: Immunoinflammatory processes may be implicated in the pathogenesis of this rare diagnosis. The implication of a subspecialty team is preferable to ensure appropriate and timely management of the disease. Further publication of similar cases is necessary to better elucidate the exact etiology of this disease.

Keywords: Linear keratitis; Interstitial keratitis; Pediatric; Anterior segment optical coherence tomography

Abbreviations

AS-OCT: Anterior Segment Optical Coherence Tomography; AKC: Allergic Keratoconjunctivitis; MMP: Matrix Metalloproteinase; VKC: Vernal Keratoconjunctivitis

Introduction

Linear interstitial keratitis is a rare corneal condition described in a few case reports. Collomb [1], in 1923, proposed the first description of this condition depicting an inflammatory linear keratitis and introduced it as superficial migrating keratitis. Throughout the years, Fuchs [2], Engelbrecht [3], Vejdovsky [4], Coop [5] and Grabner [6] characterized a similar condition that was referred to as keratitis linearis migrans. Calvo [7] recently proposed that all the previous cases, in addition to the ones he had presented, were all illustrating a distinct clinical entity named linear interstitial keratitis. At the time, no Anterior Segment Optical Coherence Tomography (AS-OCT) was acquired and the etiology of the entity remained unclear. We Report a rare case of a young teenager, who had an extensive workup and serial AS-OCT, with recurring Episodes of what is allegedly linear interstitial keratitis.

Case Presentation

An 11-year-old girl presented for the first time at our university-based tertiary center with complaints of Pain, irritation and photophobia in the right eye. The patient was known for allergic rhinitis. Besides mild myopia, she had no other past ocular history.

At first visit, visual acuity was 20/40 in the presenting right eye and 20/20 in the unaffected left eye. Examination of the anterior segment revealed a linear corneal infiltrate stretching from the corneoscleral limbus at 11° clock to the corneoscleral limbus at 3° clock (Figure 1). The infiltrate involved the anterior and middle stroma with thinning mainly located at the nasal side. There was a mild reaction in the

anterior chamber (1+ cell, no flare) with no hypopyon. Anterior Segment Optical Coherence Tomography (AS-OCT) imaging did not display any significant alteration of corneal anatomy other than slight thinning nasally. The patient was hospitalized and treated with hourly fortified tobramycin drops (14mg/mL) alternating with fortified vancomycin drops (25mg/mL). Cultures were negative for bacteria and fungi. After a 2-week tapering of the fortified antibiotics, topical 0, 1% fluorometholone was added to the regimen and then slowly tapered. She responded well to therapy with a residual thinning of the corneal stroma. At resolution of this episode, cycloplegic refraction in the right eye was -3.00+ 2.50x 55, yielding 20/20 visual acuity.

Three years later, she presented with a recurrence. A course of fortified topical antibiotics with both vancomycin and tobramycin was reinitiated. Since cultures were negative, ant biotherapy was modified for moxifloxacin 4 times daily. The patient was referred to both cornea and uveitis services to complete assessment. On biomicroscopy, diffuse palpebral papillae were noted on all four eyelids. The infiltrate was similar in appearance to that described previously, with corneal thinning greater than 50%, and a 4 negative Seidel test (Figure 2). AS-OCT was obtained during this recurrence and clearly showed the corneal thinning involving the anterior and mid-stroma (Figure 3). Prednisolone acetate 1% drops were added 4 times daily initially and tapered over 4 weeks. Multiple blood tests were ordered and yielded normal complete blood count, biochemistry and angiotensin-converting enzyme assays. Lupic anticoagulant, antiphospholipid antibodies, p-ANCA and c-ANCA were all negative. Serologic testing for toxoplasmosis, syphilis, bartonella and Lyme disease were negative. The tuberculin skin test was negative. Neither granulomatous stigmata nor hilar lymph nodes were present on chest radiography. After the extensive workup, a presumptive diagnosis of recurrent linear interstitial keratitis with no apparent precipitating factor was made.

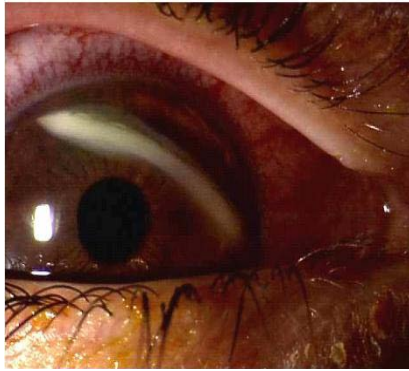


Figure 1: Slit-lamp color photograph of corneal infiltrate at first visit.

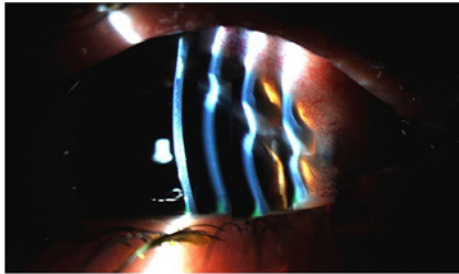


Figure 2: Multiple-beam reconstruction slit lamp photograph showing progressive thinning towards the nasal side of the infiltrate.

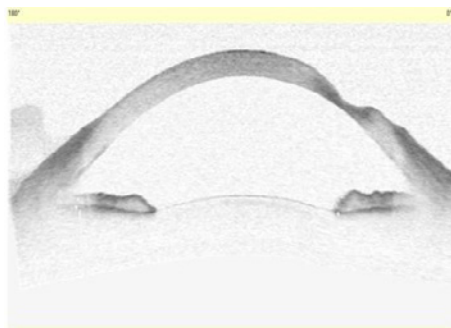


Figure 3: Cross-sectional anterior segment optical coherence tomography (Visante Omni; Carl Zeiss Meditec, Jena, Thuringia, Germany) during recurrence in 2014, clearly demonstrating the anterior- and mid-stromal thinning.

On last follow-up, 18 months after her recurrent episode, her best-corrected visual acuity was 20/20 in both eyes. The anterior segment examination revealed the well-healed linear interstitial corneal scar with stromal thinning mostly nasally. The patient continued her treatment with olopatadine drops for her allergic conjunctivitis.

Discussion

Over the past century, few cases have portrayed what is now recognized as linear interstitial keratitis the etiology of this corneal condition remains unknown. Fuchs [2] and Vejdovsky [4] proposed that syphilis contributed to the disease, but this hypothesis was refuted with the next cases as none of the patients tested positive

for syphilis. Calvo [7] was the first to evoke the possibility of an underlying autoimmune process and even suggested that Fuchs [2] and Vejdovsky [4] patients' positive syphilis serologies may represent false-positive results in the setting of inflammatory markers [7]. Our patient had no known underlying autoimmune or inflammatory condition; her only likely significant medical history was her allergic rhinitis. Her slit-lamp exam even displayed signs of Allergic Keratoconjunctivitis (AKC) during and after the recurrent episode. Patients with atopic Keratoconjunctivitis are at increased risk for keratoconus. Interestingly, the cornea of patients with keratoconus and AKC is thinner and steeper than that of non-AKC related keratoconus [8]. Mechanic factors, such as eye rubbing, are proposed but other Immunoinflammatory etiologies are at the forefront in the most recent papers. Of interest, Matrix Metalloproteinase (MMP) is derivative enzymes involved in the normal tissue remodelling and have been linked in the keratoconus physiopathology [8]. High level of MMP-2 and MMP-9 were found in the tear fluid of the vast majority of patients with Vernal Keratoconjunctivitis (VKC) and a portion of patients with AKC [9]. We could speculate that, somewhat like in keratoconus, the stromal thinning in linear interstitial keratitis could be linked to an imbalance in MMP levels caused by an atopic process. It will be pertinent to continue monitoring our patient, now treated with an antihistaminic agent, to observe if the topical treatment helps to prevent any further recurrence.

More cases are needed in order to gain a better understanding of the underlying pathogenicity of this unusual and very rare corneal disease. As no infectious agents have yet been identified and an Immunoinflammatory process has been suggested, a careful examination and extensive workup with a subspecialty team approach are highly recommended.

Acknowledgment

The authors would like to thank Charlene Provost for her expertise in photography editing.

References

1. Collomb A. Un cas rare de keratite superficielle (keratite superficielle migratrice). *Rev Gen Ophthalmol.* 1923; 37: 285.
2. Fuchs A. Über einige seltene luetische Erkrankungen des Auges. *Zeitschrift für Augenheilkunde.* 1926; 58: 315-342.
3. Engelbrecht N. Keratitis parenchymatosa migrans. *Klin. Monatsbl. Augenheilkd.* 1927; 78: 103.
4. Vejdovsky V, editors. In: *Keratitis linearis migrans.* *Br J Ophthalmol.* 1963; 47: 504-506.
5. Coop DH. Interstitial linear keratitis. *Br J Ophthalmol.* 1968; 52: 901-910.
6. Grabner G. Über die interstitielle lineare keratitis. *Klin Monbl Augenheilkd.* 1979; 174: 567-571.
7. Calvo CM, Sikder S, Mamalis N, Mifflin MD. Linear interstitial keratitis: a distinct clinical entity revisited. *Cornea.* 2012; 31: 1500-1503.
8. Naderan M, Rajabi MT, Zarrinbakhsh P, Bakhshi A. Effect of allergic diseases on keratoconus severity. *Ocul Immunol Inflamm.* 2016; 25: 1-6.
9. Kumagai N, Yamamoto K, Fukuda K, Nakamura Y, Fujitsu Y, Nuno Y. Active matrix metalloproteinases in the tear fluid of individuals with vernal Keratoconjunctivitis. *J Allergy Clin Immunol.* 2002; 110: 489-491.