

Clinical Image

Unilateral Nuclear Dusty Congenital Cataract Left Untreated

Hnich H*, Serghini L, Hajji Z, Abdellah E, Aboulanouar A and Berraho A
Ophthalmology B Department, Hospital of Specialties, Rabat, Morocco

***Corresponding authors:** Hnich H, Ophthalmology B Department, Hospital of Specialties, 51000, Rabat, Morocco

Received: November 02, 2021; **Accepted:** November 25, 2021; **Published:** December 02, 2021

Clinical Image

A 23 years old male patient with a history of unilateral deterioration of vision in his left eye since early childhood, consulted for the first time in his life for ophthalmological examination, his visual acuity at Snellen chart was 10/10 in right eye with no abnormalities in slit lamp examination, whereas the best corrected visual acuity of his left eye was reduced to 1/10, the slit lamp revealed nuclear dusty cataract, the examination of the fundus was unremarkable. Seen the amblyopia due to late consultation, the prognosis of a surgical approach was poor, however, the patient underwent a phacoemulsification procedure with intra ocular lens, the post-operative corrected visual acuity slightly improved to 3/10 (Figure 1 and 2).

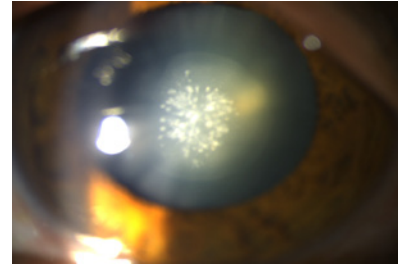


Figure 1: Anterior photograph of the left eye showing the dusty aspect of the nuclear cataract visible through a dilated pupil.

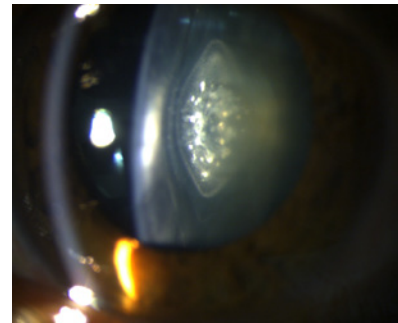


Figure 2: The dusty nuclear cataract of left eye seen in profile.