

## Clinical Image

# Cerulean Cataract in a Person with Down's Syndrome

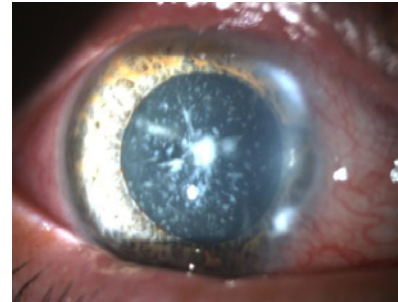
**Madbouhi K\* and Cherkaoui O**

Ophtalmologie A, Hôpital des Spécialités, Université Mohammed V Souissi, Rabat, Morocco

**\*Corresponding authors:** Madbouhi K, Ophtalmologie A, Hôpital des Spécialités, Université Mohammed V Souissi, Quartier Souissi, Rabat, Morocco**Received:** July 31, 2021; **Accepted:** August 12, 2021;**Published:** August 19, 2021

## Clinical Image

We report the case of an 18-year-old patient who consults for a loss of visual acuity in the right eye for 1 year. On clinical examination, visual acuity is 20/100. Eye tone is 12 mmHg. Examination of the anterior segment shows the existence of a cataract made up of whitish opacities corresponding to a congenital cerulean cataract (Figure 1). The treatment consisted of a cataract cure by phacoemulsification with good progress. Cerulean cataract is a rare congenital form of bluish tint, made up of whitish opacities in concentric layers with a radial arrangement at their center. Visual acuity is fairly good in childhood but may deteriorate later. In the literature, the incidence of cataracts



**Figure 1:** Image of the anterior segment showing a cerulean cataract.

in Down's children ranges from 5% to 50%. In previous studies of congenital or infantile cataract, 3-5 % of cases were associated with Down's syndrome [1].

## References

1. Haargaard B and Fledelius HC. Down's syndrome and early cataract. *Br J Ophthalmol.* 2006; 90: 1024-1027.