

Case Report

A Case of Patient with Symptoms of Small Fiber Neuropathy Following Frostbite

Do-Hyung Kim*

Department of Neurology, Eulji University Hospital, Republic Korea

***Corresponding author:** Do-Hyung Kim, Department of Neurology, Eulji University Hospital, School of Medicine, Eulji University, DunsanSeo-ro 95, Seo-gu, Daejeon, 35233, Republic Korea**Received:** October 06, 2016; **Accepted:** November 09, 2016; **Published:** November 11, 2016**Abstract**

It is known that cold temperatures can have damaging effects on peripheral nerves. However, there have been very few documented cases in the medical literature of peripheral Small Fiber Polyneuropathy (SFN) as a result of accidental hypothermic exposure. A 50-year-old man developed severe pain and tingling sensation in both feet following exposure to hypothermia from hiking.

Keywords: Frostbite; Small fiber polyneuropathy; Neuralgia; Paresthesia**Introduction**

Non-Freezing Cold Injury (NFCI) occurs when extremities, particularly feet, are exposed to a cold and damp environment. Most previously reported patients with NFCI were soldiers, who participated in outdoor activities during the winter, and typical examples are cases of trench foot during World War I and immersion foot, which developed in the crew of a wrecked ship during World War II; however, NFCI has also been reported among many civilians. Frostbite is the more severe type of Cold Injury (CI) than NFCI. The cold causes direct tissue damage, ice crystals damages cells, blood flow slows, blood clots form and there is ischemic tissue injury of the affected areas. CI can often cause peripheral neuropathy, and recent studies have reported that injury to large, myelinated fibers is obvious but lacking in small, myelinated, or unmyelinated fibers [1]. As injury progresses, fine, terminal cutaneous nerves can also be injured, but this type of injury is rare and has not been found in all reported studies [1].

Since most CI-induced cases of neuropathy affect large, myelinated fibers, motor symptoms are more common than sensory symptoms. However, we have observed a patient with Small Fiber Neuropathy (SFN) complaining of sensory symptoms limited to both feet after frostbite and report the case with a literature review here.

Case Report

A 50-year-old male patient visited an outpatient clinic of a neurology department due to tingling sense, numbness, severe pain, and cold sense on both soles of the feet from the tip of the toes to the area immediately anterior to the heels. Nearly three months ago, in February, the patient had severe frostbite on the tips of the toes on both feet after an accident in the mountains; afterwards, severe pain began in both feet. The patient went to mountain climbing 2-3 times a month as a hobby. On the climb day, there was already about 10-centimeters of snow in the mountain, which was about 1,500 meters altitude above sea level. It was a mild cloud and windy day. Temperature fallen to 18-degree below freezing point, and he recalled his feet seeming to be cold. He got set with all mountain-climbing equipment. The patient began climbing the cold mountain, but not much later, he was aware of he was lost. As time went on, the patient's hiking boots had gotten soaked and he began to feel the

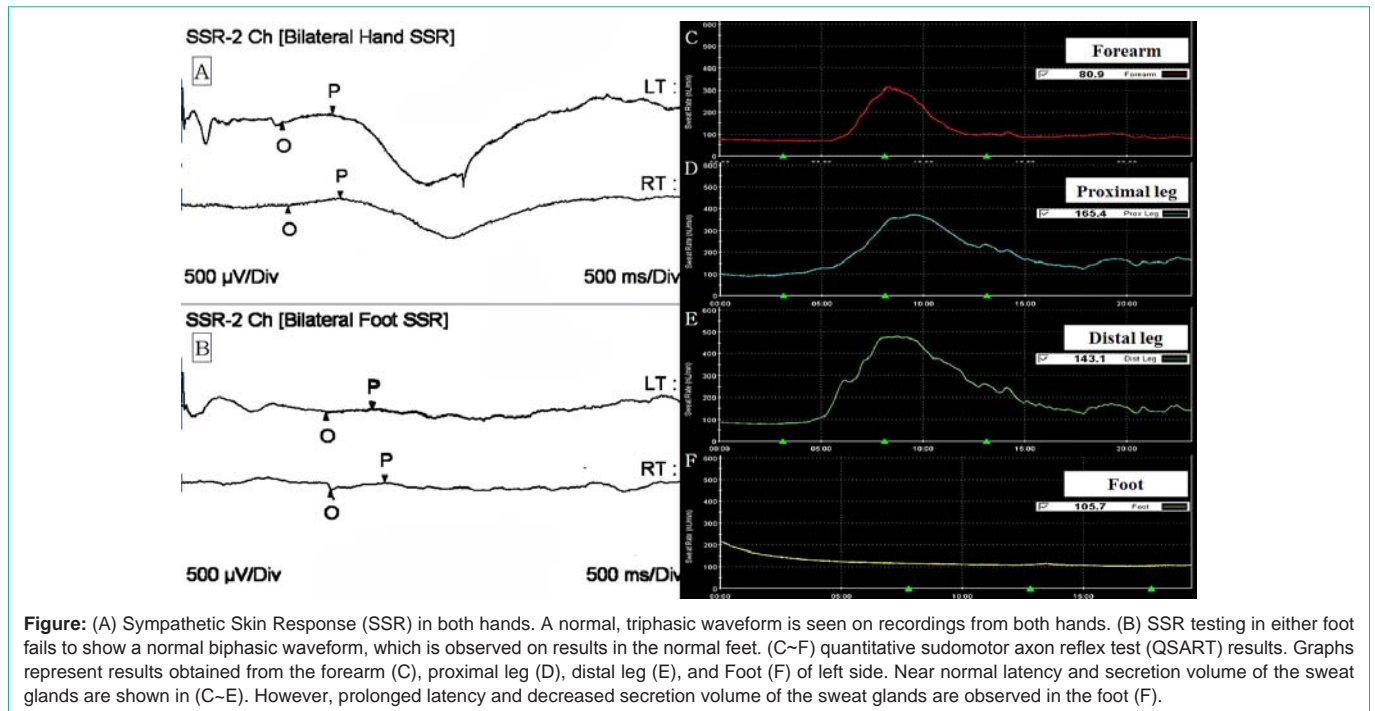
pain on both feet and pain was more exacerbated (left foot was even more). It became excruciatingly pain. The patient eventually decided to go back the way he had come. He had been roaming the cold and snow mountain for more than 6 hours. The patient was rescued, and taken directly to the surgical hospital from the mountain by ambulance. The patient presented with all finger of both hands and both feet involved; however, only the tips of the toes had turned dark, representing blisters; the rest of feet were grey or white colored. Most of the toe tissue involvement demonstrated secondary or tertiary degree frostbite characterized by color change and some vesicle with clear and hemorrhagic fluid content.

In initial primary treatment, the patient was rewarmed of all extremities in water bath at 40°C with added chlorhexadine for 1 hour and clear blisters were aspirated. Topical aloe vera gel was applied to thawed tissue before dressings are applied. Both feet were splinted, elevated and loosely wrapped with protective padding after dressing for 4 weeks. The silver sulfadiazine was applied to the vesicle wound. The patient was confirmed he was immunized against tetanus. He was taken oral ibuprofen 400 mg twice a day and aspirin 100mg once a day for 4 weeks. After 27 days, the damaged skin and the toe nail had sloughed off, and new nail had begun to emerge.

Although all skin lesions were treated after about 40 days, initial pain persisted and additional numbness and cold sense on the soles of the feet began and then progressively worsened. Although both feet experienced symptoms, symptoms in the left foot were more severe.

Skin lesions were not observed on either foot at the time of our hospital visit. Sensory symptoms were continued and unaffected by postural change. The patient did not complain of motor weakness, change in color of the feet, and changes in perspiration below the ankles. The patient was an office worker, generally healthy, and did not have a notable medical history, such as a diagnosis of diabetes or hyperlipidemia. Although he received a prescribed analgesic for the frostbite, he had no history of drinking and his physical examination was normal.

Results of neurological examination, a cranial nerve examination including pupillary light reflex testing, and muscle strength testing in both arms and legs were normal. On sensory examination, vibration, proprioceptive, positional, touch, temperature, pain and



pressure senses below both ankles were normal, although subjective paresthesia were sustained below both ankles regardless of the dermatome; particularly abnormal findings were on the tips and left side of the feet where injury was more severe. Sensory examinations of both hands and arms were normal, and the patient did not complain of autonomic nervous system-related symptoms, such as voiding dysfunction, constipation, or dyhidrosis. Deep tendon reflex, gait and cerebellar function tests, such as tandem gait and Romberg test, were normal.

Complete blood count, liver function test and renal function test were normal, thyroid hormone, HbA1c, fasting glucose, autoimmune antibody, antinuclear antibody, human immunodeficiency virus, and urine tests were also normal. Since severe frostbite-induced neuropathy was suspected, a Nerve Conduction Study (NCS) and Electromyography (EMG) were performed. NCS and EMG findings, including those from the medial and lateral plantar nerves, were normal, and ultrasonography results of both feet were normal. Symptoms persisted despite administration of 400 mg gabapentin and 10 mg amitriptyline, as well as concurrent administration of non-steroidal anti-inflammatory drugs and Tramadol hydrochloride for one month. A Sympathetic Skin Response (SSR) and Quantitative Sudomotor Axon Reflex Test (QSART) were performed in order to identify SFN. A normal triphasic waveform was found in both hands on SSR testing (Figure A), but the waveform was not observed in both feet (Figure B). QSART results were normal for the left forearm (Figure C), proximal leg (Figure D), and distal leg (Figure E); however, latency was prolonged and sweat volume was substantially decreased in the extensor digitorum muscle (Figure F) (Table 1). Frostbite-induced SFN could be suspected based on the combined results of the patient’s clinical symptoms, NCS and EMG findings, and decreased responses of foot on SSR and QSART testing. The patient who was on observation status for three months

Table 1: Quantitative Sudomotor Axon Reflex Test (QSART).

Site	Latency (second)	Volume ($\mu\ell$)
Left forearm	181	1.87
Left proximal leg	239	1.41
Left distal leg	126	2.19
Left foot	306	0.07

Quantitative sudomotor axon reflex test result that detected over the four skin region.

with administration of gabapentin, amitriptyline, non-steroidal anti-inflammatory drugs and Tramadol hydrochloride was not observed noticeable symptomatic improvements.

Discussion

Frostbite is freezing of the tissue due to heat loss that is sufficient to cause formation of ice crystals on the surface or underlying tissue, and its severity is affected by environmental temperature, direction of wind, and exposure time [2]. Although more than 90% of frostbite cases develop in the hands and feet, it also develops on the face (nose, chin, earlobe, cheek, and lips), buttocks, and perineum. Cold-induced injury such as frostbite lead to thermoregulatory response, cellular and tissue effects (e.g., membrane damage, electrolytic imbalance, endothelial injury and thrombosis) and systemic effects (e.g., shock, arrhythmia and neuromuscular dysfunction) [3]. Frostbite can be classified by the degree of severity. A first degree injury includes inflammation, hemorrhage, erythema, hyperemia, and mild edema of the injured area but no blisters or necrosis; a second degree injury indicates the presence of superficial blisters in addition to the symptoms of a first degree injury; a third degree injury includes cutaneous or subcutaneous necrosis as well as blue-grey discoloration; and a fourth degree injury indicates severe skin necrosis of injured fingers or toes requiring amputation, and freezing extending through subcutaneous tissue into muscle, tendon, and bone [4]. This patient’s

case appeared to be a second or third degree tissue injury, as blisters and discoloration of the tips of the toes were manifested in both feet. CI-induced peripheral neuropathy can present motor paralysis and sensory loss depending on the degree of injury, complete loss of motor and sensory functions occurs at 0–5°C, and motor nerves are more readily injured than sensory nerves. Therefore, motor function is more severely impacted than sensory function, which is generally recovered sooner [5]. In addition, denervation findings, such as fibrillation and positive sharp waves, are observed in the distal part of the injured nerve, because axonal injury and Wallerian degeneration of the injured axon develop, resulting in segmental demyelination surrounding the axon [5]. Previous reports of CI also described electrophysiological results that reflected axonal sensory motor polyneuropathy, and SSR and Quantitative Sensory Testing were normal despite abnormal sensation, muscle weakness, and reduced reflex responses in the injured area [6,7]. However, this patient developed neurological symptoms after frostbite, and NCS as well as EMG results were normal despite sufficient time passing after the injury. SFN was suspected based on persistent and severe pain, numbness, tingling and cold sense in feet and abnormal SSR and QSART findings, despite of normal sensory examination with normal NCS and EMG. SFN is caused by injury of a thin myelinated fiber, A δ or unmyelinated C fiber, and there is no need for additional testing if there is a strong medical history and confirmation of appropriate clinical testing to suggest SFN [8]. The tests that help confirm a diagnosis of SFN include SSR, QSART, Quantitative Sensory Testing, and skin biopsy [8].

In this patient, sensory symptoms in the feet were developed after frostbite event, and SSR test verified a lack of normal biphasic waveforms in the feet compared to the hands. In addition, a noticeable prolonged latency and decreased secretion of the sweat glands on the left foot were found by QSART, and, thus, frostbite-induced SFN could be suspected. The causes of SFN include diabetes, impaired glucose handling, systemic amyloidosis, Sjogren's syndrome, drug,

alcohol, or toxic substance abuse, HIV, hyperlipidemia, familial "burning feet" syndrome, Tangier disease, hereditary amyloidosis, Fabry disease, hereditary sensory neuropathy, and monoclonal gammopathy, [9,10] but this patient wasn't considered to have associated with these causes.

Conclusion

We report a case of frostbite-induced SFN in a patient without specific underlying diseases, and it is worth considering the possibility that frostbite or NFCI can induce SFN.

References

1. Irwin MS, Sanders R, Green CJ, Terenghi G. Neuropathy in non-freezing cold injury (trench foot). *J R Soc Med.* 1997; 90: 433-438.
2. Grieve AW, Davis P, Dhillon S, Richards P, Hillebrandt D, Imray CH. A clinical review of the management of frostbite. *J R Army Med Corps.* 2011; 157: 73-78.
3. Biem J, Koehncke N, Classen D, Dosman J. Out of the cold: management of hypothermia and frostbite. *CMAJ.* 2003; 168: 305-311.
4. Millet JD, Brown RK, Levi B, Kraft CT, Jacobson JA, Gross MD, et al. Frostbite: Spectrum of Imaging Findings and Guidelines for Management. *Radiographics.* 2016: 160045.
5. Kang Y, Hwang S, Lee W. A case of Cryosurgery-induced median nerve neuropathy. *J Korean Neurol Assoc.* 1998; 16: 899-901.
6. Collier T, Patel A, Rinaldi R. Hypothermia-induced peripheral polyneuropathy after an episode of drowning. *PM R.* 2012; 4: 230-233.
7. Loseth S, Bagenholm A, Torbergsen T, Stalberg E. Peripheral neuropathy caused by severe hypothermia. *Clin Neurophysiol.* 2013; 124: 1019-1024.
8. Hovaguimian A, Gibbons CH. Diagnosis and treatment of pain in small-fiber neuropathy. *Curr Pain Headache Rep.* 2011; 15: 193-200.
9. Lacomis D. Small-fiber neuropathy. *Muscle Nerve.* 2002; 26: 173-188.
10. Farhad K, Traub R, Ruzhansky KM, Brannagan TH. Causes of neuropathy in patients referred as "idiopathic neuropathy". *Muscle Nerve.* 2016; 53: 856-861.