

## Case Report

# Focal Seizure as the Initial Presentation of Cryptococcal Meningitis-Immune Reconstitution Inflammatory Syndrome in Human Immunodeficiency Virus Patients

Yi-Hui Lin<sup>1,3</sup>, Pei-Lin Ho<sup>1,3</sup>, Meng-Ni Wu<sup>1,3</sup>, Lung-Chang Lin<sup>4,5</sup>, Chung-Yao Hsu<sup>1,3</sup>, Chiou-Lian Lai<sup>1,2,3</sup> and Li-Min Liou<sup>1,3\*</sup>

<sup>1</sup>Department of Neurology, Kaohsiung Medical University Hospital, Kaohsiung Medical University, Kaohsiung, Taiwan

<sup>2</sup>Department of Neurology, Kaohsiung Municipal Hsiao-Kang Hospital, Kaohsiung Medical University, Kaohsiung, Taiwan

<sup>3</sup>Department of Neurology, School of Medicine, College of Medicine, Kaohsiung Medical University, Kaohsiung, Taiwan

<sup>4</sup>Department of Pediatrics, School of Medicine, College of Medicine, Kaohsiung Medical University, Kaohsiung, Taiwan

<sup>5</sup>Department of Pediatrics, Kaohsiung Medical University Hospital, Kaohsiung Medical University, Kaohsiung, Taiwan

\*Corresponding author: Li-Min Liou, Department of Neurology, Kaohsiung Medical University Hospital, School of Medicine, College of Medicine, Kaohsiung, Taiwan

Received: February 09, 2018; Accepted: March 12, 2018; Published: March 30, 2018

## Abstract

**Background:** Central Nervous System Immune Reconstitution Inflammatory Syndrome (CNS-IRIS) occurs most commonly in the setting of Human Immunodeficiency Virus (HIV) immunosuppression. Cryptococcus meningitis (CM) - IRIS, which is the most common IRIS, develops in 8-45% of HIV-infected patients with cryptococcosis who responded to Highly Active Antiretroviral Therapy (HARRT) and antifungal therapy. The general symptoms of CM-IRIS, are nonspecific, such as headache, fever, malaise, and altered consciousness. The mortality of CM-IRIS ranges from 5% to 30%. Focal seizures have never been reported as the initial presentation of CM-IRIS.

**Case Summary:** We report two rare cases of CM-IRIS in HIV patients who initially presented with focal seizures. Both lumbar punctures revealed lymphocytic reaction and decreased titers of cryptococcus Ag. In case 1 patient, the focal seizure may be associated with contra lateral cranial MR abnormalities. The seizures occurred (in case 1 and 2) and recurred (in case 1) after a rapidly increased CD4/CD8 ratio (but not absolute CD4 counts in the literature review) and decreased T-cell % and were well controlled by levetiracetam (500mg 1# BID). The MR abnormalities of CM-IRIS resolved after prednisolone 40mg per day two months later (in case 1).

**Conclusion:** The recognition of new clinical symptoms that occur despite initial successful therapy in HIV patients, along with improved laboratory data and distinct neuro imaging abnormalities, is crucial to the diagnosis and treatment of CNS-IRIS. Our two cases demonstrated that focal seizures (contra lateral to cranial lesioned site) can be the initial presentation of CM-IRIS in HIV patients, which is important because of its nonspecific features of CM-IRIS.

**Keywords:** Cryptococcal meningitis; Immune reconstitution inflammatory syndrome; Human immunodeficiency virus; Seizures

## Introduction

Immune Reconstitution Inflammatory Syndrome (IRIS) occurs in the setting of rapid recovery of immunity, mostly among HIV patients receiving Highly Active Antiretroviral Therapy (HARRT) and among non-HIV patients experiencing corticosteroid withdrawal or recovery of neutropenia after cytotoxic chemotherapy [1]. Cryptococcus Meningitis (CM) - IRIS, which is the most common IRIS, develops in 8-45% of HIV-infected patients with cryptococcosis who responded to cART and antifungal therapy [2] and a considerably high mortality of 5%-30% [3]. CM-IRIS most frequently presents as recurrent meningitis; however, it may manifest as intracranial space-occupying lesions and non-central nervous system presentations (e.g: lymphadenitis, pneumonitis, and ophthalmologic complications) [2].

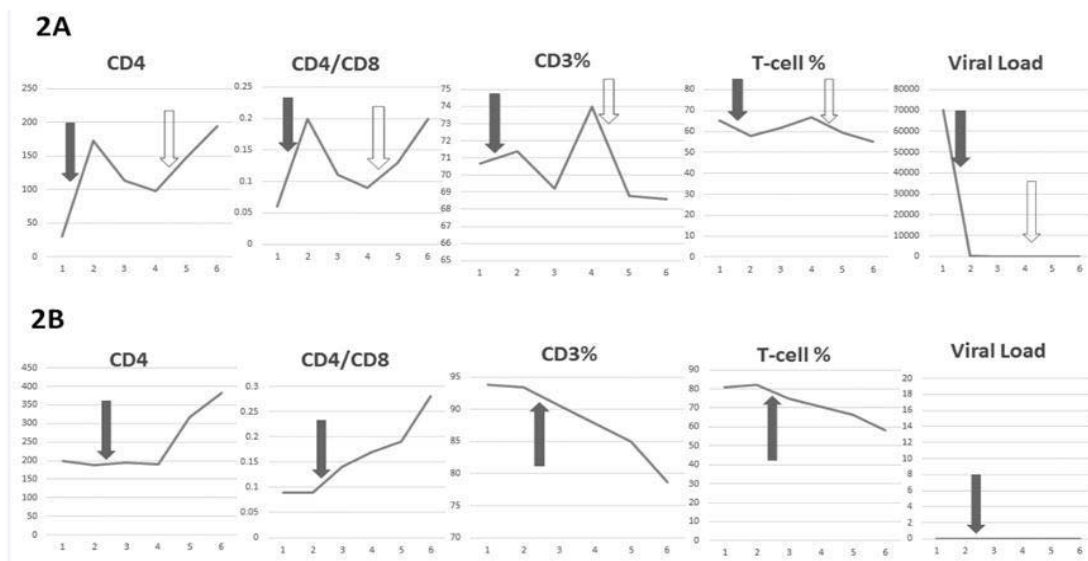
The early recognition of CM-IRIS is essential for decreasing the morbidity and mortality. However, the general symptoms of CM-IRIS are nonspecific, such as headache, fever, malaise, cranial nerve palsy, and altered consciousness [4]. It is essential that we should pay attention if any paradoxical events occur after either previously diagnosed or treated or subclinical infections. Focal seizure was rarely

reported as the initial presentation of CM-IRIS. Herein, we report two rare cases of CM-IRIS that initially presented as focal seizures.

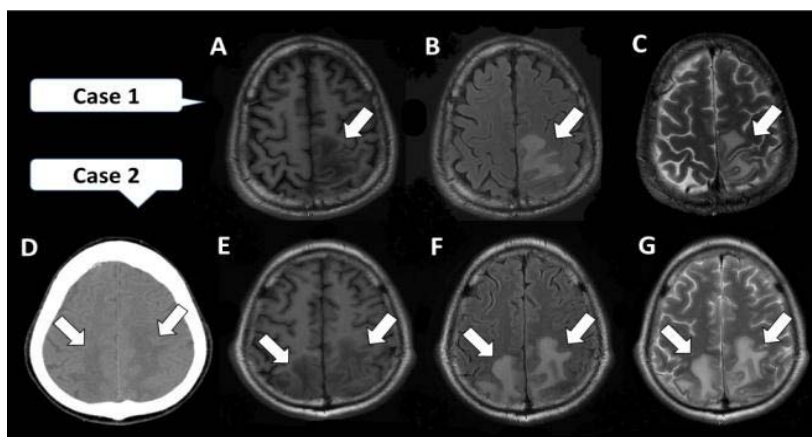
## Case Presentation

### Case 1

A 44-year-old man had a past history of CM, which had been treated with fluconazole (50mg 8# QD) since July 16, 2014, and HIV, which had been treated with HARRT since August 7, 2014. He experienced intermittent right lower leg convulsions and Todd's paralysis from September 21 to 24, 2014. Brain Computed Topography (CT) and Magnetic Resonance Imaging (MRI) reported subcortical white matter lesions with enhancement of the left parietal sulci. No obvious mass effect was found (Figure A,B,C). The Cerebrospinal Fluid (CSF) profile revealed an opening pressure of 18cmH<sub>2</sub>O, cell counts of 2 (monocyte), protein level of 42mg/dl, and sugar level of 51mg/dl. India ink stains and cultures of the CSF sample were negative. Cryptococcus antigen was positive but decreased compared to the past (1:16 to 1:4). Brain biopsy reported marked fibrosis without malignant cells. The diagnosis of Immune Reconstitution Inflammatory Syndrome (IRIS) was made. We added



**Figure 1:** This study revealed high signal intensity on T2W, FLAIR images and low signal intensity on T1W involving subcortical and deep white matter of bilateral parietal lobes. Meningeal thickening with enhancement of the parietal sulci (arrows).



**Figure 2:** Relationships between occurrence of seizures (arrows indicate the occurrence of seizures: first seizure; second seizure; case 1: A (T1), B (T2 flair), C (T2); case 2: D (CT), E (T1), F (T2 flair), G (T2) and sequential changes in the CD4 counts, CD4/CD8 ratio, CD 3%, T-cell% and HIV viral load.

on prednisolone 8# QD and kept the same anti-HIV and anti-fungal regimen. The cranial MR abnormalities disappeared two months later. He did not regular take the medicine thereafter and another similar seizure episode occurred on May 12, 2015. Cranial MR imaging reported similar but smaller lesion as those on September, 2014. The occurrence of seizures (denoted by arrows) and sequential changes in the CD4 counts, CD4/CD8 ratio, CD3%, T-cell% and HIV viral load are shown in (Figure 2A). The first and second seizure clusters were well controlled with levetiracetam (500mg 1# BID).

**Case 2**

A 29-year-old man had a past history of CM, which had been treated with Diflucan (50mg 8# QD) since November 8, 2014, and HIV, which had been treated with HARRT since December 9, 2014. He exhibited left lower leg numbness paresthesia, followed by generalized tonic-clonic seizures lasting for 5min on October 5, 2015. Brain MR imaging reported subcortical white matter lesions with enhancement of the bilateral parietal sulci. No obvious mass

effect was found (Figure D,E,F). The CSF profile revealed an opening pressure of 16cm H<sub>2</sub>O, cell counts of 63 (lymphocyte-predominant leukocytosis), protein level of 27mg/dl and sugar level of 54mg/dl. Cryptococcus antigen was decreased compared the past (1:1024 to negative). India ink stains and cultures of the CSF sample were negative. The diagnosis of Immune Reconstitution Inflammatory Syndrome (IRIS) was made. We added on prednisolone 8# QD and kept the same anti-HIV and anti-fungal regimen. The occurrence of seizures (denoted by arrows) and sequential changes in the CD4 counts, CD4/CD8 ratio, CD3%, T-cell% and HIV viral load are shown in (Figure 2B). The seizures were controlled with levetiracetam (500mg 1# BID).

**Discussion**

We report two rare cases of CM-IRIS in HIV patients who initially presented with focal seizures either with or without secondary generalization. Focal seizure was rarely reported as the initial presentation of CM-IRIS.

Although no formal diagnostic criteria for central nervous system-IRIS are available, diagnoses are generally based on the worsening of a recognized or unrecognized preexisting infection despite improving immunologic function; the detection of distinct neuro imaging abnormalities, including contrast enhancement, interstitial edema, mass effect, and restricted diffusion infections [3]; and the presence of most or all of the following features [5]: (1) HIV infection, with an initially low pretreatment CD4 count (often <100 cells/ $\mu$ L); (2) a positive virological and immunological response to antiretroviral therapy; and (3) no evidence of IRIS-mimicking conditions.

Lymphocytic activation in the CSF is characteristic of CM-IRIS. Compared CM, CM-IRIS was associated with an increasing proportion of activated CD4+ T cells, migration of intermediate monocytes to the CSF, and declining fungal burden. Neither CSF cell counts, protein values nor CD8+ T cell counts can differentiate these two conditions [5]. Our two cases fit the criteria. According to our limited experience of the occurrence of seizures and sequential changes in the CD4 counts, CD4/CD8 ratio, CD3%, T-cell% and HIV viral load (Figure 2) in our two cases, rapidly increased CD4/CD8 ratios (but not absolute CD4 counts because no CD4 count increases in case 2) and decreased T-cell% are most strongly related to the occurrence of CM-IRIS and seizures.

Seizures, which account around 8%, are not common in CM patients. And most of them (75%) are generalized seizures [6]. Case 1 demonstrated the focal seizures occurred and recurred along with concurrent contra-lateral cranial MRI lesions, while lumbar puncture profile reported lymphocytic reaction and decreased titers of cryptococcus Ag in CSF. The focal seizures are more associated with CM-IRIS than CM itself.

Approximately 6.1% of the HIV population has either symptomatic seizures or epilepsy [7]. Potentially complex and extensive interactions between HAART drugs and Antiepileptic Drugs (AEDs) are related to the P450 system enzyme induction effects of several older-generation AEDs (such as phenytoin and carbamazepine), which metabolize some HARRT drugs and may lead to virological failure. Conversely, the use of HARRT drugs that reduce AED levels could lead to the loss of seizure control [7]. Because of its minimal drug interactions, Siddiqi et al. suggested levetiracetam

as the first-line AED for HIV patients receiving HARRT [7]. When newer AEDs are not available, valproic acid may be the treatment of choice, because it does not cause enzyme-induction-associated HAART failure [7]. In our two cases, successful seizure control was achieved with levetiracetam (500mg BID).

## Conclusion

The recognition of new clinical symptoms that occur despite initial successful therapy in HIV patients, along with improved laboratory data and the recognition of distinct neuro imaging abnormalities are crucial to accurate diagnosis of CM-IRIS. Focal seizures can be the initial presentation of CM-IRIS in HIV patients. Levetiracetam can be used as a rational and individualized AED therapy for CM-IRIS-related seizures.

## References

1. Singh N, Lortholary O, Alexander BD, Gupta KL, John GT, Pursell K, et al. An immune reconstitution syndrome-like illness associated with *Cryptococcus neoformans* infection in organ transplant recipients. *Clin Infect Dis*. 2005; 40: 1756-1761.
2. Haddow LJ, Colebunders R, Meintjes G, Lawn SD, Elliott JH, Manabe YC, et al. Cryptococcal immune reconstitution inflammatory syndrome in HIV-1-infected individuals: proposed clinical case definitions. *Lancet Infect Dis*. 2010; 10: 791-802.
3. Post MJ, Thurnher MM, Clifford DB, Nath A, Gonzalez RG, Gupta RK, et al. CNS-immune reconstitution inflammatory syndrome in the setting of HIV infection, part 1: overview and discussion of progressive multifocal leukoencephalopathy-immune reconstitution inflammatory syndrome and cryptococcal-immune reconstitution inflammatory syndrome. *AJNR Am J Neuroradiol*. 2013; 34: 1297-1307.
4. Bicanic T, Harrison TS. Cryptococcal meningitis. *Br Med Bull*. 2004; 72: 99-118.
5. Meya DB, Okurut S, Zziwa G, Rolfes MA, Kelsey M, Cose S, et al. Cellular immune activation in cerebrospinal fluid from ugandans with cryptococcal meningitis and immune reconstitution inflammatory syndrome. *J Infect Dis*. 2015; 211: 1597-1606.
6. Tiamkao S, Sawanyawisuth K, Chotmongkol V. Seizure in non-HIV cryptococcal meningitis. *J Med Assoc Thai*. 2007; 90: 1298-1302.
7. Siddiqi O, Birbeck GL. Safe Treatment of Seizures in the Setting of HIV/AIDS. *Curr Treat Options Neurol*. 2013; 15: 529-543.