

Case Report

Hemocytopenia as Initial Manifestation of Chronic Myeloid Leukemia in Chronic Phase

Wu R¹, Sun YH² and Huang Y^{3*}

¹Department of Hematology, Zhangzhou Affiliated Hospital of Fujian Medical University, China

²Department of Pathology, Maimonides Medical Center, USA

³Division of Hematology/Oncology, Maimonides Medical Center, USA

*Corresponding author: Yiwu Huang, Division of Hematology/Oncology, Maimonides Cancer Center, 6300 8th Avenue, Brooklyn, New York 11220, USA

Received: June 03, 2018; Accepted: June 28, 2018;

Published: July 05, 2018

Abstract

The presence of (9;22) (q34;q11) reciprocal translocation, which is cytogenetically visible as Philadelphia chromosome (Ph), is a hallmark of Chronic Myeloid Leukemia (CML). The fusion BCR-ABL1 gene thus formed leads to constitutive expression of the BCR-ABL1 tyrosine kinase resulting in the manifestation of CML including hepatosplenomegaly and elevated white blood cell count on a routine laboratory test. We described a rare case which presented with severe neutropenia and anemia, while the cytogenetic analysis revealed an abnormal karyotype 46, XX, der(9)del(9)(q13q22)t(9;22)(q34;q11.2), der(22)t(9;22) [11]/46, XX [10]. FISH and quantitative PCR for BCR/ABL both showed that she had BCR/ABL fusion gene at Major breakpoint, which confirmed her diagnosis of CML, chronic phase. We hypothesize the hemocytopenia may relate to the deletion of 9(q13q22). After treated with dasatinib, she achieved molecular remission. She remains molecular remission 5 years later. To the best of our knowledge, there were not any previous published reports of similar cases.

Keywords: Chronic myeloid leukemia; Hemocytopenia; Cytogenetics

Introduction

Chronic Myeloid Leukemia (CML) accounts for approximately 15% of all adult leukemias [1]. In the United States, approximately 9000 new cases will be diagnosed in 2018 [2]. CML is a clonal myeloproliferative disorder associated with a specific chromosomal translocation of chromosome 9 and 22 resulting in the Philadelphia (Ph) chromosome. The abnormal chromosome harbors a BCR-ABL1 chimeric gene, which is the driver oncogene for CML and is essential for CML development. The fusion BCR-ABL1 protein tyrosine kinase constitutively activates in the hematopoietic stem cells, disrupts the signal transduction machinery of the host cells and promotes proliferation and antiapoptotic signals, leading to the malignant transformation of CML [3,4]. More than 85% of patients with CML are in the Chronic Phase (CP) at the time of diagnosis, but if left untreated, the disease will progress into the accelerated and blastic phases [3,5]. Many of the chronic phase cases may be diagnosed incidentally with an elevated white blood cell count on a routine laboratory test, usually exceeding $25 \times 10^9/L$ and frequently exceeding $100 \times 10^9/L$, occasionally with cyclic variations [3,5]. Patients are usually asymptomatic or have only mild symptoms of fatigue, weight loss, night sweats or abdominal fullness due to hepatosplenomegaly [5]. The classical teaching is that the finding of unexplained, persistent leukocytosis (e.g. $>12-15 \times 10^9/L$) in the absence of infections or other causes of WBC count elevation should prompt a workup for CML [5]. Here we described a rare case which presented with severe neutropenia and anemia, workup revealed CML-CP. After treated with dasatinib, the hemocytopenia resolved.

Case Presentation

A 41-year-old Asian female with excellent performance status and no significant past medical history, presented with severe anemia

and neutropenia for about one month with not any other symptoms in January 2013. Physical examination revealed no evidence of lymphadenopathy or hepatosplenomegaly. Her labs in February, 2013 showed WBC of $1.9 \times 10^9/L$ with a differential consisting of 40% neutrophils, 4% monocytes, 1% basophils and 55% lymphocytes, hemoglobin of 76.0g/L, hematocrit 22.6%, and platelet count $223 \times 10^9/L$. Reticulocyte count was 0.9%, MCV was 97.1fl (normal reference range 80-100fl). Complete metabolic panel showed normal kidney function and liver function. ANA, anti-Smith antibody and anti-double stranded DNA antibody were negative. Serum iron was 19 μ g/dL (33-170 μ g/dL), transferrin 167mg/dL (204-360mg/dL), TIBC 236 μ g/dL (230-450 μ g/dL), ferritin 366 μ g/L (18-160 μ g/L). Vitamin B₁₂ 275pg/mL (180-885pg/mL), folate 13.8ng/mL (2.3-24.8ng/mL). LDH was normal at 195IU/L (87-201IU/L). Peripheral blood smear showed normocytic and normochromic RBCs. There were no schistocytes, no ovalocytes. White cells showed decrease in the neutrophils but no immature cells seen. Platelet count was adequate. Chest x-ray was negative. Sonogram showed no splenomegaly. Bone marrow aspiration and biopsy was done in February, 2013. Flow cytometric analysis of bone marrow aspiration was unremarkable with no increased blasts or other abnormal cells. Bone marrow smear and biopsy showed hypocellular trilineage hematopoiesis with no increase in blasts and rare mononuclear megakaryocytes, no evidence of reticulin fibrosis (Figure 1(A-E)). Cytogenetic analysis revealed an abnormal karyotype 46, XX, der(9)del(9)(q13q22)t(9;22)(q34;q11.2), der(22)t(9;22) [11]/46, XX [10] (Figure 2). Quantitative RT-PCR analysis from bone marrow aspiration showed positive for BCR-ABL translocation with Major breakpoint 0.326% and Fluorescent in Situ Hybridization (FISH) showed positive for a BCR/ABL rearrangement (7.2% of cells), which confirmed her diagnosis of CML, chronic phase.

The patient was initially treated with dasatinib (Sprycel) at

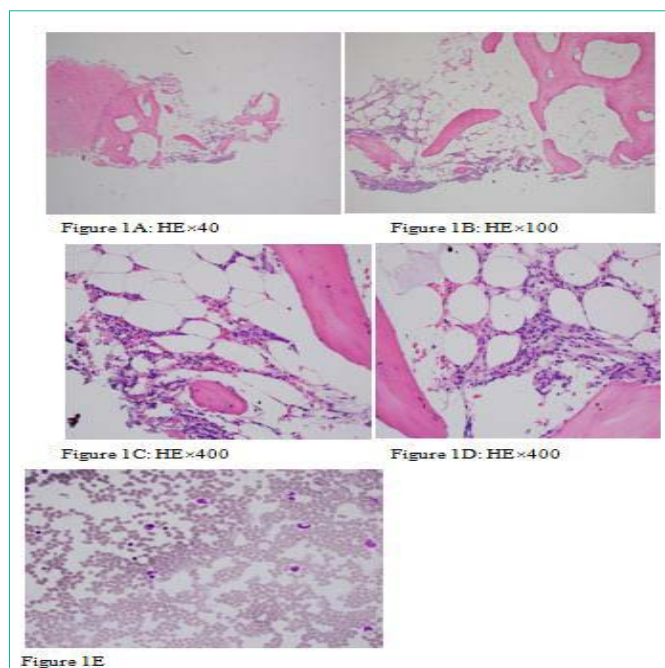


Figure 1E

Figure 1: 1A HE \times 40, 1B HE \times 100, 1C and 1D HE \times 400, 1E bone marrow smear \times 400. The marrow was hypocellular for the age group, trilineage hematopoiesis with rare mononuclear megakaryocytes. No increase in blasts and no evidence of reticulin fibrosis.

The bone marrow biopsy and smear showed hypocellular trilineage hematopoiesis with no increase in blasts and rare mononuclear megakaryocytes. Normal reticulin content was observed.

100mg daily in February 21, 2013. Before treatment, CBC showed WBC $1.5 \times 10^9/L$, hemoglobin of 65g/L, absolute neutrophil count of $0.7 \times 10^9/L$ and platelet count of $165 \times 10^9/L$. She developed severe thrombocytopenia and worsening anemia on March 15, 2013, when CBC showed WBC of $2.68 \times 10^9/L$, hemoglobin of 75g/L and platelets of $25 \times 10^9/L$. Dasatinib was hold for 17 days. She received packed RBC transfusion for symptomatic anemia. After thrombocytopenia recovered, dasatinib was restarted at lower dose of 80mg daily. She tolerated it very well. Three months after started dasatinib therapy, her peripheral blood and bone marrow biopsy revealed complete hematological response, undetected BCR/ABL by FISH and PCR, and normal karyotype (46, XX), suggested complete molecular remission. She has remained molecular remission since then. Her last visit on March, 2018 showed WBC of $4.7 \times 10^9/L$, hemoglobin of 120g/L and platelet count $130 \times 10^9/L$. Quantitative BCR-ABL PCR was still undetectable.

Discussion

This case represents an unusual initial presentation of hemocytopenia in CML of chronic phase. Untreated CML patients generally showed hypercellular marrows with increased M:E ratio, increased blasts and megakaryocytes with clustering and fibrosis [6-7]. This patient's initial bone marrow biopsy revealed hypocellular hematopoiesis. Since cytogenetics revealed Philadelphia chromosome, FISH and quantitative PCR for BCR/ABL both confirmed that she had BCR/ABL fusion gene at Major breakpoint, blasts fewer than 10% in the blood and bone marrow, the diagnosis of CML (Chronic Phase) could be established according to the 2016 revision to the World

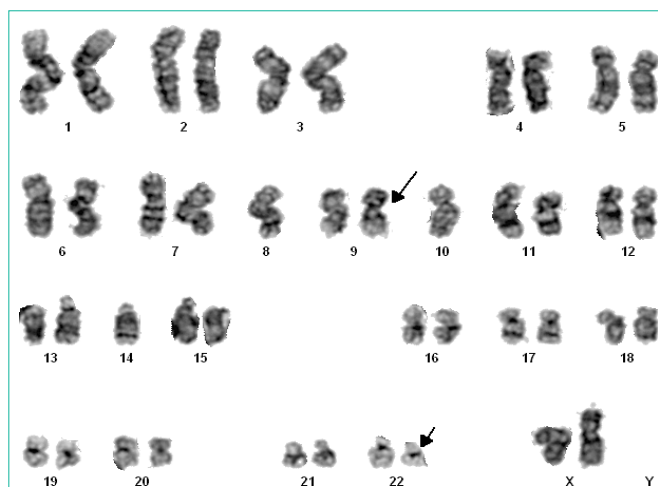


Figure 2: Chromosome analysis revealed an abnormal female karyotype with a Philadelphia (Ph) chromosome, resulting from a translocation between the long arms of chromosomes 9 and 22 and a derivative chromosome 9 resulting from a deletion of the long arm and the translocation between chromosomes 9 and 22.

Health Organization classification of myeloid neoplasms and acute leukemia [8]. Cytogenetic analysis showed evidence of interstitial deletion in the long arm of chromosome 9 with loss of the segment q13-q22 in 11 out of 21 metaphases examined.

The derivative chromosome 9 [der(9)] deletions are uncommon recurrent karyotypic abnormalities occurred in about 9-15% of the CML [9-14]. The der(9) deletions are variable in size, generally between 0.5Mb and 8Mb. They usually span the translocation breakpoint, including both chromosome 9 and chromosome 22 sequences; more than 300 genes are involved [13,15]. A study in which 144 patients with pretreated CML were enrolled showed that there was no significant difference of WBC, hemoglobin and platelet count between patients with and without der(9) deletion (16). Earlier studies [9,16] had suggested it is a poor prognostic indicator for CML patients before TKI era, who were treated with hydroxyurea, interferon alpha or bone marrow stem cell transplantation [9,10,13,16]. These patients tended to progress more rapidly to the advanced phase and had a shorter overall survival when treated with hydroxyurea or interferon-alpha. The potential poor prognostic impact of deletions of derivative chromosome 9 may be because of the loss of 1 or more tumor suppressor genes mapping to the derivative chromosome 9(16). However, the prognostic impact of der(9) deletions in TKI era has been controversy [11,12,14,17-19]. More recent reports suggested that der(9) deletions do not correlate with clinical features, laboratory findings including CBC, Sokal and Hasford scoring systems, or disease phase [11-13,18]. Quintas-Cardama A. et al [16] has studied 353 patients with CML in chronic phase, 11% patients carried der(9) deletions in 245 patients tested. All patients were treated with dasatinib or nilotinib. Their results showed that after treatment with second generation TKIs, patients with der(9) deletions do not appear to have a worse outcome compared with their counterparts without deletions, suggests that TKIs like imatinib, nilotinib and dasatinib may overcome the poor prognostic impact imparted by this cytogenetic abnormality. The der(9) deletions do not appear to be independent adverse risk factors for treatment outcome in CML patients received first or second generation TKIs [12,16,20,21]. This patient was started

on dasatinib, and at 3-month follow-up, her peripheral blood and bone marrow biopsy revealed complete hematological response and molecular remission. Five years later, she remains in complete molecular response.

The pathogenesis of the hemocytopenia, particularly neutropenia and hypocellular bone marrow in our patient is not clear yet. We hypothesize that the deletion of 9(q13q22), which contains the region of 9(q13q21) and 9(q21q22), may lead to the loss of certain regulatory genes and cause dysfunction of pluripotent stem cells [21], which could result in abnormal hematopoiesis, including hemocytopenia. However, the exact mechanism of hemocytopenia in this case may be more complex and needs to be further explored.

Conclusion

Hemocytopenia is rare in CML-CP. The case we presented suggested that the possibility of chronic myeloid leukemia should be taken into account in patients with leukopenia. Promote bone marrow biopsy is critical to establish the diagnosis. It seems this patient responded to 2nd generation TKI dasatinib as well as other patients with chronic phase CML. The mechanism of hemocytopenia is still unclear and deserves further study.

References

- Lee SJ. Chronic myelogenous leukemia. *British J. Haematol.* 2000; 111:993-1009.
- Siegel RL, Miller KD, Jamal A. *Cancer statistics.* 2018; 68:7-30.
- Apperley JF. Chronic myeloid leukemia. *Lancet.* 2015; 385:1447-1459.
- Tabarestani S, Movafagh A. New Developments in Chronic Myeloid Leukemia: Implications for Therapy. *Iran J Cancer Prev.* 2016; 9:e3961.
- Cortes JE, Silver RT, Khoury HJ, Kantarjian HM. Chronic myeloid leukemia. 2016.
- Hasserjian RP, Boecklin F, Parker S, Chase A, Dhar S, Zaiac M, et al. STI571 (imatinibmesylate) reduces bone marrow cellularity and normalizes morphologic features irrespective of cytogenetic response. *Am J ClinPathol.* 2002; 117:360-367.
- Frater JL, Tallman MS, Variakojis D, Druker BJ, Resta D, Riley MB, et al. Chronic myeloid leukemia following therapy with imatinibmesylate (Gleevec). Bone marrow histopathology and correlation with genetic status. *Am J ClinPathol.* 2003; 119: 833-841.
- Arber DA, Orazi A, Hasserjian R, Thiele J, Borowitz MJ, Le Beau MM, et al. The 2016 revision to the World Health Organization classification of myeloid neoplasms and acute leukemia. *Blood.* 2016; 127:2391-405.
- Sinclair PB, Nacheva EP, Leversha M, Telford N, Chang J, Reid A, et al. Large deletions at the t(9;22) breakpoint are common and may identify a poor-prognosis subgroup of patients with chronic myeloid leukemia. *Blood.* 2000; 95:738-743.
- Quintas-Cardama A, Kantarjian H, Talpaz M, O'Brien S, Garcia-Manro G, Verstovsek S, et al. Imatinibmesylate therapy may overcome the poor prognostic significance of deletions of derivative chromosome 9 in patients with chronic myelogenous leukemia. *Blood.* 2005; 105:2281-2286.
- Patel BP, Trivedi PI, Brahmabhatt MM, Gajjar SB, Iyer RR, Nalal EN, et al. Detection of derivative 9 deletion by BCR-ABL fluorescence *in-situ* hybridization signal pattern to evaluate treatment response in CML patients. *Arch Oncol.* 2009; 17:13-18.
- Kim DH, Popradi G, Sriharsha L, Kamel-Reid S, Chang H, Messner HA, et al. No significance of derivative chromosome 9 deletion on the clearance kinetics of BCR/ABL fusion transcripts, cytogenetic or molecular response, loss of response, or treatment failure to imatinibmesylate therapy for chronic myeloid leukemia. *Cancer.* 2008; 113:772-781.
- Huntly BJ, Bench A, Green AR. Double jeopardy from a single translocation: deletions of the derivative chromosome 9 in chronic myeloid leukemia. *Blood.* 2003; 102:1160-1168.
- Huntly BJ, Guilhot F, Reid AG, Vassiliou G, Hennig E, Franke C, et al. Imatinib improves but may not fully reverse the poor prognosis of patients with CML with derivative chromosome 9 deletions. *Blood.* 2003; 102:2205-2212.
- Storlazzi C, Specchia G, Anelli L, Albano F, Psatore D, Zafaria A, et al. Break-point characterization of der(9) deletions in chronic myeloid leukemia patients. *Genes Chromosome & Cancer.* 2002; 35:271-276.
- Quintas-Cardama A, Kantarjian H, Shan J, Jabbour E, Abruzzo LV, Verstovsek S, et al. Prognostic impact of deletions of derivative chromosome 9 in patients with chronic myelogenous leukemia treated with nilotinib or dasatinib. *Cancer.* 2011; 117:5085-5093.
- Marzocchi G, Castagnetti F, Luatti S, Baldazzi C, Stacchini M, Gugliotta G, et al. Variant Philadelphia translocations: molecular-cytogenetic characterization and prognostic influence on frontline imatinib therapy, a GIMEMA Working Party on CML analysis. *Blood.* 2011; 117:6793-6800.
- Fabarius A, Leitner A, Hochhaus A, Muller MC, Hanfstein B, Haferlach C, et al. Impact of additional cytogenetic aberrations at diagnosis on prognosis of CML: long-term observation of 1151 patients from the randomized CML Study IV. *Blood.* 2011; 118:6760-6768.
- Huntly BJ, Reid AG, Bench AJ, Campbell LJ, Telford N, Shepherd P, et al. Deletions of the derivative chromosome 9 occur at the time of the Philadelphia translocation and provide a powerful and independent prognostic indicator in chronic myeloid leukemia. *Blood.* 2001; 98:1732-1738.
- Castagnetti F, Testoni N, Luatti S, Marzocchi G, Mancini M, Kerim S, et al. Deletions of the derivative chromosome 9 do not influence the response and the outcome of chronic myeloid leukemia in early chronic phase treated with imatinibmesylate: GIMEMA CML Working Party analysis. *J Clin Oncol.* 2010; 28:2748-2754.
- Huntly BJ, Bench A, Delabesse E, Reid AG, Li K, Scott MA, et al. Derivative chromosome 9 deletions in chronic myeloid leukemia: poor prognosis is not associated with loss of ABL-BCR expression, elevated BCR-ABL levels or karyotypic instability. *Blood.* 2002; 99:4547-4553.