

## Special Article - Myelogenous Leukemia

# Imatinib-Induced Interstitial Lung Disease: A Case Report

Al-Mashhadi AL<sup>1\*</sup>, Stentoft J<sup>2</sup> and Roug AS<sup>1</sup>

<sup>1</sup>Department of Haematology, Aalborg University Hospital, Aalborg and Department of Haematology, Aarhus University Hospital, Aarhus, Denmark

<sup>2</sup>Department of Haematology, Aarhus University Hospital, Denmark

\*Corresponding author: Ahmed Ludvigsen Al-Mashhadi, Department of Haematology, Aalborg University Hospital, Mølleparkvej 4, 9000 Aalborg, Denmark

Received: January 17, 2018; Accepted: June 05, 2018;

Published: June 12, 2018

## Abstract

For more than a decade, Tyrosine Kinase Inhibitors (TKI) has been standard of care in the treatment of *BCR-ABL* positive Chronic Myeloid Leukemia (CML). The treatment has revolutionized the approach to CML and a vast majority of patients can now have unaltered lifespan with lifelong treatment. Generally the treatment is well tolerated with high-grade toxicities being rare. In this case report, a 69-year-old male patient with newly diagnosed chronic phase CML had a rapid hematological and compelling molecular response to imatinib mesylate (imatinib), but developed severe progressive Interstitial Lung Disease (ILD) within the first 3 months of treatment. Drug discontinuation and combined immunosuppressive therapy, with corticosteroids and azathioprine, alleviated the pulmonary symptoms, chest radiographs improved significantly, and the patient achieved nearly complete pulmonary recovery. This case report serves to raise awareness of ILD as a rare but very serious complication of TKI treatment in CML, where early diagnosis and intervention is of utmost importance since the condition is potentially life threatening, if unrecognized.

**Keywords:** Chronic myeloid leukemia; Tyrosine kinase inhibitor; Interstitial lung disease

## Case Presentation

A 69-year-old male presented with significant leukocytosis and a 4-months history of weight loss and fatigue. There was no prior history of smoking, cardiac or pulmonary disease, nor any other significant comorbidity. Also, there was no history of toxic exposure in the workplace. At diagnosis the total leukocyte count was  $146 \times 10^9/L$ , hemoglobin 11.8g/dl, and platelets  $1159 \times 10^9/L$ . The spleen was not enlarged. Bone marrow examination showed chronic phase CML with 5% blasts and 12% basophils and cytogenetic analysis revealed 46, XY, t(9;22) (q34;q11) [25/25]. The Sokal [1] and ELTS [2] scores were 2.02 (high risk) and 1.84 (intermediate risk), respectively.

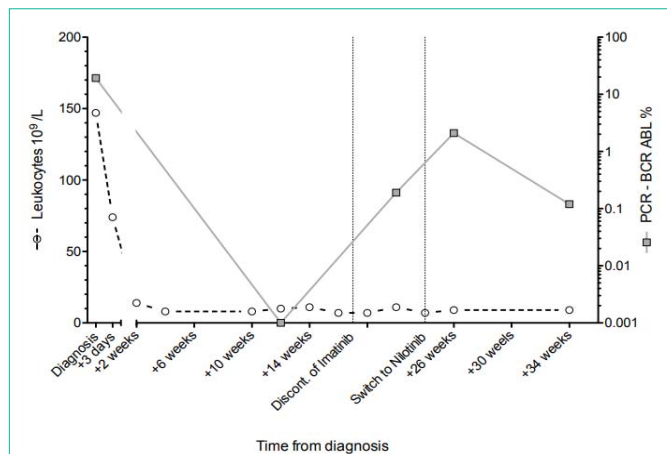
The patient was started on standard dose imatinib (400mg OD). Hematologic remission was achieved within 4 weeks, and after 12 weeks a compelling molecular response, as measured by qPCR, was accomplished (MR5 with *BCR-ABL* below 0.001% IS in peripheral blood) (Figure 1) [3]. Grade 1 periorbital edema was the only side effect experienced during the initial 9 weeks of treatment, after which there was an insidious and progressive dyspnea and non-purulent secretory cough, but no fever. Chest examination revealed end-expiratory crackles, and chest X-ray verified bilateral perihilar infiltrates. C-reactive protein was slightly elevated to 52 g/L (Figure 2b), but hypoxemia was not observed. Antibiotics were ineffective. Repeated chest radiograph showed progression of the perihilar infiltrates and regular Computed Tomography (CT) scan verified marked pathology with bilateral infiltration, ground-glass opacity and generalized bronchiectasis (Figure 3b-d). There were no signs of malignancy or lymph-node pathology in the thorax, abdomen or pelvic regions. The dyspnea had now become debilitating. High Resolution CT scan verified the standard CT findings resembling ILD (Figure 3e). Echocardiography was normal with no sign of pulmonary

hypertension. Lung function test shortly after corticosteroid treatment showed typical restrictive lung disease pattern consistent with interstitial disease (FEV1/FVC 100%, FVC 77% of expected, DLCO/VA 58% of expected). Transbronchial lung biopsy or bronchoalveolar lavage was not performed.

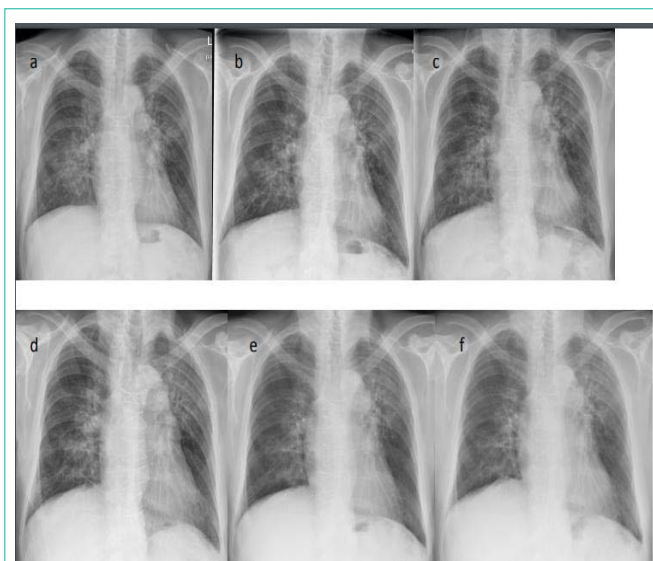
Imatinib-induced ILD (grade 2) was suspected, the culprit TKI was discontinued, and a 14-day course of prednisolone (75mg OD) was started, which was effective but inadequate. Hence, prednisolone was resumed (50mg OD) alongside azathioprine (150mg OD, 11 weeks) by which a slow but steady clinical and radiological improvement was attained (Figure 3 a-f). Due to rising levels of the *BCR-ABL* transcript, nilotinib was introduced (300mg BID) with good response (Figure 1). Five months after discontinuation of imatinib, the patient was still treated with prednisolone (12.5 mg/day) and nilotinib. The pulmonary symptoms had nearly recovered and chest radiographs almost normalized (Figure 3f).

## Discussion

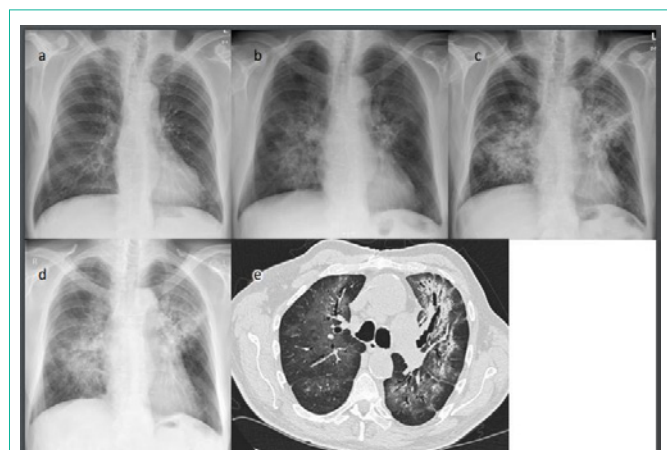The approval of imatinib in 2001 as the first molecularly targeted TKI not only led to breakthrough treatment of *BCR-ABL* positive CML [4], but also heralded a new era in the treatment of neoplastic disorders in general. Five TKIs are currently available for clinical use in CML. Overall, these drugs are well tolerated and highly effective, but treatment related complications do occur. The most prominent side effects of imatinib treatment are nausea, diarrhea, edema, muscle cramps, rash, fatigue, and bone marrow suppression. Among the most serious adverse effects of second generation TKIs, cardiovascular disease dominates [5]. Although rare, more than 50% of all approved TKIs have been reported to induce ILD including imatinib, dasatinib and nilotinib. It presents with varying severity and the reported mortality rates are in the range of 20-50% when untreated [6-8].



**Figure 1:** Progression of leukocyte count and qPCR levels of *BCR-ABL1* transcript in peripheral blood.



**Figure 3:** X-ray controls after discontinuation of Imatinib and introduction of immunosuppressive therapy after (a) 1 weeks; (b) 3 weeks; (c) 5 weeks; (d) 8 weeks; (e) 14 weeks; (f) 23 weeks.



**Figure 2:** Diagnostic imaging during treatment course illustrating progressive interstitial disease. (a) Pretreatment X-ray; X-ray after introduction of Imatinib for; (b) 9 weeks; (c) 13 weeks; (d and e) 16 weeks. (e) HRCT showing ground-glass opacity, bronchiectasis and fibrosis.

ILD can occur secondary to a broad range of systemic diseases, after many different exposures including as drug toxicity. Most frequently it presents with dyspnea, cough, fever, and hypoxemia due to chronic inflammation and/or skin damage resulting in progressive fibrosis. The diagnosis is supported by the case history, relevant exposure, and radiological findings, but lung biopsy may be necessary for accurate diagnosis. Extensive diagnostic work-up may also be needed with regard to primary disease.

The pathophysiology of TKI-induced ILD remains unclear, but is believed to be multifactorial. Generally pneumotoxic agents cause alveolitis and edema, which initiate various mechanisms to repair the lung tissue [9]. Acute injury may, on occasion, result in detrimental chronic inflammation and, eventually, fibrosis that compromises gas exchange. Some compounds and their metabolites have been shown to interact with HLA and act as potential antigens or haptens causing a drug-specific immuno-allergic response [10]. Recent data indicate TKIs may behave in a similar manner [11,12]. Speculatively, the cytolysis resulting from the compelling decrease in tumor burden in the case presented, could have resulted in a severe cytokine release,

a so-called “cytokine storm”, which may have contributed to an inflammatory response. The intensity and time course of the protective effect of the combination of corticosteroids and azathioprine, further add credence to the perception that immune mechanisms are indeed involved in TKI-induced ILD.

The susceptibility and likelihood of developing TKI-induced ILD remain obscure. Certain risk factors have been identified with both extremes of age, radiation therapy, underlying lung disease, and concomitant administration of pulmonary toxic agents being the most pronounced. In addition, ethnicity seems to play an important role. Specifically, the Japanese population has a significantly increased incidence of ILD as compared to other nationalities, which most likely may reflect a specific genetic susceptibility [7].

There is no general consensus in treating drug induced ILD. The use of corticosteroid-sparing systemic immunosuppression, in this case azathioprine, which particularly impedes B- and T lymphocyte proliferation [13], has only been sparsely reported in the treatment of TKI-induced ILD, but may be a viable and effective option as we have demonstrated. The expected tumor flare-up after discontinuation of imatinib necessitated re-challenge of TKI treatment with good response (Figure 1). Reportedly, for some patients, re-administration or continuation of the culprit TKI in a reduced dose under corticosteroid cover may be successful [6]. In CML however there are now a number of effective TKIs available and reintroduction of a culprit TKI should be restricted to cases where no alternatives remain, e.g. lack of response, unwanted drug interactions, or other potent side effects.

With this case report we hope to place emphasis on the importance of vigilant monitoring of early and late toxicity, concurrent morbidity, and drug interactions along with efficacy of treatment in CML patients. The diagnosis of TKI-induced ILD remains a diagnosis of exclusion and may be hampered by non-specific findings and idiosyncratic toxicities. Early treatment may reduce the high

mortality rates that have been reported. Therefore patients presenting with unexplained fever, cough, and dyspnea, even several months after starting TKI treatment, should be investigated and treated for ILD. Besides immediate discontinuation of the culprit TKI and initiation of high-dose corticosteroids, systemic corticosteroid-sparing immunosuppression should be considered.

## References

1. Sokal JE, Cox EB, Baccarani M, Tura S, Gomez GA, Robertson JE, et al. Prognostic discrimination in "good-risk" chronic granulocytic leukemia. *Blood*. American Society of Hematology; 1984; 63: 789-799.
2. Pffirmann M, Baccarani M, Saussele S, Guilhot J, Cervantes F, Ossenkoppele G, et al. Prognosis of long-term survival considering disease-specific death in patients with chronic myeloid leukemia. *Leukemia*. 2016; 30: 48-56.
3. Cross NCP, White HE, Iler MCMU, Saglio G, Hochhaus A. Standardized definitions of molecular response in chronic myeloid leukemia. *Nature Publishing Group*. 2012; 26: 2172-2175.
4. Baccarani M, Pileri S, Steegmann JL, Muller M, Soverini S, Dreyling M, et al. Chronic myeloid leukemia: ESMO Clinical Practice Guidelines for diagnosis, treatment and follow-up. *Annals of oncology: official journal of the European Society for Medical Oncology*. 2012; 23: vii72-77.
5. Larson RA. Is there a best TKI for chronic phase CML? *Blood*. American Society of Hematology. 2015; 126: 2370-2375.
6. Shah RR. Tyrosine Kinase Inhibitor-Induced Interstitial Lung Disease: Clinical Features, Diagnostic Challenges, and Therapeutic Dilemmas. *Drug Saf*. Springer International Publishing. 2016; 39: 1073-1091.
7. Ohnishi K, Sakai F, Kudoh S, Ohno R. Twenty-seven cases of drug-induced interstitial lung disease associated with imatinib mesylate. *Leukemia*. 2006; 20: 1162-1164.
8. Peerzada MM, Spiro TP, Daw HA. Pulmonary toxicities of tyrosine kinase inhibitors. *Clin Adv Hematol Oncol*. 2011; 9: 824-836.
9. Schwaiblmair M, Behr W, Haeckel T, Märkl B, Foerg W, Berghaus T. Drug induced interstitial lung disease. *Open Respir Med J*. 2012; 6: 63-74.
10. Illing PT, Vivian JP, Dudek NL, Kostenko L, Chen Z, Bharadwaj M, et al. Immune self-reactivity triggered by drug-modified HLA-peptide repertoire. *Nature*. 2012; 486: 554-558.
11. Nishimura M, Toyoda M, Takenaka K, Imamura Y, Chayahara N, Kiyota N, et al. The combination of HLA-B\*15:01 and DRB1\*15:01 is associated with gemcitabine plus erlotinib-induced interstitial lung disease in patients with advanced pancreatic cancer. *Cancer Chemother Pharmacol*. 2016; 77: 1165-1170.
12. Furukawa H, Oka S, Shimada K, Tsuchiya N, Tohma S. Genetics of Interstitial Lung Disease: Vol de Nuit (Night Flight). *Clin Med Insights Circ Respir Pulm Med*. 2014; 9: 1-7.
13. Cara CJ, Pena AS, Sans M, Rodrigo L, Guerrero-Esteso M, Hinojosa J, et al. Reviewing the mechanism of action of thiopurine drugs: towards a new paradigm in clinical practice. *Med Sci Monit*. 2004; 10: RA247-254.