

Editorial

Dominant Hereditary Essential Thrombocythemia Caused by Germline TPO Mutation Complicated by Secondary Myelofibrosis

Michiels JJ*

Goodheart Institute & Foundation in Nature Medicine & Health, Goodheart Institute, Netherlands

*Corresponding author: Michiels JJ, Goodheart Institute & Foundation in Nature Medicine & Health, Goodheart Institute, Freedom of Science and Education, Erasmus Tower, Veenmos 13, 3069 AT Rotterdam, Netherlands

Received: November 06, 2017; Accepted: November 15, 2017; Published: November 22, 2017

Editorial

Clinical presentation of Dutch TPO induced Hereditary Essential Thrombocythemia: HET

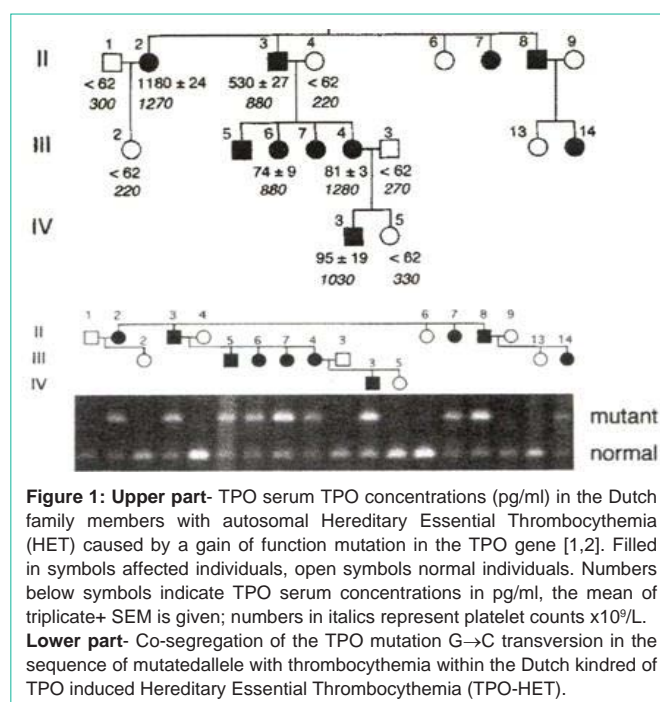
An activating mutation in the TPO gene caused dominant Hereditary Essential Thrombocythemia (HET) by the demonstration of the co-segregation of G to C transversion in the splice donor site of intron 3 in the TPO gene with the presence of HET in a large Dutch family [1,2]. All affected family members with HET showed increased TPO levels (Figure 1), pedigree [1,2]. The proband of the Dutch family with autosomal dominant HET case II 3 (man born in 1934) presented in 1986 with typical erythromelalgia complicated by acrocyanosis of a few toes followed by gangrene and amputation of one toe, which typically responded to low dose aspirin but not to coumadin similar as first described by Michiels *et al.* in patients with Essential Thrombocythemia (ET) and Polycythemia Vera (PV) in 1985 [3]. Dr. Van der Maas consulted me to evaluate whether the bone marrow histology of the proband (case II 3, (Figure 1)) was compatible with ET [3]. At time of diagnosis of familial HET the histopathology from bone marrow biopsy material from the proband in 1986 (Figure 2) and in 1991 (Figure 3) were very characteristic and diagnostic for ET meeting all features according to the Rotterdam Clinical and Pathological (RCP) [4] and the European Clinical and Pathological (ECP) [5]. Diagnostic criteria of ET were present: increase of platelet count in excess of $400 \times 10^9/l$ and clustered increase of large mature megakaryocytes in a normocellular prefibrotic bone marrow.

Molecular etiology and pathophysiology of congenital TPO induced HET

Based on 4 publications in 1994 [6-9] analysis of the TPO gene in the Dutch HET family¹ was initiated by Dr. Van der Maas and Dr. Skoda discovered the novel point mutation in the TPO gene [2]. A C

G transversion in the splice donor of intron 3 co-segregated with the affected autosomal dominant Hereditary ET (HET) in the family of whom the affected member had increased levels of TPO [2]. This mutation destroys the splice donor site in intron 3 and results in exon 3 skipping. The resulting shortened 5'UTR leads to over production

of thrombopoietin by a mechanism of increased efficiency of the TPO mRNA translation. TPO stimulates megakaryocyte production *via* the MPL signaling pathway both *in vitro* and *in vivo*. Size, number, and mean geometric ploidy of megakaryocytes in HET are pronounced increased by TPO (TPO-HET bone marrow histology, (Figures 2,3)). Congenital gain of function mutation in the TPO gene on chromosome 3q27 results in increased levels of plasma TPO levels and a physiological activation of the TPO TpoR/MPL signalling pathway. This results in hyperproliferation of large mature megakaryocytes (Figures 2,3) in a normocellular bone marrow (Figures 2,3) and increased platelet count and TPO levels (Figure 1) complicated by platelet-mediated microvascular complications [3]. Platelets contain many constituents of the TPO signalling machinery [11,12]. Apart from the TpoR/MPL, platelets contain JAK2, PI-3 kinase, Stat 3 and Stat 5 p^{38} , MAPK and signalling elements downstream of those regulars. Platelet stimulation with a supra-physiological plasma concentration of TPO initiates aggregation and secretion, illustrating TPO act as an independent inducer of platelet responses. Pre-incubation of platelet with 20 ng/ml TPO for 5 minutes increases the amount of serotonin secretion by low a low dose of the agonist thrombin (0.1 U/ml), which is associated with activation of the TPO signalling machinery. This activation together with other activating routes initiated TPO and thrombin leads to subsequent activation of the enzyme cPLA2, which liberates



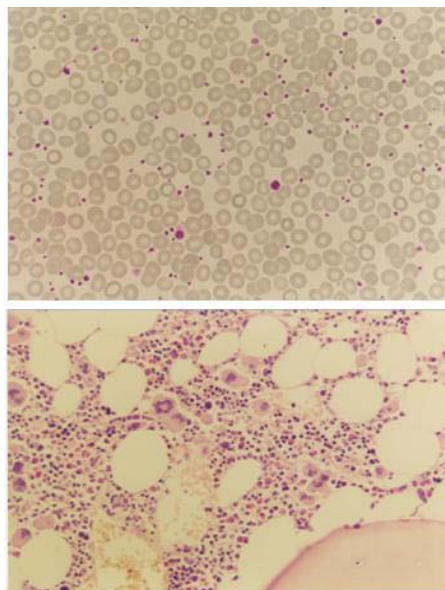


Figure 2: Peripheral blood smear shows marked thrombocytosis with slight anisocytosis and few large platelets in case *II3* with TPO-HET at age of 52 years (1986). The bone marrow is normocellular and shows marked proliferation of large mature megakaryocytes, arranged in loose clusters and no or slight focal reticulin fibrosis grade 0/1.

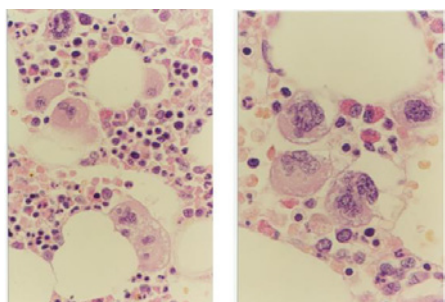


Figure 3: Large mature megakaryocytes with abundant cytoplasm and one cluster of large megakaryocytes with hyperlobulated nuclei in case *II3* with TPO-HET at age of 57 years (1991).

arachidonic acid from membrane phospholipids as a source for platelet cyclo-oxygenase to produce prostaglandin endoperoxides and thromboxane A2 mediating the inflammatory and microvascular manifestation of erythromelalgia [3,13]. Increased TPO levels in symptomatic HET patients induce hypersensitive platelets causing spontaneous platelet aggregates and thrombi at high shear rate in the end-arterial circulation [10-12]. Perfusion models mimicking platelet adhesion in flowing blood show that platelets (including VWF-platelet aggregates) bind to these surface-bound adhesive protein in the absence of a soluble platelet activator. Very low concentrations of plasma TPO (0.01 to 1.0 ng/mL) enhance this platelet-VWF adhesion and VWF-platelet aggregation by more than 50%. In the presence of 1 ng/mL TPO, firm platelet adhesion to the subendothelial surface is almost immediate and reversal of VWF-platelet aggregates/thrombi by high shear stress is prevented, thereby causing platelet thrombi on the subendothelium. These findings show that increased plasma TPO concentrations causes hypersensitive platelets in circulating plasma and thereby have a major effect on the initiation of the

clinical manifestations of spontaneous platelet-mediated arteriolar inflammation and thrombosis at high shear rate in the end-arterial circulation including erythromelalgia, fibromuscular intimal proliferation and its ischemic complications [3], which is preventable by inhibition of platelet cyclo-oxygenase by low dose aspirin [3,13,14].

Evolution of TPO induced HET into myelofibrosis during long-term follow-up

The patients in the affected Dutch HET family members showed no Endogenous Erythroid Colony formation (EEC negative) [14]. The members including the propositus case *II3* of the Dutch family with the gain of function mutation in the TPO gene showed no further increase of platelet counts, no features of PV, and no splenomegaly had developed during life-long follow-up. Bone marrow histology (Figure 2) at time of diagnosis in 1986 of the propositus case *II3* is consistent with ET according to the RCP and ECP criteria [4,5]. A second bone marrow biopsy performed in 1991 showed dense clustering of large megakaryocytes with and hyperlobulated nuclei in a slightly hypercellular bone marrow with reticulin stain grade 0/1 (Figure 3). The histology picture of the third follow-up bone marrow biopsy ten years later at his age of 62 years (1996) had dramatically changed showing a hypocellular bone marrow with a few focal dense clustered dysplastic megakaryocytes and myelofibrosis reticulin grade 3 to 4 ((Figure 4), ECP criteria)) [5], which was associated with low normal values for hemoglobin, hematocrit, erythrocytes and platelet counts around $700 \times 10^9/L$. Subsequent repeated bone marrow aspirations had a dry tap and re-examination of the bone marrow biopsy showed increase of reticulin fibers. The patient died of stroke at age 73 years [13].

In 2010 Posthuma *et al.* updated the natural history of two affected members in generation *II* of the Dutch HET family [14]. Case *II2* died at the age of 71 due to myelofibrosis with severe pancytopenia. The peripheral blood showed leukoerythroblastosis, macrothrombocytes, and teardrop red cells. Bone marrow histology revealed myelofibrosis with dysplastic megakaryopoiesis, granulopoiesis and erythropoiesis, 10% blasts and increased LDH. Case *II8* had a history of diabetes, hypertension and transient ischemic attack in 1989, and was referred in 2008 because of fatigue, anemia and fever (hemoglobin 6.1 mmol/L, leukocytes $4.8 \times 10^9/L$, platelets $90 \times 10^9/L$, 4% blasts and increased LDH, 1509 U/L14. Bone marrow cytology showed 45% myeloid blasts (CD 34/117/13/33 and HLAdr positive) and complex cytogenetic abnormalities: 47, add(2) (p23, del 5q, i (8((q10) + i (*) (10), -18, -20, i (21) (q10), = 2-5 (cp5), an no JAK2V617F mutation. The diagnosis was consistent with AML refractory to treatment and the patient died at the age of 71 years [14]. Patients *II2*, *II3*, *II8* and *III3* were treated with low dose aspirin and did not receive cytoreductive agents. Skoda, Van der Maas, Kralovic and Liu *et al.* described a second Polish family with HET caused by the identical mutation C→G transversion in the splice donor of intron 3 of the THPO gene in 11 affected family members with autosomal dominant HET [15,16]. In the Dutch and Polish HET families TPO receptor (TpoR = Myelo Proliferative Leukemia (MPL) protein expression in platelets was down regulated, which was associated with increased TpoR/MPL mRNA expression in platelets indicating a increased TpoR/MPL receptor protein turnover metabolism indicating *in vivo* platelet activation. From these basic research studies it can be concluded that increased TPO levels in HET patients are caused by a gain of function mutation in the TPO

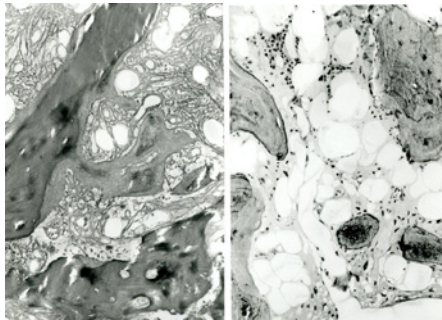


Figure 4: Hypocellular bone marrow (right) with marked Peritrabecular Fibrosis (RF) grade 3 and focal osteosclerosis (left) in case /I3 with TPO-HET at age of 62 years (1996) with low normal values of hemoglobin, hematocrit and erythrocytes and platelet counts around $800 \times 10^9/L$.

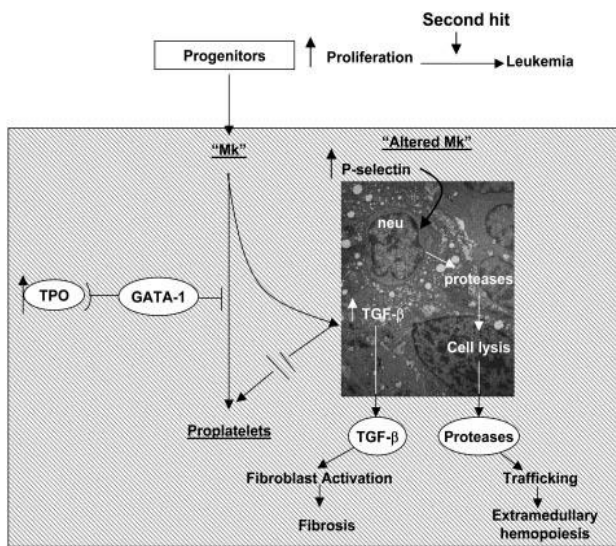


Figure 5: Pathobiologic pathway according to Vannucchi *et al* [18]. Linking TPO, GATA-1, and TGF-beta-1 in the development of megakaryocytic myeloproliferation and secondary myelofibrosis in TPO^{high} mice. Such pathophysiologic etiology of end stage myelofibrosis is also operative in TPO driven Dutch HET family caused by a gain of function mutation in the TPO gene complicated by advanced myelofibrosis occurring at ages around 65 to 70 years [14].

gene that activates the TpoR/MPL pathway thereby causing the ET features of increased platelet counts and increase of clustered large mature megakaryocytes.

Evidence for a decisive role of deregulated TPO in ET comes from observations in mice over expressing a TPO transgene where increased TPO production resulted in a fatal myelofibrosis disorder [17]. High dose exposure to TPO, lethally irradiated mice grafted with bone marrow cells infected with a retrovirus carrying the Murrin TPO cDNA (TPO high mice) developed a lethal myeloproliferative disorder of TPO induced megakaryocytic myelo proliferation (TPO-MF) with reduced erythropoiesis in the spleen and bone marrow [18]. TPO treatment increases platelet counts the number of megakaryocytes and CFU-Mks in the spleen. In TPO high mice abnormally large to giant size of some platelets appear in the circulation of TPO high mice and the overall morphology of the megakaryocytes in the spleen became less mature as revealed by

reduced localization of P-selection and von Willebrand factor on ten alpha granules. In wild type mice TPO treatment decreased GATA-1 content in megakaryocytes, and the development of myelofibrosis is associated with high levels of transforming growth factor beta-1 (TGF-Beta-1) expression in bone marrow and spleen (Figure 5) [18]. The strict association between occurrence of the TPO-induced disease with low GATA-1 content in megakaryocytes and high TGF-Beta-1 expression represent a common pathobiological pathways leading to the sequential development of essential thrombocythemia and subsequent myelofibrotic transformation of the bone marrow in mice and possible of myelofibrosis in thrombocythemia of various molecular etiology in humans. Continuous forced expression of TPO, (TPO high mice) in mice induces megakaryocyte proliferation and differentiation and subsequently develop myelofibrosis [17,18]. TGF-Beta-1 has been implicated in the pathobiology of myelofibrosis by the observation that megakaryocytes from TPO high rates and mice express high levels of TGF-Beta-1 in marrow extracellular fluids and plasma [18] and PDGF was found to be up regulated in a fashion similar to TGF-Beta-1 [17]. High levels of TGF-Beta-1 mRNA in bone marrow and spleen cells in TPO high mice were associated with high levels of TGF-Beta-1 protein in extracellular fluids from these organs (Figure 5).

Villevall *et al.* showed that mice respond to TPO treatment by increasing the number of platelets in the circulation and megakaryocytes in the spleen at day 7 to 10 and returned to pretreatment values at day 14 [19]. Transient mylofibrosis is observed in rats receiving long-term recombinant TPO [19]. In wild type mice, TPO treatment increases platelet counts 2.3 fold, increased number of megakaryocytes and CFU-Mks, and had profound effects on the morphology of megakaryocytes in wild type mice. In TPO reconstituted mice abnormally large size of some platelets were seen and the megakaryocyte morphology in the spleen became less mature as revealed by reduced localization of P-selection and von Willebrand factor on ten alpha granules. In addition, a significant portion of these megakaryocytes had heavy-electron dense para-apoptotic morphology and contained neutrophils embedded in the cytoplasm, as confirmed by myeloperoxidase immunostaining. In wild type mice TPO treatment decreased GATA-1 content in megakaryocytes, and the development of myelofibrosis is associated with high levels of transforming growth factor beta-1 (TGF-Beta-1) expression in bone marrow and spleen (Figure 5) [19]. The strict association between occurrence of the TPO-induced disease with low GATA-1 content in megakaryocytes and high GF-beta-1 expression represent a common pathobiologic pathways leading to the sequential development of essential thrombocythemia and subsequent myelofibrotic transformation of the bone marrow in mice (Figure 5) and possible of myelofibrosis in thrombocythemia of various molecular etiology in humans. Continuous forced expression of TPO, (TPO high mice) in mice induces megakaryocyte proliferation and differentiation and subsequently develop myelofibrosis [9,10]. TPO high mice engineered to over express TPO in their liver and those that received transplants of marrow cells infected with a TPO containing retrovirus develop thrombocythemia due to massive hyperplasia of megakaryocytes and granulocytes and hypoplasia of erythropoiesis in the bone marrow followed by myelofibrosis and extramedullary hematopoiesis within 2 to 3 months and die from myeloid metaplasia and myelofibrosis thereafter [10]. TGF-beta has been implicated in the pathobiology

of myelofibrosis by the observation that megakaryocytes from TPO high rates and mice express high levels of TGF-Beta-1 in marrow extracellular fluids and plasma (Figure 5) [19]. In wild mice TGFB1 mRNA expression in bone marrow and spleen was barely detectable before TPO treatment, and significantly increased in both organs after TPO treatment and returned to basal levels at day 14 (Figure 5) [19]. Another growth factor produced by megakaryocytes, PDGF, was found to be upregulated in a fashion similar to TGB1 [19]. High levels of TGB1 mRNA in bone marrow and spleen cells in TPO high mice were associated with high levels of TGF-Beta-1 protein in extracellular fluids from these organs (Figure 5).

References

- Schlemper RJ, van der Maas AP, Eikenboom JC. Familial essential thrombocythemia: clinical characteristics of 11 cases in one family. *Ann Hematol.* 1994; 68: 153-158.
- Wiestner A, Schlemper RJ, Van der Maas AP, Skoda RC. An activating splice donor mutation in the thrombopoietin gene causes hereditary thrombocythemia. *Nat Genet.* 1998; 18: 49-52.
- Michiels JJ, Abels J, Steketee J, Van Vliet HH, Vizevski VD. Erythromelalgia caused by platelet-mediated arteriolar inflammation and thrombosis in thrombocythemia. *Ann Intern Med.* 1985; 102: 466-471.
- Michiels JJ, Juvonen E. Proposal for revised diagnostic criteria of essential thrombocythemia and polycythemia vera by the Thrombocythemia Vera Study Group (TVSG). *Semin Thromb Hemost.* 1997; 23: 339-347.
- Michiels JJ, Thiele J. Clinical and pathological criteria for the diagnosis of essential thrombocythemia, polycythemia vera and idiopathic myelofibrosis (agnogenic myeloid metaplasia). *Int J Hematol.* 2002; 76: 133-145.
- Wendling F, Marskovsky E, Debili N, Florindo C, Teepe M, Titeux M, *et al.* cMpl ligand is a humoral regulator of megakaryopoiesis. *Nature.* 1994; 369: 571-574.
- Kaushansky K, Lok S, Holly RD, Broudy VC, Lin N, Bailey MC, *et al.* Promotion of megakaryocyte progenitor expansion and differentiation by c-Mpl ligand thrombopoietin. *Nature.* 1994; 369: 568-571.
- Sohma Y, Akahori H, Seki N, Hori T, Ogami K, Kato T, *et al.* Molecular cloning and chromosomal localization of the human thrombopoietin gene. *FEBS PRESS.* 1994; 353: 57.
- Yan XQ, Lacey D, Hill D, Chen Y, Fletcher F, Hawley IK, *et al.* A model of myelofibrosis and osteosclerosis in mice induced by overexpressing thrombopoietin (mpl ligand): reversal of disease by bone marrow transplantation. *Blood.* 1996; 88: 402-409.
- Akkerman JW. Thrombopoietin and platelet function. *Semin Thromb Hemost.* 2006; 32: 295-304.
- Van Willigen G, Gorter G, Akkerman JW. Thrombopoietin increases platelet sensitivity to alpha-thrombin via activation of ERK-2-cPLA2 pathway. *Thromb Haemost.* 2000; 83: 610-616.
- Van Os E, Wu Y, Pouwels JG, *et al.* Thrombopoietin increases platelet adhesion under flow and decreases rolling. *Br J Haematol.* 2003; 121: 482-490.
- Michiels JJ. Aspirin responsive erythromelalgia in JAK2-thrombocythemia and incurable inherited erythrothermalgia in neuropathic Nav1.7 sodium channelopathy: from Mitchell 1878 to Michiels 2017. *Expert Opinion on Orphan Drugs.* 2017.
- Posthuma HL, Skoda RC, Jacob FA, Van der Maas AP, Valk PJ, Posthuma EF. Hereditary thrombocytosis not as innocent as thought? Development into acute leukemia and myelofibrosis. *Blood.* 2010; 110: 3375-3376.
- Kralovics R, Buser AS, Teo SS, Coers J, Tchelli A, van der Maas APC, *et al.* Comparison of molecular markers in a cohort of patients with chronic myeloproliferative disorders. *Blood.* 2003; 102: 1869-1871.
- Liu K, Kralovics R, Ridzli Z, Grabovsky B, Buser AS, Olcaydu D, *et al.* A de novo splice donor mutation in the thrombopoietin gene causes hereditary thrombocythemia in a Polish family. *Haematologica.* 2008; 93: 706-714.
- Villeval JL, Cohen-Solal K, Tulliez M, Giraudier S, Guichard J, Burstein SA, *et al.* High thrombopoietin production by hematopoietic cells induces a fatal myeloproliferative syndrome in mice. *Blood.* 1997; 90: 4369-4383.
- Vannucchi A, Bianchi L, Paoletti F, Pancrazzi A, Torre E, Nishikawa M, *et al.* A pathobiologic pathway linking thrombopoietin, GATA-1, and TGF-beta1 in the development of myelofibrosis. *Blood.* 2005; 105: 3493-3501.
- Michiels JJ, De Raeve H, Valster F, Potters V, Kim Y, Kim M. Extension of 2016 World Health Organization (WHO) Classification into a New Set of Clinical, Laboratory, Molecular, and Pathological Criteria for the Diagnosis of Myeloproliferative Neoplasms: From Dameshek to Vainchenker, Green, and Kralovics. *Eur Med J* 2017; 2: 72-81.