

Special Article - COVID-19

Concern for Pericarditis in a COVID-19 Positive Patient

Griffith N¹, Lance DOS¹, Orr L² and Vinayak A^{2*}¹Department of Internal Medicine, MedStar Georgetown University Hospital, USA²Division of Pulmonary, Critical Care and Sleep Medicine, Department of Internal Medicine, MedStar Georgetown University Hospital, USA

***Corresponding author:** Ajeet Vinayak, Division of Pulmonary, Critical Care and Sleep Medicine, Department of Internal Medicine, MedStar Georgetown University Hospital, Washington, District of Columbia, 3800 Reservoir Rd, NW, Washington, DC, 20007, USA

Received: May 06, 2020; Accepted: May 18, 2020;

Published: May 25, 2020

Abstract

This report describes a 53-year-old male with a medical history of cerebral palsy and developmental delay who presented to the hospital with a fever, cough, and dyspnea and subsequently tested positive for Coronavirus Disease of 2019 (COVID-19). His hospital course was complicated by worsening acute respiratory failure requiring admission to the intensive care unit and intubation. He was subsequently found to have diffuse ST elevations on telemetry with follow-up Electrocardiogram (ECG) confirming these findings. A diagnosis of acute pericarditis was suspected, however unconfirmed given that other diagnostic criteria were limited or negative. A decision was made to withhold treatment given the equivocal nature of the diagnosis and the patient's comorbidities. Viral infections are one of the leading inciting factors for acute pericarditis, but to our knowledge, there have been no previously reported cases associated with the novel coronavirus. This report describes acute pericarditis as a possible complication of COVID-19 infection and explores the diagnostic and treatment challenges in this patient population.

Keywords: COVID-19; SARS-CoV-2; Pericarditis

Case Description

A 53-year-old man with a history of cerebral palsy and developmental delay presented to the emergency department with fever, cough, and dyspnea and subsequently tested positive for Coronavirus Disease of 2019 (COVID-19). He was admitted to the medicine floor for acute hypoxic respiratory failure initially requiring 2 liters of supplemental oxygen and was started on hydroxychloroquine and azithromycin. On hospital day six, the patient developed worsening hypoxic respiratory failure leading to intensive care unit admission and subsequent intubation. Labs were notable for elevated inflammatory markers including serum ferritin 4,128 ng/mL, erythrocyte sedimentation rate 104 mm/hr, C-reactive protein 243 mg/L and interleukin-6 level 18 pg/mL. Given his rising inflammatory markers and clinical course, the patient was given a single dose of 800 mg tocilizumab. The following day, ST-elevations were noted on telemetry and ECG confirmed concave, diffuse ST-elevations and PR-depressions consistent with acute pericarditis (Figure 1). Physical exam was negative for a pericardial rub and labs showed troponins within normal limits. A bedside echocardiogram followed by a formal transthoracic echocardiogram showed no signs of pericardial effusion and a normal ejection fraction. Given the ambiguous nature of the diagnosis of acute pericarditis and that the patient had concurrent acute kidney injury, a decision was made to withhold treatment with Nonsteroidal Anti-Inflammatory Drugs (NSAIDs) and colchicine. A repeat ECG showed resolution of ST-elevations after four days.

Conclusion

Viral infections have often been described as a cause of pericarditis and myocarditis. Although less is known about the cardiovascular complications of Severe Acute Respiratory Syndrome Coronavirus 2 (SARS-CoV-2), the novel virus has been linked to myocarditis, myopericarditis, and heart failure [1-4]. While cases of acute pericarditis

have been reported in a related coronavirus, MERS-CoV, none have been reported as a complication of COVID-19.

The case discussed above suggests a likely diagnosis of acute pericarditis caused by COVID-19, however it also highlights the diagnostic and treatment challenges with this patient population. A definitive diagnosis of pericarditis is made when two of four clinical criteria are met [5]. While this patient had classic ECG changes consistent with acute pericarditis, a history of typical chest pain was unable to be obtained given the patient was sedated and intubated. Furthermore, inflammatory markers are typically already elevated and immediate formal imaging studies such as transthoracic echocardiogram, computed tomography and magnetic resonance imaging have been limited in this patient population due to concerns of spreading the infection. In addition to the diagnostic limitations, the decision to treat these critically ill patients who often have multiorgan involvement can be challenging- especially when the

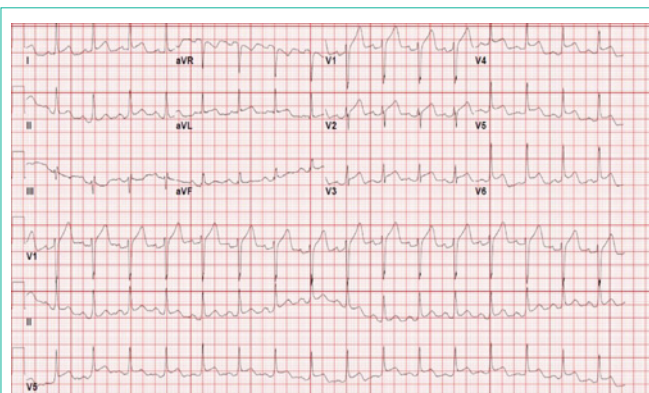


Figure 1: Electrocardiography showing sinus rhythm, diffuse depressed PR intervals, diffuse concave ST-segment elevation (especially in the anterolateral leads), and ST-segment depression with T-wave inversion in lead aVR- findings consistent with acute pericarditis.

diagnosis of acute pericarditis is not definitive.

COVID-19 has been linked to myocarditis, myo-pericarditis, and other cardiac complications; however, no cases of acute pericarditis have been reported. Here we present a likely case of acute pericarditis in a COVID-19 patient and highlight the diagnostic and treatment challenges with this patient population. As with many other aspects of this novel virus, more literature is needed to improve diagnostic and treatment guidance of acute pericarditis in these patients.

References

1. Kochi AN, Tagliari AP, Forleo GB, Fassini GM, Tondo C. Cardiac and arrhythmic complications in patients with COVID-19. *J Cardiovasc Electrophysiol.* 2020; 1-6.
2. Hua A, O'Gallagher K, Sado D, Byrne J. Life-threatening cardiac tamponade complicating myo-pericarditis in COVID-19. *European Heart Journal.* 2020.
3. Imazio M, Gaita F. Diagnosis and treatment of pericarditis. *Heart.* 2015; 101: 1159-1168.
4. Inciardi RM, Lupi L, Zaccone G, Italia L, Raffo M, Tomasoni D, et al. Cardiac Involvement in a Patient With Coronavirus Disease 2019 (COVID-19). *JAMA Cardiol.* 2020.
5. Klein A, Abbara S, Agler DA, Appleton CP, Asher CR, Hoit B, et al. American Society of Echocardiography Clinical Recommendations for Multimodality Cardiovascular Imaging of Patients with Pericardial Disease. *Journal of the American Society of Echocardiography.* 2013; 26; 965-1012.