

## Research Article

# Intercostobrachial Nerve - Anatomical Considerations and its Importance in Carcinoma Breast of Female Patients

Kumar P<sup>1</sup>, Meena RN<sup>2\*</sup>, Sheikh BA<sup>3</sup>, Belliappa V<sup>4</sup> and Pais AV<sup>5</sup>

<sup>1</sup>Junior Consultant, Department of Surgery, PSRI Hospital, New Delhi, India

<sup>2</sup>Assistant Professor, Department of General Surgery, Institute of Medical Sciences, Banaras Hindu University, Varanasi, India

<sup>3</sup>Senior Resident, Department of Surgery, PSRI Hospital New Delhi, India

<sup>4</sup>Chief of the Oncoplastic Breast Surgery Unit, Senior Consultant Surgical Oncology and Head, General Surgery, Narayana Hrudayalana Institute of Medical Sciences, Bangalore, India

<sup>5</sup>Senior Consultant Surgical Gastroenterology and General Surgery, Narayana Hrudayalana Institute of Medical Sciences Bangalore, India

\*Corresponding author: Ram Niwas Meena, Assistant Professor, Department of General Surgery, Institute of Medical Sciences, Banaras Hindu University, Varanasi – 221005, India

**Received:** November 04, 2016; **Accepted:** December 01, 2016; **Published:** December 05, 2016

## Abstract

**Background:** Complete axillary node dissection is commonly performed in the management of breast cancer for oncological clearance as well as in the staging of the disease. The aim of the present study was to assess the beneficial effects of preservation of intercostobrachial nerve and its anatomical variation during the surgery (modified radical mastectomy and breast conserving surgery).

**Method:** A total of 50 female patients with breast cancer underwent Muzamdar Cancer Centre of Narayana Hrudayalaya Hospital Bangalore between February 2010 and January 2012. For the purpose of ICBN preservation, the patients were randomly divided into two groups that is one with preservation of ICBN and one with non-preservation and intraoperative type of ICBN noted as classified by Cunnick et al. The numbness in area supplied by ICBN, paraesthesia in both the arms and assessment of pain by VAS score were recorded. Postoperative assessment was done 24 hours, 3 and 7 days after surgery. Thereafter, re-assessment was done after 1 and 6 months from day of surgery.

**Result:** We have found all the six variants of ICBN as: Type I (40%), type II (24%), Type III (14%), Type IV (4%) Type V (6%) and Type VI (12%). At 1 month all the patients in both the groups did not complain numbness and paresthesia ( $p=1.00$ ). At 6 months (80%) in non-preserved group had numbness as compared to (20%) in preserved group of ICBN ( $p<0.001$ ), similarly (75%) in non-preserved group had paresthesia as compared to (25%) in preserved group of ICBN after 6 months ( $p = 0.004$ ) which shows that both numbness and paresthesia are significantly decreased over a period of time in preserved group of ICBN. There was significant decrease in pain in preserved group of ICBN after 6 months versus nonpreserved group of ICBN ( $p<0.001$ ). Local relapse was not observed in any group after 36 months of follow-up.

**Conclusion:** As per our knowledge, this is the first study which describes the various anatomical variants encountered during axillary clearance surgery. Our study shows that the morbidity resulting from division of the ICBN during axillary surgery is significant. Preserving ICBN significantly reduces paraesthesia, numbness and pain.

**Keywords:** Breast cancer; Intercostobrachial nerve; Axillary dissection

## Introduction

Breast Cancer is one of the most common malignancy affecting women all over the world. The incidence has increased over a period of time due to lifestyle and environmental changes. The majority of patients presenting with breast cancer undergo surgical resection (whether a mastectomy or breast conservation surgery including an axillary clearance).

Surgery of the breast is dominated by the surgery of breast cancer, which affects up to 1 in 12 women at some time during their lifetime. Radical surgery for breast cancer traditionally involved the excision of the whole breast and the axillary lymph nodes. The original radical operation of Halstead radical mastectomy [1] included removal of the whole breast, the axillary contents and the pectoral muscles. Extended radical mastectomy is a logical extension to a Halstead

radical mastectomy which achieves more radical thoracic and supraclavicular nodes clearance. However, morbidity is increased without significant advantages in survival or local control, and these extensive procedures are for the most part abandoned.

It is estimated that over 50 per cent of women suffer chronic pain following the treatment for breast cancer surgery. It seriously affects quality of life through the combined impact of physical disability and emotional distress. Chronic pain following treatment for breast cancer surgery is a significantly under-recognized and under-treated problem. Neuropathic pain is the most prevalent type of pain and it may be derived from the breast cancer, breast cancer surgery and non-surgical treatment. The surgery-related pain syndromes present as pain in the surgical scar, chest wall and upper arm, as well as shoulder discomfort and phantom breast dysesthesias and paraesthesias.

It has been reported that up to half of patients report negative impact of pain on their activities and up to one-quarter report moderate to high impact on their daily activities at home and work [2]. Studies have also found that breast cancer surgery patients with post operative morbidity have a greater psychological stress and psychiatric morbidity than the general population [3,4].

Nerve preservation approaches have shown reduced incidence of sensory deficits (53 percent vs. 84 percent of women) but nerve sparing is only successful in 65 percent of the cases where it was attempted [5].

The complications [6-12] associated with axillary node clearance after breast cancer surgery are well recognized and include – wound infection, lymphoedema, Seroma, limitation of shoulder movement, pain and arm paraesthesias. The long thoracic & thoracodorsal nerves, which are major motor nerves are routinely identified and preserved during axillary surgery, but the intercostobrachial nerve (ICBN) is often scarified. The ICBN [13] is the lateral cutaneous branch of the second intercostal nerve; it is sensory to the skin of the medial upper arm. Teicher et al [14] described a technique in 1982 to preserve the ICBN as it was their belief that sacrifice caused symptoms of discomfort. Since then, preservation of the ICBN has been recommended by several groups [15,16].

The present study was conducted to assess the beneficial effects of preservation of intercostobrachial nerve and its anatomical variation during the surgery (modified radical mastectomy and breast conserving surgery).

## Methods

This study was conducted in Muzamdar Cancer Centre of Narayana Hrudayalaya Hospital Bangalore over a period of 2 years from February 2010 to January 2012. A total of 50 female patients diagnosed to have carcinoma of breast were recruited in this study. Informed consent was taken from each of the patients. Patients with age group 35-70 years, unilateral early female breast cancers (stage I, IIA, IIB) and no clinically detected nodal tissue were included in the study. Axillary node dissection was performed in each of these patients either as part of MRM or along with BCT by the same surgeon. For the purpose of ICBN preservation the patients were randomly divided into two groups that is one with preservation of ICBN and one with non-preservation and intraoperative Type of ICBN noted as classified by Cunnick et al [17].

### Pre-operative assessment

A detailed clinical history with assessment of presence of arm and axillary pain, weakness, paresthesia was carried out in every patient prior to surgery. A visual analogue score with maximum score of 10 and minimum score of 0 explained to each patient and the assessment of the pain on the medial side of arm was done by using the score. Each patient was assessed preoperatively for the presence of the pain numbness in area supplied by ICBN and par aesthesia in both the arms was recorded.

### Intra-operative assessment

Intra-operative observation included the ease of identification, separation and preservation of ICBN. As the axillary contents were dissected off the axillary vein and dissection proceeded inferiorly and

posteriorly in the medial part of the axilla, the ICBN was routinely encountered running directly across the axillary fat. It was dissected free to the point at which it enters the arm just anterior to where latisimus dorsi crosses the axillary vein. Caution was taken during the lateral dissection of the axilla where the nerve was in greatest jeopardy; this part of the dissection was performed last. No attempt was made to preserve the lateral branches of the third or fourth intercostal nerves. Total time taken for surgery in preservation and non preservation of ICBN was recorded and the type of nerve noted as per classification of Cunnick. In our study duration of operation was defined as the time taken from the moment of making an incision to the time of last stitch to close the incision.

### Post-operative assessment

Postoperative pain score was assessed on Visual Analogue Scale. Post operative assessment was done 24 hours after surgery and then subsequently after 3 & 7 days. Thereafter, re-assessment was done after 1 and 6 months from day of surgery. Each time the pain score was recorded. Assessment for any paresthesia & numbness in area supplied by ICBN in the post operative period was also done by neurological examination. Each patient was assessed for any sensory deficit to light touch, pin prick in the area supplied by ICBN on the side of axillary clearance and compared to opposite side. Assessment was done at the time of discharge, 1 and 6 months. Findings noted in preset proforma.

The scores were recorded and a mean score was arrived at the end of 6 months, which was indicative of change in quality of life of the patient post surgery.

In the post operative period each patient was given a set of similar antibiotics & analgesics. The antibiotic was administered I/V for the first day (post op) thereafter patient was put on oral antibiotics which was continued for 5 days. Pain relief was achieved by giving analgesics (dose being same for each group). Analgesia was in the form of intravenous paracetamol 1gm thrice a day for the first day thereafter shifted to oral administration. Most of the patients were discharged at 24 to 72 hours.

All the analyses were done using SPSS V [18]. Descriptive statistics were reported using mean (SD) for continuous variables, number and percentage for categorical variables. Chi-square test was used to test the association between the Paraesthesia and numbness with the preservation of ICBN. Independent test was used to compare the VAS-pain scores at each time point between the preservation of ICBN. Repeated measures ANOVA were used to compare the pain scores over time between the preservation of ICBN groups. Probability value less than 5% was considered as statistically significant.

## Result

The characteristics of the breast cancer cases identified in this study are summarized in Table 1. The preservation of the intercostobrachial nerve during axillary dissection in patients with breast cancer resulted in a significant improvement in paraesthesias, numbness and pain at 6 months as compared with the standard dissection in which the nerve is routinely sacrificed (Table 2). The mean time difference between the preserved and unpreserved surgery of ICBN was 5 minutes. The surgery where the nerve was preserved took a longer time (Table 2).

**Table 1:** Characteristics of the study population.

Variables	Number	Percentage
Staging of disease		
1 A	7	14
1 B	14	28
2 A	15	30
2 B	14	28
Type of surgery		
BCT	22	44.0
MRM	28	56.0
Preservation of ICBN		
Yes	25	50.0
No	25	50.0
Type of ICBN observed as per Cunnick classification		
1	20	40
2	12	24
3	7	14
4	2	4
5	3	6
6	6	12
Paraesthesia at discharge		
No	50	100
Paraesthesia at 1 month		
Yes	10	20
No	40	80
Paraesthesia at 6 month		
Yes	20	40
No	30	60
Numbness at discharge		
No	50	100
Numbness at 1 month		
No	50	100
Numbness at 6 month		
Yes	25	50
No	25	50

Comparison of mean pain score at 24 hours, 3 days, 7 days, 1 month, and 6 months between preserved and un-preserved group of ICBN is shown in Figure 1. The mean pain score recorded at 24 hours for non preserved ICBN and preserved ICBN groups are the same. However, at 3 days it was (4.92 ± 2.08 SD) for non preserved group and (4.92 ± 2.08 SD) for preserved group. At 7 days, it become (4.48 ± 1.96 SD) for non preserved group and (4.16 ± 1.65 SD) for preserved group of ICBN, no significant difference between the two groups. Similarly at 1 month, no difference have been found in pain score in both groups of ICBN. However there is significant decrease of pain in preserved group ICBN as compared with non preserve group ICBN at 6 month (P<0.001). This shows that over a period time (6 months) the pain is significantly decrease in the preserved group of ICBN as

**Table 2:** Association of paraesthesia, numbness, type of surgery, time of surgery and preservation of ICBN.

Paraesthesia	Preservation of ICBN		P value
	Yes	No	
Paraesthesia at discharge No	25 (50)	25 (50)	-
Paraesthesia at 1 month			1.00
Yes	5 (50)	5 (50)	
No	20 (50)	20 (50)	
Paraesthesia at 6 month			0.004
Yes	5 (25)	15 (60)	
No	20 (75)	10 (40)	
Numbness at discharge			-
No	25 (50)	25 (50)	
Numbness at 1 month			-
No	25 (50)	25 (50)	
Numbness at 6 month			<0.001
Yes	5 (20)	20 (80)	
No	20 (80)	5 (20)	
Time of surgery in minutes	98.8 ± 9.3	93.2 ± 10.6	0.05
Type of surgery			0.56
BCT	12 (54.5)	10 (45.5)	
MRM	13 (45.4)	15 (53.6)	

**Table 3:** Type of ICBN observed during surgery.

Type of nerve as per classification of Cunnick	Number	Percentage
1	20/50	40
2	12/50	24
3	7/50	14
4	2/50	4
5	3/50	6
6	6/6	12

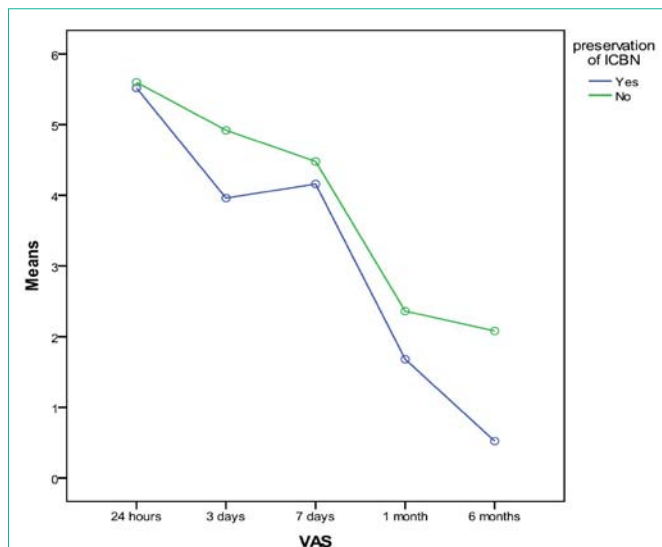
compared with non preserved of ICBN group.

The various anatomical variants of intercostobrachial nerve have been observed as per classification of Cunnick. We have seen all the types of variation in our study which was described by Cunnick, the various variant which was observed during this study are shown in Table 3.

## Discussion

Complete axillary node dissection is commonly performed in the management of breast cancer. The importance of axillary LN dissection helps in oncological clearance as well as in the staging of the disease. The majority of surgeons routinely sacrifice the ICBN to enable a thorough clearance of the axilla and the technical difficulty involved while trying to preserve the nerve. The ICBN is easily identified during axillary dissection. This nerve is the lateral cutaneous branch of the second intercostal nerve. From its origin, it crosses the axilla to reach the medial side of arm.

To protect the nerve, the axillary contents are first reflected off



**Figure 1:** Comparison of Mean Pain score at 24 hours, 3 days, 7 days, 1 month and 6 months between preserved and un-preserved group of ICBN.

the axillary vessels medially, and the dissection proceeds inferiorly & posteriorly in the medial axilla. The ICBN is routinely encountered before the long thoracic nerve is identified. The ICBN is then dissected free from the fatty axillary tissues until it enters the medial arm in the region where the axillary vein crosses the tendon of latissimus dorsi.

Anatomical variants of intercostobrachial nerve are noted as per classification of Cunnick [17]. He has described the following variants.

Type 1 – arises from T2 alone and does not give off any branches.

Type 2 – arises from T2 alone and divides into a large main trunk and a much smaller branch.

Type 3 – arises T2 alone and divides equally into two branches.

Type 4 – formed by two equal-sized branches from T1 and T2 nerves. No significant branches during its course through the axilla.

Type 5 – arises from two separate T2 radicals to form a single nerve which does not give off branches in the axilla.

Type 6 – arises from T2 alone and divides into a large main trunk and at least two smaller branches (range: 2-5 branches).

The incidence of each of these is also described by Cunnick [17] as type I-(42%), type II-(22), type III - (11%), type IV- (9%), type V-(9%) and type VI (7%). This was the first study which has described the various anatomical variants encountered during axillary clearance surgery. In India one study was done in 2011 by Satyajeet et al [18] who has also described the various anatomical variant as per Cunnick. He found type I (69.6 %) but did not find any type of V. In our study we have found all the six variants as; Type I (40%), type II (24%), Type III (14%), Type IV (4%), Type V (6%) and Type VI (12%). So type 1 is the common in all studies followed by type 2,

This study also shows a significant benefit to sensory function by saving the ICBN. More importantly, it also diminishes the incidence of pain, paresthesia & numbness which cause alarming discomfort

and are often associated with routine sacrifice of the ICBN.

Teicher et al [14] in 1982 have shown that decrease in morbidity with this modified procedure (preservation of ICBN) who reported their preliminary experience with 30 patients and Latteri et al [19] in 1985 studied the significance of preservation of intercostobrachial nerve during axillary dissection for carcinoma breast. Our study confirms the significance of perseveration of intercostobrachial nerve and its various anatomical variations.

In 1985 Temple et al [15] did a study of the 50 patient with stage 1 breast cancer with preservation of intercostobrachial nerve; only 2 among these had marked sensory losses. Ninety-five percent of these patients had relatively normal sensation. The area of greatest risk for sensory change in these patients was in the region of the posterior axillary fold (32 percent). None of these patients complained of postoperative dysesthesias or paraesthesias. Mean length of follow-up was 29 months with a range of 6 to 60 months. No patient had a regional recurrence of cancer despite the fact that 33 percent of these patients had involved nodes.

Resection of the intercostobrachial nerve in the 15 patients studied resulted in significant changes in sensory function. The incidence of marked changes significantly increased from 4 percent to 55 percent with sacrifice of the intercostobrachial nerve ( $p < 0.001$  by the chi-square test). Similarly, 33 percent of these patients noted paresthesia, dysesthesia or both postoperatively in the sensory territory of the intercostobrachial nerve. This increase was also significant ( $p < 0.001$ ). However, none of the five patients complained of dysesthesias 6 months postoperatively. In our study the length of follow up was up to 6 months which showed significant difference in the pain score of the ICBN preserved category ( $p = < 0.001$  at 6 months). However numbness and Paraesthesia also show significant difference at 6 months. Patients complaining numbness at the end of 6 months in the ICBN preserved category was (20%) patient as compared with non preserved ICBN group (80%). Paraesthesia at the end of 6 months in ICBN preserved category was (25%) as compared with non preserved group (75%) with ( $p = 0.004$ ). This shows a significant decrease of numbness and paresthesia after 6 months of surgery.

In 1998 Abdullah, et al [5] studied the feasibility and benefit of preserving the ICBN. Preserving the ICBN was feasible in 39 (65 per cent) of the 60 patients randomized to the preservation group. Preserving the nerve prolonged the procedure by a median of 5min. No difference in sensory symptoms between the groups was seen at 3 months. At 3 months 53 per cent of patients randomized to ICBN preservation had a sensory deficit compared with 84 per cent of those randomized to ICBN sacrifice ( $P < 0.05$ ). He concluded that preserving the ICBN reduces the incidence of sensory deficit (but not symptoms) in patients after axillary clearance. However in our study the mean duration of surgery of preserved ICBN was 98 minutes as compared with non ICBN 93 minutes. And a significant difference in sensory symptoms (numbness) between the groups was seen at 6 months ( $p < 0.001$ ). Preserving the nerve prolonged the procedure by 5 minutes. This is clinically insignificant

In 2003 Freeman et al [20] did a study to assess long term results of preservation of the intercostobrachial nerve. Follow up was at approximately 3 years post-operatively (range 32-38 months) at

which time 16 patients had died, two were known to have metastatic disease and were excluded and seven had been lost to follow-up. The remaining 95 patients were sent a letter requesting attendance at a clinic and a questionnaire asking details about their current symptoms.

He found that there was no difference in limitation of daily activities, shoulder stiffness or Neuroma formation. Comparing actually preserved and divided groups the patient assessment of 'different sensation' differed ( $p = 0.006$ ) and the total area of abnormal sensation was significantly distinct between the two groups with a smaller area of sensory loss in the actually preserved group ( $p = 0.009$ ).

The ICBN, which lies embedded within the axillary contents, often sacrificed due to technical difficulty and because of concerns regarding compromise of clearance. Benefits of preserving the ICBN have been reported in several descriptive studies and include a reduction in postoperative pain, improved sensation and reduced arm stiffness. This study concluded that the alteration in sensation that occurs following axillary node surgery cannot be solely attributed to preservation or sacrifice of the ICBN. This was confirmed by the fact that some patients whom had documented nerve sacrifice had normal sensation and yet many with nerve preservation did not. The anatomy and distribution of the nerve supply to the axilla and upper arm has been shown to be highly variable. The ICBN may have direct connections with the third intercostal nerve, the medial cord of the brachial plexus or the medial cutaneous nerve of the arm, as well as providing a branch to the posterior axillary fold; it usually provides several branches to the axillary contents. The distribution varies from the upper third of the arm to below the elbow. It is therefore easy to see how division in the axilla may have markedly different consequences for different patients. There was no attempt to preserve the third and fourth intercostals nerves in the above mentioned study, and given the variable anatomy, this may have been a confounding element. They observed that both the prevalence and total area of sensation became worse over time in a proportion of patients. It may be concluded from this that, with wound resolution to scar tissue, the function of the preserved nerve has become compromised in these patients.

The situation with regard to the presence of pain was similar to that of sensation, in that there was no clear difference between the two groups at 3 months or 3 years. Six patients who had pain after 3 months had been pain-free at 3 years and a further 11 patients had developed pain who had been pain free at 3 months implying that this also is a dynamic situation. They concluded that preservation of the intercostobrachial nerve can usually be performed; only marginally increases the operation time and doing so does not affect patient survival. It improves patient sensory deficit significantly.

In our study there was significant difference between the two groups at 1 and 6 months in respect to Paraesthesia & numbness. At 1 month all the patients in non preserved group and preserved group did not complained numbness and paresthesia. At 6 months (80%) in non preserved group had numbness as compared to (20%) in preserved group of ICBN. Similarly (75%) in non-preserved group had paresthesia as compared to (25%) in preserved group of ICBN after 6 months ( $p = 0.004$ ) which shows that both numbness

and paresthesia are significantly decreased over a period of time in preserved group of ICBN. As per their study there was only marginal increase in the operation time. In our study preserving the nerve prolonged the procedure by 5 minutes only. This is clinically not so significant.

In 2003 study was done by Toreesan et al [21] who evaluated the relationship between preservation of the intercostobrachial (ICBN) nerve and pain sensitivity of the arm, the total time of the surgery, and the number of dissected nodes in patients submitted to axillary lymphadenectomy due to breast cancer. An interventional, prospective, randomized, and double blind study was performed on 85 patients. The patients were divided into two groups, according to whether the ICB nerve was preserved or not. The surgeries were performed by the same surgeons, utilizing the same technique. The postoperative evaluations were performed at 2 days, 40 days and 3 months. The surgical technique presented a feasibility of 100% and preservation of the ICB nerve was related to a significant decrease in the pain sensitivity of the arm, both in the subjective and objective evaluations. After 3 months, in the subjective evaluation, 61% of the patients were asymptomatic in the ICB nerve preservation group, with 28.6% in the nerve section group ( $p < 0.01$ ). In the objective evaluation, 53.7% of the patients presented normal neurological examination in the ICB nerve preservation group, with 16.7% in the nerve section group ( $p < 0.01$ ). No significant difference was observed in the total time of the surgery ( $p = 0.76$ ) and the number of dissected nodes between the two groups ( $p = 0.59$ ). Local relapse was not observed in any group after 36 months of follow-up. Our study also shows that preservation of intercostobrachial nerve decrease the pain, numbness and paresthesia. the difference of surgery between preservation and non preservation is marginal (5 minutes). This is clinically insignificant.

Complications of axillary surgery for breast cancer and whether preservation intercostobrachial nerve (ICBN) reduces this morbidity was studied by Kim O. Taylor et al [22] in 2003 conducted a study and one hundred and seventy of 208 (82%) questionnaires were returned completed. At least one symptom was reported by 130 (76.5%) of patients. Numbness was the most common symptom, present in 60% overall. Patients who had the ICBN preserved reported significantly less numbness (37.5% vs 71.7%  $P < 0.001$ ). Pain was present in 45.3% of patients and those with the ICBN preserved had significantly less pain (31.3% vs 58.5%  $P = 0.02$ ). Whereas in our study it found that pain reduces constantly over the post operative period as is evident from the mean values of the pain scores. There was significant difference in the pain at 24 hours ( $p = 0.12$ ) and 6 months ( $p = < 0.001$ ) months of follow up. Other studies showing significant decrease in pain after preserving intercostobrachial nerve were conducted by Wei et al [23] in 2005 who studied the clinical value of preserving ICBN during the axillary lymph nodes excision in breast cancer operations. As per their study one hundred and sixty-two cases of stages I, II and IIIa breast cancer patients were preserved in experimental group and not in control group. Both groups were treated following the practice guideline of breast cancer, and found no recurrence during 4 to 36 months following up. The postoperative arm sensory distribution was 22.2% in experimental group, which was also significantly different from that of control group 31.1% ( $\chi^2(2) = 7.86, p < 0.01$ ). In comparison, our study was limited to 50 patients having T1 and

T2 lesion and we concluded that there was significant difference in pain in the preserved group as compared to non-preserved group over period of time. Though pain reduced constantly over the post operative period as evident from the mean values of the pain scores. Application of chi square showed that there was significant pain difference at 6 months ( $p < 0.001$ ) of follow up, while there was also significant difference in Paraesthesia and numbness in the preserved group as compared to non-preserved group of ICBN.

In 2007, Ivanovic, et al [24] studied the implications of the section of the neurovascular elements passing through the dissected tissue (ICBN) in conventional axillary dissection in breast cancer surgery. It was a prospective study in which 126 patients undergoing axillary node clearance for breast cancer of stages I and II were randomly selected for preservation of ICBN. Sensory deficit, pain were examined in the first two weeks after the surgery. No difference in the number of dissected nodes was seen between the two groups ( $p = 0.7$ ). The loss of sensitivity was significantly less common in the group randomized for ICBN preservation (16/65 vs. 30/61,  $p < 0.005$ ), while there was no difference in the pain intensity and duration (49/65 vs. 44/61,  $p > 0.05$ ). In our study there was significant decrease in pain in preserved group of ICBN after 6 month versus nonpreserved group of ICBN ( $p < 0.001$ ) whereas at 1 month all patients (both preserved and non preserved ICBN) had no numbness and paraesthesias ( $p = 1.00$ ). However at 6 months there is significant decrease in both numbness and paraesthesias ( $p < 0.001$ ) in the preserved group of ICBN.

Later on, Satyajeet et al [18] did retrospective study in 2011 to evaluate the role of preservation of the intercostobrachial nerve and post-mastectomy pain syndrome and also to evaluate various anatomical variations of the intercostobrachial nerve. Forty-two patients were included into the ICB nerve preservation group A. In Group B, 27 patients were included where this nerve was sectioned. In all the cases, it was tried to identify the nerve and its course at the best to assess various variations. The subjective and objective pain evaluations were performed on the 2nd day, after 1 month and after 3 months post-operatively. After 3 months, 76.2% of the patients were asymptomatic in Group A (ICB nerve preservation group) and 51.9% in the nerve section group (Group B) ( $p < .01$ ). Although there was a slight increase in the total time of surgery in group A, it was not significant ( $p = 0.62$ ).

In our study, we have also found the significant decrease in pain, numbness and paraesthesias after the 6 months in preserved group of ICBN; however we find five minutes increase in duration of surgery of preserved ICBN as compared with non preserved group of ICBN. However, we have noted all the six anatomical variants of intercostobrachial nerve as per Cunnick [17].

Our study shows that the morbidity resulting from division of the ICBN during axillary surgery is significant. Preserving ICBN significantly reduces Paraesthesia, numbness and pain. There is a marginal difference in the duration of surgery in preserving the ICBN. This study also demonstrates the various anatomical variants of ICBN.

The operating surgeon should be aware of these various anatomical variants of the ICBN while operating so that there are less chances of sacrifice of ICBN. Thus it should be a routine practice to preserve the ICBN at the time of axillary surgery as it significantly

reduces the patient's morbidity and improves the quality of life.

## References

- Halstead WS. The results of operations for the cure of cancer of the breast performed at The Johns Hopkins Hospital from June 1889. Johns Hopkins Hospital Rep. 1894-1895; 4: 297-350.
- Tasmuth T, et al. Pain and other symptoms after different treatment modalities of breast cancer. *Annals of Oncology*. 1995; 6: 453-459.
- Tasmuth T, Estlanderb A, Kalso E. Effect of present pain and mood on the memory of past postoperative pain in women treated surgically for breast cancer. *Pain*. 1996; 68: 343-347.
- Akechi T, et al. Biomedical and psychosocial determinants of psychiatric morbidity among postoperative ambulatory breast cancer patients. *Breast Cancer Research and Treatment*. 2001; 65: 195-202.
- Abdullah TI, Iddon J, Barr L, Baildam AD, Bundred NJ. Prospective randomized controlled trial of preservation of the intercostobrachial nerve during axillary node clearance for breast cancer. *Br J Surg*. 1998; 85: 1443-1445.
- Lin PP, Alison DC, Wainstock J, et al. Impact of axillary lymph node dissection on the therapy of breast cancer patients. *J Clin Oncol*. 1993; 11: 1536-1544.
- Kissn MW, Della Rovere QG, Easton D, Westbury G. Risk of lymphadema following the treatment of breast cancer. *Br. J. Surg*. 1986; 73: 580-584.
- Carpenter JS, Sloan P, Andrykowski M A, et al. Risk factors for pain after mastectomy / lumpectomy. *Cancer Practice*. 1999; 7: 66-70.
- Aitken DR, Minton JP. Complications associated with mastectomy. *Surg Clin North Am*. 1983; 63: 1331-1352.
- Ivens D, Hoe AL, Podd CR, et al. Assessment of morbidity from complete axillary dissection. *Br J cancer*. 1992; 66: 136-138.
- Kissn MW, Della Rovere QG, Easton D, Westbury G. Risk of lymphoedema following the treatment of breast cancer. *Br J Surg*. 1986; 73: 580-584.
- Keramopoulos A, Tsionou C, Minaretzis D, et al. Arm morbidity following treatment of breast cancer with total axillary dissection: A multivariate approach. *Oncology*. 1993; 50: 445-449.
- Assa J. The intercostobrachial nerve in radical mastectomy. *J Surg Oncol*. 1974; 6: 123-126.
- Teicher I, Pouland B, Wise L. Preservation of the Intercostobrachial nerve during axillary dissection for carcinoma of the breast. *Surg Gynecol Obstet*. 1982; 155: 891-892.
- Temple WJ, Ketchum AS. Preservation of the intercostobrachial nerve during axillary dissection for breast cancer. *Am J Surg*. 1985; 150: 585-588.
- Maycock LA, Dillon P, Dixon JM. Morbidity related to intercostobrachial nerve damage following axillary surgery for breast cancer. *The breast*. 1998; 7: 209-212.
- Cunnick GH, Upponi S, Wishart GC. Anatomical variants of the intercostobrachial nerve countered during axillary dissection. *The Breast*. 2001; 10: 160-162.
- Verma S, Kala S, Bhargava R, et al. Evaluation of the role of preservation of the intercostobrachial nerve on the post-mastectomy pain syndrome in breast cancer patients of north India. *The internet J of surgery*. 2011; 23: 1.
- Latteri M, Bajardi G, La Nasa S, Spinnato G, Pantuso G, Fricano S. Technical note in oncological surgery: preservation of the ICBN in the course of axillary lymphadenectomy.
- Freeman SR, Washington SJ, Pritchard T, et al. Long term results of randomized prospective study of preservation of the intercostobrachial nerve. *Eur J Surg Oncol*. 2003; 29: 213-215.
- Torresan RZ, Cabello C, Conde DM, Brenelli HB. Impact of the preservation of the intercostobrachial nerve in axillary lymphadenectomy due to breast cancer. *The Breast*. 2003; 9: 389-392.
- Taylor KO. Morbidity associated with axillary surgery for breast cancer. *ANZ*

- J Surg. 2004; 74: 314-317.
23. Wei WD, Wang X, Rong TH, Huang ZF, Li BJ. Methods of preserving intercostobrachial nerve during breast cancer operation and its clinical value. Zhonghua Wai Ke Za Zhi. 2005; 43: 1136-1138.
24. Ivanovic N, Granic M, Randelovic T, Bilanovic D, Duakanovic B, Ristic N, et al. Functional effects of preserving the intercostobrachial nerve and the lateral thoracic vein during axillary dissection in breast cancer conservative surgery. Vojnosanit Pregi. 2007; 64: 195-198.