

## Case Series

# Airway Management of Granuloma Post Intubation: 2 Cases Report

Walid Atmani\*; Ayoub Boubekri; Abdelhamid Jaafari;  
Abdelouahed Baite; Mustapha Bensghir  
Pole Anesthésie-Réanimation Hôpital Militaire  
d'Instruction Mohamed V Rabat, Morocco

\*Corresponding author: Walid Atmani  
Pole Anesthésie-Réanimation Hôpital Militaire  
d'Instruction Mohamed V Rabat, Morocco.  
Email: atmani.walid@gmail.com

Received: May 08, 2023

Accepted: June 03, 2023

Published: June 10, 2023

## Abstract

Tracheal intubation is a common procedure during General Anesthesia. It consists in introducing a probe into the trachea. This simple act remains not without risks. Various incidents and complications have been described due to this procedure. Among these is granulomas. Different factors and mechanisms are responsible for these complications. The prolongation of the intubation especially in intensive care remains the main causative factor of the development of granulomas, on the other hand this complication remains infrequent in anesthesia. The main clinical signs are dyspnea or a change in voice. Surgery is often required. Through two clinical cases of granulomas developed after surgery, the authors discuss the mechanisms and requirements for anesthetic management of this type of complication.

**Keywords:** Anesthesia; Tracheal intubation; Dyspnea; Granuloma; Surgery

## Introduction

Tracheal intubation is an undissociated act of general anesthesia, and consists of the introduction of a probe in the trachea to ensure respiration and ventilation in a patient freed up in apnea. The frequency of laryngeal lesions after translaryngeal intubation differs in published studies. The pathophysiology of these lesions includes mucosal ischemia and other unclear factors. Post-extubation dyspnea uncommonly results from laryngeal edema; edema may result from lesions of laryngeal mucosa [1].

Moreover, this gesture sometimes does not remain trivial, and burdened with complications that can be immediate as dyspnea, dysphagia or late-onset type of granuloma, [2] making any other intubation difficult and the management of the upper airway impossible because of laryngeal obstruction. Indeed, granulomas, trachomalacia, oeso-tracheal fistula... are frequent complications, seen especially in case of prolonged intubation [3,4] in patients in intensive care but rarely in case of general anesthesia for a gesture more or less fast.

We describe the clinical observation of two post-intubation granuloma cases in two patients with upper airway management measures.

## Observations

### Patient 1:

**Patient and observation:** A 34-year-old female patient was admitted to the ear, nose and throat clinic with shortness of

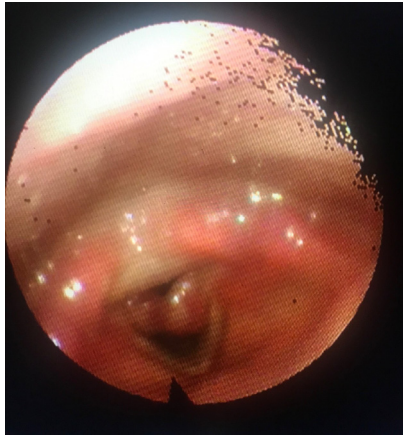breath and dysphonia lasting for 2 months, her personal history revealed total thyroidectomy 2 months ago. No dyspnea or history of alcoholism, smoking associated; no trismus or other symptom noted.

The last surgery had lasted 2 hours, intubation was difficult 2 temptations with guide support and had performed by endotracheal army tube n°7mm, intubation and anesthesia had been completed without complications

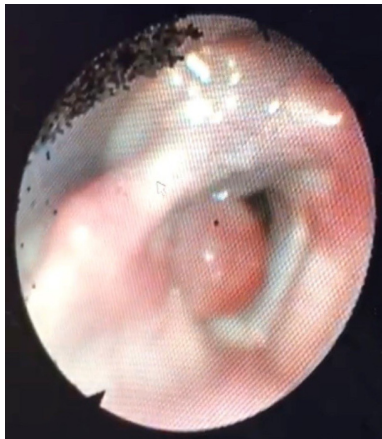
**Diagnosis:** Echo-endoscopic exploration showed two rounded formations arising on both sides of the vocal cords with obstruction of 2/3 of tracheal light Figure 1 surgical indication was posed and consist on microlaryngeal surgery under general anesthesia

**Clinical findings:** Pre-anesthetic evaluation found a patient ASA 1 in good health, Mallampati III; cardiac and respiratory evaluation without abnormality and thyroid status is normal. The obstruction of the glottic lumen posed a problem of the management of the airways necessitating the patient's consent for a possible tracheotomy in case of impossible mask ventilation.

**Follow-up and outcome of interventions:** The patient underwent standard monitoring and perfusion of fluid through and interavenous line, after checklist verification of difficult intubation equipment (laryngeal mask, Eshmann guide, armed probe of different size 4-6mm) plus tracheotomy table for emergency.



**Figure 1:** Two rounded granulomas arising on both sides of the vocal cords with obstruction of 2/3 of tracheal light.



**Figure 2:** Sessile laryngeal granuloma originating in the right vocal cord with obstruction of the half of the tracheal orifice.

Induction of anesthesia, of whom the body weight was 68Kg, was performed with injection of fentanyl 3µg/kg, propofol 3mg/kg, after verification of effective mask ventilation but difficult in relation to resistance, curarization ensured by rocuronium 0.6mg/kg.

Due to the difficulty of airway management, videolaryngoscope (Mcgrath) used in first line which inable the visualization of the tracheal opening with two granulomas completely masking the tracheal lumen. Intubation is provided by probe n°5 mm army finely passing through the two non-depressible, pedunculated and tissue-like granulomas

After verification of an effective ventilation, Maintenance of anesthesia was performed by sevoflurane 1,5%; in addition, the patient received 120mg of solumedrol and 10mg of metoclopramide. The Hemodynamic statut was stable during the operation without episodes of hypotension or neosineprine injection.

Surgical procedure allowed complete excision in an operation that lasted 30 min Patient then admitted to post interventional surveillance room decurarized by neostigmine and extubated without incident. The SPO2 was at 99% in ambient air without dyspnea nor dysphonia

**Patient 2**

**Patient and observation:** 57-year-old patient with an appendectomy history about 15 years ago, cholecystectomy 5 years ago and a colectomy 2 months ago; admitted to the Ear Nose Throat clinic for dysphonia and hoarsness aggravation 1 month after the last surgery.

In fact, there were no clinical information about the appendectomy, in contrario the cholecystectomy lasted 95 min without complications. Intubation was difficult and was performed by endotracheal tube 7mm and the anesthesia was completed without abnormalities. The last one (colectomy) lasted more than 3h hours with hemodynamic variations including use of vasopressure support with ephedrine and transfusion, the intubation was performed by endotracheal tube 7,5mm. The anesthesia had completed without complications except several hypotension episodes successfully managed by vasopressors.

**Diagnosis:** The endoscopic examination found a sessile laryngeal granuloma originating in the right vocal cord with obstruction of the half of the tracheal orifice, otherwise no history of alcoholic smoking or associated trismus (Figure 2).

**Clinical findings:** Pre-anesthetic evaluation found a patient ASA 1 in good health, Mallampati III cardiac and respiratory evaluation without abnormality. The obstruction of the glottic lumen posed a problem of the management of the airways, like the first case, necessitating the patient's consent for a possible tracheotomy in case of impossible mask ventilation.

**Follow-up and outcome of interventions:** After admission to the operating room, checklist of difficult intubation equipment (laryngeal mask, Eshmann guide, armed probe of different size 4-6mm) plus tracheotomy table for emergency airway management.

The anesthetic induction after standard monitoring and fluid replacement through intravenous line with fentanyl 3µg/kg, propofol 3mg/kg, after verification of effective mask ventilation, curarization ensured by rocuronium 0.6mg/kg.

Given the difficulty of airway management, first-line videolaryngoscope (McGrath) used to visualize the tracheal opening and then we noticed a right granuloma almost completely obscuring the tracheal light Intubation is provided by probe n°5.5 army passing finely below the granuloma with bleeding on contact, given the difficulty of glottic exposure in a patient cormack IV intubation is accompanied by mobility of the incisor during intubation.

After verification of an effective ventilation, surgical procedure allowed complete excision. Patient then admitted to post interventional room decurarized by neostigmine and extubated without incident, SPO2 was 97% in ambient air without dyspnea nor dysphonia, except that the patient lost the two incisor during suspended direct laryngectomy.

**Discussion**

Orotracheal intubation is a common act in anesthesia and condition to a prior assessment of ventilation. it's performed in the majority of cases without incident. the occurrence of complications is frequent associated with difficult intubation.

The earliest report of laryngeal granuloma was submitted by Clausen in 1932 [5], Since that time, it is well known that prolonged endotracheal intubation may result in development of laryngeal granuloma. But laryngeal granuloma caused by short-term intubation has not been reported. We encountered a laryngeal granuloma growing by endotracheal intubation for 4.5h. Furthermore, the otologist declares that patients suffering from laryngogranuloma visit the department every 2 months. The occurrence rate of laryngeal granuloma was reported to be ranging from 0.01% to 3.5% [6]. There are many etiologic factors :the trauma of intubation, infection, the use of oversized

tube, excessive cuff pressure in the presence of nitrous oxide, the duration of intubation, and the positioning of endotracheal tube [7-9]. Predisposing factors reinforces age, gender, anatomic character, fragility of the laryngotracheal mucosa, and hyperacidity with gastric reflux; Women are more likely to develop granulomas, as is a patient who is obese, has a short neck, or possesses other congenital anomalies involving the airway [10]. Prevention primarily involves avoiding or eliminating the etiologic factors. To reduce the incidence of the postintubation complications, there are many means: atraumatic intubation under direct vision during laryngoscopy, use of smaller endotracheal tubes, attention to cuff pressure, prevention of excessive flexion or extension of the neck, and the use of muscle relaxants or adequate depth of anesthesia to avoid reflexive movements around the tube [11-13]. Treatment consists of strict voice rest, cessation of smoking, corticosteroids, antibiotics, antacids, and surgical removal under direct laryngoscopy. However, some laryngeal granulomas are highly refractory to standard therapies [14]. For these persistent or recurrent granulomas, repeated excision followed by low-dose irradiation may provide successful resolution [15]. Most anesthesiologists recognize that hoarseness often is a postintubation complication. Few anesthesiologists, however, realize that developed postintubation laryngogranuloma may cause dyspnea that leads to emergency surgical excision. The sign of growing granuloma is hoarseness. Difficult vocalization, dyspnea, and pharyngodynia appear a few weeks or a few months after surgery. Patients should be informed of the risk of laryngogranuloma and its signs and symptoms and should be instructed to visit an otorhinolaryngologist if they experience postintubation hoarseness for more than 1 week.

The recurrence rate of intubation granulomas renders the treatment of these lesions challenging. As we could verify in this review, few studies approach this topic with rigorous methodology and in many the information is incomplete and often the number of patients is small.

Analyzing the studies selected in this review, females (76%) and adults predominate, corroborating the findings of other authors [16]. Even in post-intubation granulomas, gastro-esophageal reflux is an important predisposing factor, and its treatment is the main clinical treatment indicated in the studies here listed. Gastro-eosophagal-reflux disease is certainly a deleterious factor to the epithelization of the laryngeal mucosa damaged by intubation [17]. Injuries to the laryngeal mucosa caused by exposure to gastric juice have been described for decades as well as the benefits of treatment with proton pump inhibitors in improving vocal symptoms and laryngeal lesions in patients with acid laryngitis. Proton pump inhibitors have been advocated in laryngeal granulomas, regardless of the etiology of the lesion [18].

Vocal overuse is another factor predisposing to the formation of post intubation granulomas, as observed in two studies of this review, that included five patients. Exaggerated phonation causes traumatic collision of the vocal folds, resulting in lesions of the arytenoid epithelium and delayed tissue healing [19].

Choosing the ideal treatment for post-intubation granulomas has been a constant challenge for many specialists. Drug treatment alone is lengthy, therefore demotivating. According to Koufman, granuloma resolution with clinical treatment may take from six to eight months. Surgical treatment is faster, but involves anesthetic risks, local scars and recurrence, often being

reserved for intractable cases. Even after surgery, clinical treatment is almost always initiated in order to reduce relapses, which can occur in 40-90% [20].

Our observations have raised the problem of managing airways in case of laryngeal obstruction by granuloma, in this case the ideal is the use of jet ventilation for respiratory management or intubation in spontaneous ventilation as described in previous observation while preparing an emergency tracheotomy tray. A case report describing a worse scenario of intubation; The patient's symptoms developed following general anaesthesia for dental extractions. Based on the clinical course of increasing frequency and duration of hoarseness, it was reasonable to presume that she had post-intubation granuloma. In this case, the location of the tumour changed after manual ventilation, becoming partially lodged in the glottis by the positive pressure ventilation. Therefore, ideally, awake or semi-awake intubation should have been performed. In cases with large or malignant tumours that can obstruct the glottis and trachea, tracheotomy can be performed, but the tumour was benign and relatively small in size in this case; therefore, we did not select tracheotomy as an airway management strategy. Also, tracheotomy is contraindicated in cases of laryngeal papilloma caused by human papillomavirus, which could not be ruled out preoperatively in this case [20].

### Conclusion

several risk factors are associated with post-intubation tracheal injuries; as we can note the majority of the cases are women with more than 70% in the literature, without also forgetting the inflation pressure of the balloon and as well as the size of the probe, these are modifiable factors simple to manage and which can be useful for a better prognosis.

### Author Statements

#### Competing Interests

authors do not declare any conflict of interest.

#### Authors Contributions

All the authors participated in this work, read and approved the final version of the manuscript.

### References

1. Lambert P, Delorme N. Complications laryngées aiguës de l'intubation translaryngée: revue de la littérature Delorme Service des maladies respiratoires et réanimation respiratoire. Réanimation. 2002; 11: 59-65.
2. Blanc VF, Tremblay NAG. The complication of tracheal intubation: a new classification with a review of the literature. Anesth Analg. 1974; 53: 202-13.
3. Lindholm CE. Prolonged endotracheal intubation. Acta Anesth Scand. 1969; 33: 1-131.
4. Bishop MJ, Weymuller EA, Fink BR. Laryngeal effect of prolonged intubation. Anesth Analg. 1984; 63: 335-42.
5. Clausen RJ. Unusual sequela of tracheal intubation. Proc R Soc Med. 1932; 25: 1507.
6. Balestrieri F, Watson CB. Intubation granuloma. Otolaryngol Clin North Am. 1982; 15:567-79.
7. Feder RJ, Michell MJ. Hyperfunctional, hyperacidic, and intubation granulomas. Arch Otolaryngol. 1984; 110: 582-4.

8. Kastanos N, Miro RE, Perez AM, Mir AX, Vidal AA. Laryngotracheal injury due to endotracheal intubation: Incidence, evolution and predisposing factors. A prospective long-term study. *Crit Care Med.* 1983; 11: 362-7
9. Ward PH, Zwitman D, Hanson D, Berci G. Contact ulcers and granulomas of the larynx: New insights into their etiology as a basis for more rational treatment. *Otolaryngol Head Neck Surg.* 1980; 88: 262-9.
10. Blanc V, Tremblay N. The complications of tracheal intubation: A new classification with a review of the literature. *Anesth Analg.* 1974; 53: 202-13.
11. Bishop M, Weymuller E, Fink B. Laryngeal effects of prolonged intubation. *Anesth Analg.* 1984; 63: 335-42.
12. Barton R. Medicolegal aspects of intubation granuloma. *JAMA.* 1958; 166: 1821-3.
13. Snow J, Harano M, Balogh K. Postintubation granuloma of the larynx. *Anesth Analg.* 1966; 48: 425-8.
14. Harari PM, Blatchford SJ, Coulthard SW, Cassidy JR. Intubation granuloma of the larynx: Successful eradication with low-dose radiotherapy. *Head Neck.* 1991; 13: 230-3.
15. de Lima Pontes PAL, De Biase NG, Gadelha MC. Clinical evolution of laryngeal granulomas: treatment and prognosis. *Laryngoscope.* 1999; 102: 289-94.
16. Martins RH, Braz JR, Dias NH, Castilho EC, Braz LG, et al. Roarseness after tracheal intubation. *Rev Bras Anesthesiol.* 2006; 56: 189-99.
17. Böttcher A, Mencke T, Zitzmann A, Knecht R, Jowett N, et al. Laryngeal injuries following endotracheal intubation in ENT surgery: predictive value of anatomical scores. *Eur Arch Otorhinolaryngol.* 2014; 271: 345-52.
18. Roh HJ, Goh EK, Chon KM, Wang SG. Topical inhalant steroid (budesonide, Pulmicort nasal) therapy in intubation granuloma. *J Laryngol Otol.* 1999; 113: 427-32.
19. Hirano S, Kojima H, Tateya I, Ito J. Fiberoptic laryngeal surgery for vocal process granuloma. *Ann Otol Rhinol Laryngol.* 2002; 111: 789-93.
20. Derkay CS, Wiatrak B. Recurrent respiratory papillomatosis: a review. *Laryngoscope.* 2008, 118: 1236-1247.