

## Case Report

# Neurogenic Bradycardia in Perioperative of Neurosurgery: A Dreadful Complication 2 Cases and Literature Review

Masad Ilyass\*, Abouelalaa KH, Elbouti AN, Fakri AH, Elwali AB and Bensghir MU

Department of Anesthesiology and Intensive Care, Military Hospital Mohammed V, Faculty of Medicine and Pharmacy of Rabat, Mohammed V University, Rabat, Morocco.

\*Corresponding author: MASAD Ilyass

Department of Anesthesiology and Intensive Care, Military Hospital Mohammed V, Faculty of Medicine and Pharmacy of Rabat, Mohammed V University, Rabat, Morocco.

Received: November 24, 2022; Accepted: January 20, 2023; Published: January 27, 2023

## Abstract

Neurogenic bradycardia which can lead to cardiac arrest is a rare, but well-recognized complication of anesthesia.

We report the cases of two patients admitted for craniotomy who presented intraoperative bradycardia due to TrigeminoCardiac Reflex and Hypothalamic stimulation immediately reversible after cessation of stimulation.

The importance of having the knowledge, vigilance, equipment and skills to quickly deal with such a case will be critical to the survival of the patient.

**Keywords:** Neurogenic bradycardia; Craniotomy; Trigemino Cardiac Reflex; Hypothalamic stimulation

## Introduction

Today, patients safety is an important pillar of patients care, advances in therapeutics, management guidelines, and technological devices and close monitoring allowed to detect, and quickly treat cardiac arrest and peri arrest arrhythmias.

Neurogenic bradycardia which can lead to cardiac arrest is a rare, but well-recognized complication of anesthesia.

We report the cases of two patients admitted for craniotomy who presented intraoperative bradycardia.

### Case 1

A 40-year-old patient, weighing 65 kg, was admitted to the neurosurgery department for occipital headache accompanied by vomiting and reduced visual acuity that had progressed in the past 9 months. He had no specific history nor had any comorbidities. All the requested radiological and biological assessments that were carried out were within normal limits. The patient was diagnosed on MRI with a dermoid cyst in the magna cistern displacing the fourth ventricle; therefore, a retro mastoid suboccipital craniotomy and tumor excision were planned.

After admission to the operating room, we proceeded with the induction with 200 µg intravenous Fentanyl and 160 mg Propofol. Orotracheal intubation was facilitated by the administration of 100 mg of rocuronium intravenously.

The anesthesia was maintained with sevoflurane in a mixture of oxygen and nitrous oxide (50/50) as well as with intermittent boluses of fentanyl 1 µg / kg and rocuronium 0.2 mg / kg depending on the needs. The patient was placed prone and the operation started.

After 90 minutes the Anesthesiologist and the nurse were alerted by sudden asystole without any prior prodrome which spontaneously resolved followed by a transient episode of bradycardia which occurred which also resolved spontaneously. 8 minutes later, a second episode of bradycardia occurred and was complicated by a new asystole. The neurosurgeon was notified and 0.5 mg of atropine was administered intravenously. The heart rate has returned tonormal. Mean arterial pressure (MAP) dropped from 80 to 50 mm Hg. A bolus of neosynephrine (3 mg) was given. The mean arterial pressure increased to 85 mm Hg and tumor dissection was resumed. Another episode of sudden asystole

occurred four minutes later and Heart rate increased after stopping the stimulus. The bradycardia stopped with the surgical stimuli stopping, indicating that the surgical manipulation of the brain was the probable cause. After this event, it was decided to end the operation and resume it later. The operation continued afterwards and took place without significant incidents. The patient was subsequently transferred to intensive care for postoperative monitoring and he was extubated

without any incident 8 hours later and he returned to the ward after an 18-hour stay in intensive care.

## Case 2

A 45-year-old patient was admitted to the neurosurgery department for a reduced unilateral vision in her right eye evolving for more than 4 months. Magnetic resonance imaging revealed a homogeneous mass of 2 × 2 cm over the suprasellar region. The patient was diagnosed with suprasellar meningioma and a bi-frontal craniotomy with tumor excision was planned in a supine position.

All preoperative examinations, including the EKG and Chest X-Ray, were normal. On the day of the operation, the patient was pre-medicated with 0.2 mg of glycopyrrolate intramuscularly one hour before the operation. Routine monitors have been set up. The basal heart rate was 78 bpm and the blood pressure was 130/80 mmHg. General anesthesia was induced with fentanyl 2 µg/kg, propofol 1.5 mg/kg and tracheal intubation was facilitated with rocuronium 1 mg/kg. The trachea was intubated using a 7.5 mm cuff portex endotracheal tube. Anesthesia was maintained with sevoflurane in a mixture of oxygen and nitrous oxide (50:50) and intermittent boluses of fentanyl and vecuronium as needed. Dexmedetomidine was also administered just before the incision (1 bolus of µg/kg over 10 min followed by an infusion of 0.4-0.5 µg/kg/min). Invasive intraoperative monitoring was established and included central venous pressure and arterial pressure, using the right femoral vein and left artery, respectively. The patient was maintained at a mean arterial pressure of 65-70 mmHg.

During retro chiasmatic dissection, a sudden severe bradycardia (30 beats/min) with hypotension (mean arterial pressure 50 mmHg) occurred. The surgeon was immediately informed. After removing the stimulus, the heart rate and blood pressure returned to normal. These transient hemodynamic disturbances occurred twice. No pharmacological intervention was performed. After this excision cardiac event, the operation took place without any other incident.

The patient was transferred to the intensive care unit for elective ventilation. The next day, the trachea was extubated while the patient was fully conscious and following orders.

## Discussion

Because of its high degree of complexity, neurosurgery is considered high-risk surgery, and improving patient outcomes has always been a primary focus of the specialty's research. On the other hand, The need for a systematic strategy to increase patient safety and lowering adverse events has just lately been recognized as a necessity [1].

Cardiac pathology, hypoxia, insufficient anesthesia, the use of agents such as β-blockers, α2-agonists, strong narcotics and other anesthetic drugs can all lead to bradycardia or asystole during an ongoing operation. Asystole can also be produced by paradoxical cardiovascular reflexes [2].

These reactions can also be caused by activation of the trigeminal cardioreflex (TCR) due to direct stimulation of the trigeminal nerve or its branches in the duramater or the cerebellar tentorium [3]. The trigeminal nerve and the cardioinhibitory vagus nerve constitute the afferent and efferent pathways of the reflex arc. Sudden asystole occurs regardless of the pressure exerted on the brainstem during posterior fossa surgery which remains the only explanation in our case.

TrigeminoCardiac Reflex is a recognized physiological reflex, causing circulation and cardiac events (Bradycardia, hypotension, or asystole) in neurosurgery, ophthalmic and Ears Nose and Throat Surgery [4,5].

It was described for the first time by the Italian Bernard Ascher and Giuseppe Dagnini. It was first described as the oculo-cardiac effect (OCR) as it was known to only affect the ophthalmic branch of the Trigeminal Nerve but the terminology was changed to TCR.

The mechanism of TCR is not completely elucidated, but the current evidence shows that the TCR is as a result of the direct or indirect stimulation (mechanical, stretching, thermal, electrical) of the trigeminal nerve or its branches. The arc starts by the confluence of all the endings of the trigeminal nerve to the Gasserian ganglion, then to the sensory nucleus of CN V in the Pons. These neurons will then join the motor nucleus of the vagus nerve from which the cardioinhibitory fibers will arise and terminate in the heart. The activation of the reflex causes a negative chronotropic and inotropic response inducing the bradycardia and the hypotension [6].

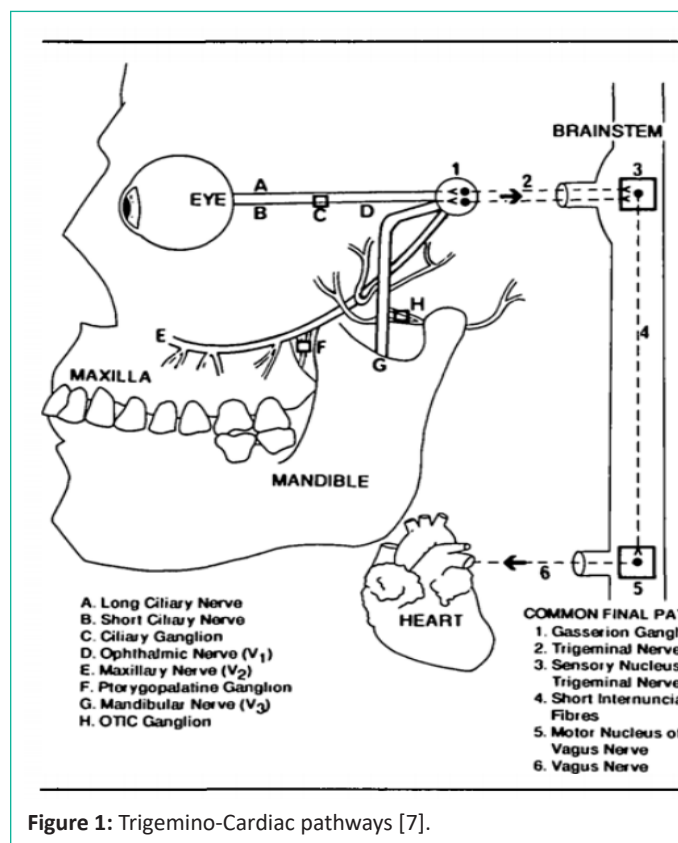


Figure 1: Trigemino-Cardiac pathways [7].

Several risk factors are associated with the occurrence of the TCR, including age, hypercapnia, hypoxemia and the anesthesia [7]. With this

regard, the best-known anesthetic drug responsible for TCR is Fentanyl in the young population, however Propofol, as a commonly used anesthetic, is not fully evaluated in TCR and this study showed also that there is a statistical difference between patients, who previously had an infarctus and those who did not, as TCR was more frequent in the population with previous cardiac infarctus [8]. A study from A. Koerbel et al. described a series of 200 patients admitted for skull base surgery in which 8% (16 patients) had a TCR with no impact on the mortality [9]. This showed that the TCR can be a common event in neuro-logical surgery, due to the diverse surgical approaches near the trigeminal nerve. However, stopping surgical stimulation was

sufficient to reestablish HR and blood pressure to normal levels, thus CPR is rarely required [6]. Another case report showed the use of anticholinergic drugs to increase the heart rate [10]. This is why it is important to closely monitor hemodynamic parameters, and detect the occurrence of the TCR and act accordingly. Moreover, studies about the postoperative consequences of TCR did not report any postoperative clinical consequences [11].

Hypothalamic stimulation is responsible for the production of a wide range of dysfunctions of the cardiovascular system. Since the hypothalamus is located in close proximity in the suprasellar compartment, it is likely that it produces such an event in this patient. A similar hemodynamic event has been reported with hydrogen peroxide irrigation in craniopharyngioma surgery. The anterior hypothalamus participates in the baroreflex regulation of the heart rate by modifying the parasympathetic tone but without affecting the activity of the cardiac sympathetic nerve. The stimulus from the anterior hypothalamus therefore probably contributed to severe bradycardia and hypotension in our patient.

Hypothalamic stimulation was also described in the literature as causing cardiac arrhythmias including asystole. A study by Attar et al. showed that stimulation of anterior hypothalamus resulted in bradycardia, and the stimulation of lateral and posterior hypothalamus resulted in transient premature beats and a Auriculo-Ventricular dissociation [12].

A Case study by Girija et al. described a case of a transient asystole in a patient with no history of associated cardiac disease, who underwent a transsphenoidal pituitary surgery [13].

Amygdaloid complex stimulation and other manipulations were also associated with hemodynamic disturbances; this concerns different parts (Insular Cortical, Limb). Kumar et al. described 3 cases of severe bradycardia and asystole occurring in patients undergoing anterior temporal lobectomy and amygdalo-hippocampectomy for the treatment of epilepsy [14]. However as with other surgical simulations, stopping the stimuli resolved the case. Vagal stimulation was also described to cause hemodynamic and cardiac complications [15]. Some cases of CA caused by glossopharyngeal vagal reflexes were described in the posterior fossa surgery [14]. With the removal of the surgical stimulus, bradycardia usually improves and pharmacological treatment is not necessary, with direct manipulation of the brainstem. The drugs given may mask the signs of brainstem manipulation and permanently damage the cranial nerve nuclei. The ability to predict the risk of asystole can better prepare the anesthesia team to anticipate, identify and manage an episode. The importance of having the knowledge, vigilance, equipment and skills to quickly deal with such a case will be critical to the survival of the patient [16].

## Conclusion

Efforts were made during the last years to promote patients' safety and to train medical teams to detect and treat cardiac arrest.

However, evidence is rare when dealing with neurosurgical patients, and more efforts are needed in understanding the etiologies, mechanisms and the specificities of its management.

## References

1. Han SJ, Rolston JD, Lau CY, Berger MS. Improving Patient Safety in Neurologic Surgery. *Neurosurg Clin N Am*. 2015; 26: 143-147.
2. Kinsella SM, Tuckey JP. Perioperative bradycardia and asystole: relationship to vasovagal syncope and the Bezold-Jarisch reflex. *Br J Anaesth*. 2001; 86: 859-868.
3. Goyal K, Philip FA, Rath GP, Mahajan C, Sujatha M, et al. Asystole during posterior fossa surgery: Report of two cases. *Asian J Neurosurg*. 2012; 7: 87.
4. Brown JA, Preul MC. Trigeminal depressor response during percutaneous microcompression of the trigeminal ganglion for trigeminal neuralgia. *Neurosurgery*. 1988; 23: 745-748.
5. Dominguez J, Lobato RD, Rivas JJ, Gargallo MC, Castells V, et al. Changes in systemic blood pressure and cardiac rhythm induced by therapeutic compression of the trigeminal ganglion. *Neurosurgery*. 1994; 34: 422-427.
6. Prabhu VC, Bamber NI, Shea JF, Jellish WS. Avoidance and management of trigeminocardiac reflex complicating awake craniotomy. *Clin Neurol Neurosurg*. 2008; 110: 1064-1067.
7. Meng Q, Yang Y, Zhou M, Li X. Trigemino-cardiac reflex-The trigeminal depressor responses during skull base surgery. *Clin Neurol Neurosurg*. 2008; 110: 662-666.
8. Meuwly C, Chowdhury T, Sandu N, Reck M, Erne P, et al. Anesthetic Influence on Occurrence and Treatment of the Trigemino-Cardiac Reflex. *Medicine (Baltimore)*. 2015; 94: e807.
9. Koerbel A, Gharabaghi A, Samii A, Gerganov V, von Gosseln H, et al. Trigemino-cardiac reflex during skull base surgery: mechanism and management. *Acta Neurochir (Wien)*. 2005; 147: 727-732.
10. Gomez TM, Van Gilder JW. Reflex bradycardia during TMJ arthroscopy: case report. *J Oral Maxillofac Surg*. 1991; 49: 543-544.
11. Campbell R, Rodrigo D, Cheung L. Asystole and bradycardia during maxillofacial surgery. *Anesth Prog*. 1994; 41: 13-16.
12. Attar HJ, Gutierrez MT, Bellet S, Ravens JR. Effect of Stimulation of Hypothalamus and Reticular Activating System on Production of Cardiac Arrhythmia. *Circ Res*. 1963; 12: 14-21.
13. Rath GP, Chaturvedi A, Chouhan RS, Prabhakar H. Transient Cardiac Asystole in Transsphenoidal Pituitary Surgery: A Case Report. *J Neurosurg Anesthesiol*. 2004; 16: 299-301.
14. Nagashima C, Sakaguchi A, Kamisasa A, Kawanuma S. Cardiovascular complications on upper vagal rootlet section for glossopharyngeal neuralgia; case report. *J Neurosurg*. 1976; 44: 248-253.
15. Sharma RR, Pawar SJ, Dev E, Chackochan EK, Suri N. Vagal schwannoma of the cerebello-medullary cistern presenting with hoarseness and intractable tinnitus: a rare case of intra-operative bradycardia and cardiac asystole. *J Clin Neurosci*. 2001; 8: 577-580.
16. Abraham M, Wadhawan M, Gupta V, Singh AK. Cardiopulmonary resuscitation in the lateral position: is it feasible during pediatric intracranial surgery? *Anesthesiology*. 2009; 110: 1185-1186.