

Case Report

Melorheostosis, A Rare Disease That Causes Chronic Pain: Efficacy of Pulsed Radiofrequency

Rodríguez-Navarro MA*, Alcaraz AB, Benitez M, Mula-Leal J, Padilla-Del Rey ML, Díaz C and Castillo JA

Department of Anesthesia and Pain Management, General University Hospital, José María Morales Meseguer, Murcia, Spain

*Corresponding author: Maria Angeles Rodríguez Navarro, Department of Anesthesia and Pain Management, General University Hospital, José María Morales Meseguer, Murcia, Spain

Received: May 27, 2020; Accepted: June 16, 2020;

Published: June 23, 2020

Abstract

Melorheostosis is an exceptionally rare sclerosing hyperostosis. Recent studies of melorheostosis indicate that most cases arise from somatic *MAP2K1* mutations, those cases are more likely to have the classic “dripping candle wax” appearance on radiographs. It has an incidence of 0.9 cases per million inhabitants and it is distributed equally between both sexes.

Why Melorheostosis is a syndrome that pain physician need to know? The presenting features of melorheostosis are variable, depending on the site and extent of the bone disease and whether there is any associated soft tissue involvement. Some cases are identified from incidental radiographic findings, but the most common syndrome there will be chronic pain. Despite this, there is no any publication in “pain management journals”.

In addition to drug treatment, which is in constant revision, we propose to apply Pulsed Radiofrequency of the nerves (PRF) to treat pain in melorheostosis based in the efficacy published.

We reported a case of 39-year-old male suffering 15 years of chronic hip pain because of Melorheostosis. The results of PRF of articular branches of femoral and obturator nerves have been very successful.

For radicular pain from spinal diseases, the evidence supports that PRF is an effective treatment. Similarly, PRF appears to be effective for post-herpetic neuralgia and occipital neuralgia. Nevertheless for others syndromes its effectiveness must be tested and even it is more necessary to communicate results in rare diseases as Melorheostosis which the number of treated patients is not very large.

Keywords: Melorheostosis; Melorheostosis; Pain Management; Hip Joint Pain; Pulsed Radiofrequency, Obturator and Femoral Nerves

Introduction

First described in 1922 as Leri’s disease, Melorheostosis is a rare sclerosing hyperostosis that typically affects the appendicular skeleton in a limited segmental fashion. It occasionally occurs on a background of another benign generalized sclerosing bone condition, known as osteopoikilosis caused by germline mutations in *LEMD3*, encoding the inner nuclear membrane protein MAN1, which modulates $TGF\beta$ /bone morphogenetic protein signaling. Recent studies of melorheostosis lesioned tissue indicate that most cases arise from somatic *MAP2K1* mutations, those cases are more likely to have the classic “dripping candle wax” appearance on radiographs. It has an incidence of 0.9 cases per million inhabitants and it is distributed equally between both sexes.

Why Melorheostosis is a syndrome that pain physician need to know? The presenting features of melorheostosis are variable, depending on the site and extent of the bone disease and whether there is any associated soft tissue involvement. Some cases are identified from incidental radiographic findings, but pain is the most common presenting concern (83%) [1,2].

Medical treatments have been tested include bisphosphonates,

but there is not a definitive guidance on their use because of the small number of patients. Surgical intervention may be required for those with large bone growths, nerve entrapments, joint impingement syndromes or major limb deformities. Bone regrowth is possible after surgery and recurrent contractures represent a major issue in those with extensive associated soft tissue involvement [1,3].

Today, Chronic Pain Units offer pulsed radiofrequency (PRF), a new method in the treatment of pain which can be applied in Melorheostosis. For example, PRF of the articular branches of the femoral and obturator nerves offers a treatment option of hip pain [4,5].

Case Report

A 39-year-old male was referred to the Pain Unit for persistent pain after total hip replacement. After 15 years of chronic pain and different ineffective pharmacological treatments, hip arthroscopy was performed that visualized areas of intra-articular bone growth that were removed. A postoperative radiology control showed different areas of these growing and a cortical thickening of the femur was noted (Figure 1). Analytics, including acute phase reactants, were normal. Bone scintigraphy shows tracer hypercaptation in the right

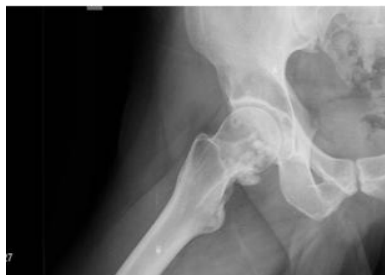

Figure 1A: Anteroposterior x-ray of the pelvis of the right hip: Post-surgical control of hip arthroscopy.

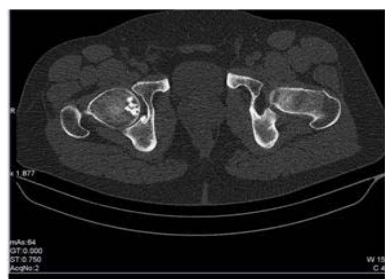


Figure 1B: CT scan, 3D reconstruction. Areas of subchondral sclerosis are observed in the head of the right femur with thickening of the inferior cortex and bone proliferation that has been reduced after surgery. Reviewing previous studies, it shows an involvement of the entire MID in the form of cortical thickening - undulating periostitis that affects the lower two thirds of the femur, on its medial face, and patched in the tibia (anterior region of the proximal and lateral diaphysis of the distal diaphysis), together with small intraosseous, sclerous lesions, such as those visible in the femoral head, which are located in the epiphyses of the distal femur, proximal tibia, and tibial pylon. The findings correspond to a melorheostosis (monomielic hyperostotic osteopathy).

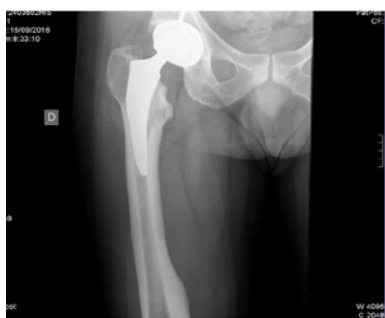

Figure 2: Post-surgical hip replacement rx control.

internal femoral cortex with bone cortex hypertrophy and proximal third of the right tibia compatible with Melorheostosis syndrome.

However, pain and mechanical impotence persisted and a total hip replacement was placed (Figure 2). After the second intervention, the patient continued with intermittent, oppressive pains, which improved with rest and exacerbated with mobilization, tingling sensation and cramps located in the external area of the thigh, groin and quadriceps.

On physical examination, limitation of passive and active joint mobility was detected, which was painful and increased to external and internal rotation. Also a non-mobile stone tumor in the lower

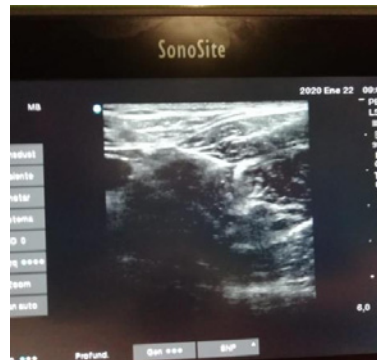

Figure 3: Obturator distal guided block with ultrasound echography.

third of the femur was detected. The maximum intensity of pain referred by the patient was 8 out of 10 on the Visual Analog Scale (VAS).

Given these findings, it was decided to perform a diagnostic-therapeutic block of the right obturator nerve and the femoral nerve with 10 ml of 0.25% levobupivacaine and 4 mg of dexamethasone, in each nerve, with marked improvement of the painful clinic during the two following months, referring the patient a maximum pain intensity of 3 over 8 on the analog visual scale. Due to the effectiveness of the block, 45 V Pulsed Radiofrequency (RF) was subsequently carried out in order to prolong the analgesia. We used two 20G radiofrequency needles 15 cm long and 10 mm active tip were used for 6 minutes (Figure 3). The patient was evaluated one month after the neuromodulative procedure and a decrease in pain of 2 out of 8 was observed in VAS.

Currently, the patient is 42 years old, pulsed radiofrequency of right femoral nerves and obturator is performed every 4-5 months that have improved their quality of life, pain and mobility. Occasionally, when clinically he exhibits muscular contractures, especially in iliopsoas, muscle block is also performed with local anesthetic and corticosteroid.

Discussion

The hip joint has a multiple sensory innervation from the sensory branches of the gluteal, femoral, obturator and sciatic nerves.

In our case, the patient reported more intense pain in the anterolateral face of the joint, so, given the suspicion of involvement of the sensitive territory innervated by the obturator nerve and resistance to pharmacological treatment, it was decided to perform a diagnostic nerve block of the nerve right shutter with local anesthetic [6].

Several ultrasound-guided obturator nerve block techniques are used to prevent thigh adductor jerk (during transurethral resection), provide analgesia for knee surgery, treat hip pain and improve hip adductor spasticity [7].

The anesthetic blockade and pulsed RF are performed on these nerves in order to produced enervation and block the painful impulse transmission [5].

Recently has been published a new review about whether PRF

is the appropriate option for managing the various peripheral neuropathic pain conditions. This review shows that PRF can be a beneficial treatment option without serious complications for some peripheral neuropathic pain disorders [5]. Few cases of complications have been described after its performance, although its blockage can occur as in any nerve block, neuropathy, infection, vascular puncture and even visceral puncture, for example bladder. In order to minimize these complications, in our case, it was decided to perform the guided block with ultrasound echography and a distal approach in which the anterior and posterior branches are blocked separately by two different needles toward the interfascial planes where each branch lies [7] (Figure 3).

Conclusion

Melorheostosis is a rare cause of hyperostosis osteopathy but in most cases it causes severe and disabling pain in a single, usually lower limb. Hence, it is important to think about it in order to reach an early diagnosis that allows it to be treated properly. Pulsed RF of the obturator and femoral nerves can be an effective treatment for the management of hip pain secondary to melorheostosis. However, it is not a hazard-free technique that must be carried out by trained personnel in its practice.

References

1. Smith GC, Pingree MJ, Freeman LA, Matsumoto JM, Howe BM, Kannas SN, et al. Melorheostosis: A Retrospective Clinical Analysis of 24 Patients at the Mayo Clinic. *PM R*. 2017; 9: 283-288.
2. Wordsworth P, Chan M. Melorheostosis and Osteopoikilosis: A Review of Clinical Features and Pathogenesis. *Calcified Tissue International*. 2019; 104: 530-543.
3. Salman TC, Rotés D, Blanch J, Bittermann V, Carbonell J. Melorheostosis: presentación de un caso y revisión de la literatura. *Reumatol Clin*. 2011; 7: 346-8.
4. Cortiñas- Saenz M, Salmerón G, Holgado IA. Bloqueo intraarticular y de ramas sensoriales de los nervios obturador y femoral en el cuadro de osteonecrosis y artrosis de cabeza femoral. *Revista Española de Cirugía Ortopédica y Traumatología*. 2013; 58: 319-324.
5. Cheol Chang M. Efficacy of Pulsed Radiofrequency Stimulation in Patients with Peripheral Neuropathic Pain: A Narrative Review. *Pain Physician*. 2018; 21: E225-E234.
6. Chye CL, Liang CHL, Lu K, Chen YW, Liliang PCH. Pulsed radiofrequency treatment of articular branches of femoral and obturator nerves for chronic hip pain. *Clinical Interventions in Aging*. 2015; 10: 569-574.
7. Yoshida T, Nakamoto T, Kamibayashi T. Ultrasound-Guided Obturator Nerve Block: A Focused Review on Anatomy and Updated Techniques. *Biomed Res Int*. 2017; 2017: 7023750.