

Case Report

Rescue Therapy by Intralipid in Covid-19 Pulmonary Complications: A Novel Approach

Javid MJ^{1*} and Zebardast J²

¹Department of Anesthesiology, Farabi Hospital, Tehran University of Medical Sciences, Iran

²PH. D Candidate of Cognitive Neuroscience Institute for Cognitive Science Studies (ICSS), Tehran, Iran

*Corresponding author: Mihan J Javid, MD, Department of Anesthesiology, Farabi Hospital, Tehran University of Medical Sciences, Iran

Received: April 26, 2020; Accepted: May 15, 2020;

Published: May 22, 2020

Abstract

Objectives: Covid-19 lung involvement is accompanied by morbidity and mortality. There is no efficient drug for treatment of progressive lethal pulmonary invasion of Covid19.

Based on unsuccessful results of antiviral medications in the treatment of pulmonary dysfunction, different pathophysiology of pulmonary infiltration should be in mind.

Based on hypothesis of progressive blockade of cardiopulmonary system by viral aggregation we are proposing Intralipid infusion for strenuous cleansing the cardiopulmonary system of Covid19 colonization.

This article is aimed to report a case of Covid-19 with severe pulmonary involvement. Pulmonary dysfunction subsided obviously after 48 hours of initiation of Intralipid infusion.

Results: In our case, pulmonary dysfunction subsided obviously after 48 hours of initiation of intralipid infusion and obvious improved O₂ saturation was observed.

We believe that the probable cause of death is disseminated cardiopulmonary involvement by viral load and viral intoxication. Based on this attitude Intralipid is recommended for rescue therapy in Covid-19 pulmonary involvement.

Keywords: Covid-19; Intralipid Rescue Therapy; Pulmonary Dysfunction; Packed Cell; Toxication

Abbreviations

GCS: Glasgow Coma Scale; CT: Computed Tomography

Introduction

It seems that treatment of pneumonia by focusing on antiviral drugs, is kind of misconception. In fact, the cardiopulmonary system is involved with a viral overload and intoxication instead of pneumonia.

Focusing on the virus structural characteristics and bilayer lipid coverage of Covid-19 [3] a lipid base intravascular component (Intralipid) could play a rescue therapy role in refractory Cardiopulmonary injury [1-3].

We believe that the virus mimics the local anesthetic systemic toxicity [4]. Based on the aggressive behavior of Covid-19 and progressive lung involvement we believe that we should focus on the potential systemic toxicity of the virus with involvement of cardiopulmonary system as target organs based on the affinity of the virus to ACE receptors [1,2]. Irreversible cardiopulmonary resuscitation is in favor of virus overload and total blockade or cardiopulmonary system by Covid-19 (viral intoxication) such as local anesthetics overdose and other lipophilic drugs such as Lamotrigine [5] and diltiazem [6] toxication. Viral blockade is gradual but progressive.

This article is aimed to report a case of Covid-19 with severe

pulmonary involvement (ICU admitted patient under mechanical ventilation). Pulmonary infiltrations subsided obviously 48 hours after injection of intralipid and packed cell.

Case Presentation

A 65-year-old male patient, with the history of diabetes and hypertension was presented to the hospital by mild dyspnea on march 14. The initial Symptoms started by fever on march 10, 2020. Diarrhea started on march 11 and lasted for two days and then ceased. The patient was admitted to the hospital on march 14. No medical therapy was received by patient. On the day 5 after hospitalization, sudden drop in blood pressure (70/40 mmHg) and Spo₂ (less than 70%) resulted in deterioration of consciousness and urgent tracheal intubation. Mechanical ventilation was established and infusion of dopamine was administered. The laboratory tests showed severe changes. WBC: 7300, RBC: 4.05, HG: 11.2, neutrophil: 90%, lymphocyte: 5%, Albumin 2.5gr/dl. Anaemia and Hypoalbuminemia were progressive. Chest CT detected massive pulmonary involvement with grave inflammation (Figure 1).

After tracheal intubation and establishment of mechanical ventilation, inotropic dose of dopamine continued for two days.

on the day 3 besides conservative cardiovascular treatment, aggressive rescue therapy was proposed as bellow;

Infusion of Intralipid 10%, 500 mL for 2 days and infusion of packed cell 1 unit for two days, in order to substitute destroyed RBCs

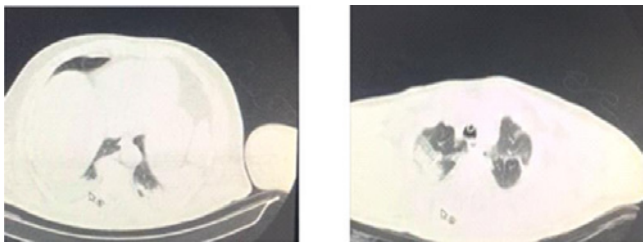


Figure 1: Computed tomography before treatment.

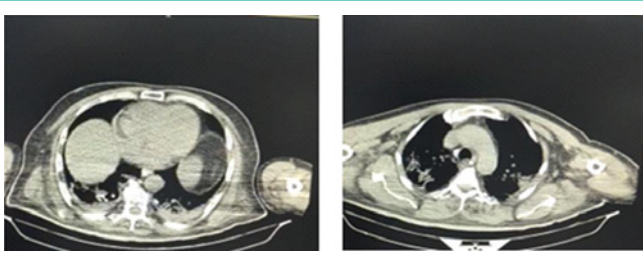


Figure 2: Computed tomography 48 hours after intralipid infusion.

to achieve enough oxygen carrying capacity.

Progressive improvement of vital signs and GCS was observed after administration of intralipid and packed cell.

Prominent recovery was detected in lung control CT (Figure 2) after aggressive treatment with intralipid and packed cell. After one week, patient was extubated and 48 hours later he was transferred to the ward.

Discussion

Aggressive behavior of Covid-19 and progressive lung dysfunction, proposes the probable systemic toxicity of the virus with prominent involvement of cardiopulmonary system as target organ based on the affinity of the virus to ACE receptors [1,2]. Irreversible cardiopulmonary resuscitation is in favor of virus overload and total blockade of cardiopulmonary system by Covid-19 (viral intoxication).

May be using antivirals for treatment of pulmonary dysfunction is wrong approach.

It seems that the probable cause of death is disseminated cardiopulmonary involvement by viral load and viral intoxication. Respiratory insufficiency is the consequence of viral colonization in lungs and heart. Ultimate complete cardiopulmonary blockade by viruses is responsible for irreversible cardiopulmonary collapse and death. If we can remove the colony of viruses, early recovery will be achievable.

Biologically similar to most viruses, the outer surface of the coronavirus is coated by a lipid bilayer membrane that houses spike proteins. S proteins are responsible for attaching host cells [3].

S proteins act as hook or claws. The body of the virus is lipid substance and rationally lipid-soluble.

High dose intralipid has been used for cardiopulmonary resuscitation in lipophilic local anesthetics and other lipophilic drug overdose and toxication [7]. "The mechanism by which lipids reverse this kind of cardiotoxicity, is probably increasing clearance

from cardiac tissue". This nonspecific, observed extraction of lipophilic drugs from aqueous plasma or cardiac tissues is termed a "lipid sink" [7].

As Rothschild et. al described the mechanism that intralipid acts in local anesthetic intoxication reversal, [7] intralipid as emulsified fat droplets provides an intravascular lipid compartment in which lipophilic substances such as Corona viruses are partitioned and infused into an aqueous medium such as blood. Blood moves entangled viruses away from area of high concentration (lung, heart, brain ...) to the lipid sink. In other words, offended viruses are entangled in the "Lipid Sink" and virus removal and cardiopulmonary purification fulfils rapidly through circulating intralipid.

Intralipid (20%) has been recommended to administer 1.5 mL/kg as an initial bolus for persistent asystole. The bolus dose can be repeated 1- 2 times [8].

Our patient received an initial rate of Intralipid (10%) infusion, 1mL/min for 30 minutes. No untoward reactions occurred. Then infusion rate was increased to 2 mL/min. Intralipid (10%) 500 ml was administered for 2 days.

Correction of other related Co- morbidities such as anemia and hypoalbuminemia accelerates patient improvement and diminishes recovery period.

As corona virus binds to Hb, oxygen carrying capacity decreases and hypoxemia promotes tissue hypoxia, ischemia and multiorgan failure.

Simultaneous administration of packed cell and intralipid increases O₂ saturation promptly.

Early administration of intralipid and packed cell would be life-saving in severe cardiopulmonary involvement by Covid-19.

Conclusion

It seems that treatment of pneumonia by focusing on antiviral drugs is kind of misconception. In fact, the cardiopulmonary system is involved with a viral overload and intoxication instead of pneumonia. Intralipid is good choice to overcome viral overload.

Intralipid is recommended as rescue therapy in severe pulmonary involvement in Covid-19.

Limitations

This study was conducted on a volunteer patient. Although we found Intralipid infusion of value in Covid-19 lung invasion, it would need to be evaluated in a randomized trial.

Unfortunately despite the safety of intralipid and approval for using intralipid in ICU admitted patients and absence of any efficient medication against destructive effects of SARS Covi 2 , designing a trial for ICU admitted Covid 19 patients, was evaluated as non ethical, in research department of Tehran University of Medical Sciences. It was the most important limitation for authors to design a systematic study to provide more documents.

Declarations

Consent for publication

Written informed consent was obtained before starting the

treatment. A separate written informed consent was obtained for publishing the photographs.

Availability of data and materials

Data and materials are available in Ardebil University of Medical Sciences, Imam Khomeini hospital.

Authors' contribution

Mihan J Javid and Jayran Zebardast contributed to Manuscript preparation.

Acknowledgement

I would like to thank Dr. Shahnaz Fooladi for her cooperation in the treatment of the patient.

The Author Mihan J Javid has proposed a novel protocol for prevention and treatment of Covid-19 invasion, in different stages. It has been registered in USPTO on March 24. Treatment with Intralipid in ICU patients is part of this protocol. The author is interested in sharing it to the world.

References

1. Orfanos SE, Langleben D, Khoury J, Schlesinger RD, Dragataki L, Roussos C, Ryan JW, Catravas JD. Pulmonary capillary endothelium-bound angiotensin-converting enzyme activity in humans. *Circulation*. 1999; 99: 1593-9.
2. Andrew M. Allen, Jialong Zhuo, Frederick A.O. Mendelsohn. Localization and function of angiotensin AT1 receptors. *American Journal of Hypertension*. 2000; 13: 31S-38S.
3. Shereen MA, Khan S, Kazmi A, Bashir N, Siddique R. COVID-19 infection: Origin, transmission, and characteristics of human coronaviruses. *Journal of Advanced Research*. 2020; 24: 91-98.
4. Ciechanowicz S, Patil V. Lipid Emulsion for Local Anesthetic Systemic Toxicity. *Anesthesiol Res Pract*. 2012; 2012: 131784.
5. Tara J. Bellis and Laura Gibeon. The use of intralipid emulsion therapy to treat severe cardiotoxicity secondary to lamotrigine ingestion in a dog. *Clin Case Rep*. 2018; 6: 1982-1988.
6. Muller SH, Diaz JH, Kaye AD. Intralipid Emulsion Rescue Therapy: Emerging Therapeutic Indications in Medical Practice. *J La State Med Soc*. 2016; 168: 101-3.
7. Rothschild L, Bern S, Oswald S, Weinberg G. Intravenous lipid emulsion in clinical toxicology. *Scand J Trauma Resusc Emerg Med*. 2010; 18: 51.
8. Weinberg GL. Lipid infusion therapy: translation to clinical practice. *Anesth Analg* 2008; 106: 1340-2.