

Case Report

A Case of One-Lung Ventilation Using Double-Lumen Tube Inserted into Patient with Voice Prosthesis After Total Laryngectomy

Kida H*; Shibata T; Takahashi K

Department of Anesthesiology, Kanazawa Medical University, Japan

***Corresponding author: Kida H**

Department of Anesthesiology, Kanazawa Medical University, 1-1, Daigaku, Uchinada-cho, Kahoku-gun Ishikawa 920-0293 Japan.

Tel: +81-076-286-3511; Fax: +81-076-286-3475

Email: kida0430@kanazawa-med.ac.jp

Received: March 27, 2023**Accepted:** April 15, 2024**Published:** April 22, 2024

Introduction

Total laryngectomy results in loss of voice and deprives patients of their ability to communicate. A Voice Prosthesis (VP) is one of the devices to restore loss of speech for such patients [1,2]. VP is recognized as the preferred method of voice restoration due to its high success rate of producing speech, and short training time after total laryngectomy. It is placed in a created fistula between the trachea and esophagus. Major tracheoesophageal puncture issues can lead to pulmonary infections and other respiratory complications. A detailed explanation of the device has been provided by Itzhak Brook et al., [3] but it is rare for anesthesiologists to encounter this device in clinical practice. Removing the speech cannula and replacing it with a tracheotomy tube in patients who have undergone a tracheotomy is a common practice in general anesthesia management. Anesthesiologists are familiar with these devices and have established methods for airway management. However, One-Lung Ventilation (OLV) in patients with tracheostomy is a special condition that limits the methods available for lung isolation and makes airway management difficult. OLV through a tracheostomy stoma is typically managed with bronchoscope-guided placement of either a Double-Lumen Tube (DLT) or bronchial blocker.

Summary

The Voice Prosthesis (VP) is a device used to reacquire speech in patients who have undergone laryngectomy. There is no established airway management approach to one-lung ventilation for such patients.

An 82-year-old man, with a past history of total laryngectomy, jejunum transplantation, and permanent tracheostomy to treat laryngeal cancer. A tracheoesophageal shunt was created and VP was placed. A thoracoscopic left upper lobectomy was scheduled for a patient with a VP. We selected multiple options to secure the airway and prepared a support system in case of accidental removal of VP. As VP removal would have increased the risk of aspiration, we secured the airway using a 39 Fr tracheostomy double-lumen tube after inducing anesthesia.

In patients with one-lung ventilation, it is possible to minimize the risk of aspiration as VP is not easily displaced, even while performing intubation without its removal.

Keywords: Voice prosthesis; One-lung ventilation; Difficult airway; Double-lumen tube

Abbreviations: VP: Voice Prosthesis; OLV: One-Lung Ventilation; DLT: Double-Lumen Tube; SLT: Single-Lumen Tube

There are no established methods for patients who have undergone a laryngectomy and have VP to manage the airway or handle VP during general anesthesia management, because only a few studies have extensively examined patients with such a condition.

In this study, we report our experience of inserting a Double-Lumen Tube (DLT) in a patient who underwent a total laryngectomy and had VP.

Case Presentation

The patient was an 82-year-old man who was 158 cm in height and weighed 55 kg. Comorbidities were spinal canal stenosis, diabetes mellitus, and hypertension.

A total laryngectomy, jejunum transplantation, and permanent tracheostomy were performed 14 years ago to treat laryngeal cancer. Two months after the surgery, a tracheoesophageal shunt was created and VP was placed (Figure 1). Chest Computed Tomography (CT) revealed a large, 10-mm nodular shadow in the left upper lobe of S3, and a thoracoscopic left upper lobectomy was scheduled to be performed under general

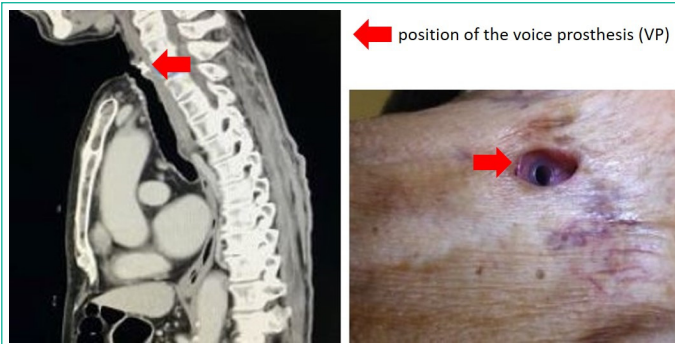


Figure 1: The positional relationship of the stoma and VP. The red marks demonstrates the position of the VP. VP has flanges that make it less likely to become dislodged.

anesthesia. Perioperative Forced Expiratory Volume in 1 second (FEV_{1.0}) was 1.73L, FEV_{1.0}% was 79.4%, Forced Vital Capacity (FVC) was 2.46 L, and FVC% was 84.2%.

Prior to surgery, the problems and methods used in airway management of patients with VP were discussed with departments of respiratory surgery, head and neck surgery, and anesthesiology. VP was designed to act as a one-way valve for movement of air from the trachea to esophagus on obstructing the tracheostomy with the fingers. Therefore, aspiration can be prevented with VP in place. Furthermore, reinsertion of VP is difficult owing to the need for a dedicated device. An esophageal and tracheal flange prevents falling, acting as a washer to seal the prosthesis against the walls of the esophagus and/or trachea, thus preventing leakage. When VP is left in place, there is a risk of its displacement due to interference between VP and the endotracheal tube.

After entering the operating theater, the blood pressure, heart rate, and oxygen saturation (SpO₂) of the patient were 159/79 mmHg, 63 bpm, and 98%, respectively. After preoxygenation (3 minutes, oxygen flow rate of 6 L), anesthesia was induced using propofol (70 mg) and rocuronium (50 mg). Mask ventilation was performed at less than 10 mmHg using a child-sized mask. During mask ventilation, the position of VP and inner diameter of the permanent stoma were reconfirmed. After confirming that the Train of Four (TOF) monitor showed a count of zero, the Double-Lumen Tube (DLT) was inserted via the permanent stoma in a gentle manner. After establishing that ventilation was possible, appropriate VP placement was confirmed. Mask ventilation and oxygenation were effectively applied throughout the induction. Anesthesia was maintained using sevoflurane, rocuronium, fentanyl, and remifentanyl. During the surgery, no problems, including dislodgement due to interference between VP and DLT, were encountered even when the patient's position was changed. Sputum was suctioned as required during anesthesia and no indications suggestive of aspiration were noted. Chest X-ray was taken after the completion of surgery, and no obvious signs of atelectasis or aspiration were observed. After the patient awakened, extubation was carefully performed to avoid interference with VP. The position of VP was unchanged as compared with the preoperative position. The duration of surgery was 1 hour 34 minutes and anesthesia were maintained for 2 hours 50 minutes. No postoperative complications associated with the airway were observed, and the patient was discharged from the hospital after 1 week.

Discussion

After undergoing total laryngectomy, patients lose their vocal functions and have trouble communicating. Therefore, it is necessary to improve their quality of life by restoring their

speech. VP is a shunt device that has a high rate of success for speech rehabilitation,^[4] and is considered the gold standard for speech recovery [1,2,4]. In the future, it is expected that the number of patients undergoing general anesthesia with VP in place will increase. However, no established anesthesia method exists for the treatment of patients with VP.

There are no clear guidelines regarding whether VP should be removed or left in place when patients with it undergo general anesthesia. However, VP has an internal one-way valve that stops food and saliva from entering the airway. Removing VP connects the esophagus to airway, thereby increasing the risk of aspiration. Additionally, as reinserting VP requires a dedicated device and skilled surgeon, this procedure is not straightforward for the anesthesiologist to perform. Therefore, support from otolaryngology and head and neck surgery departments is essential. Thus, we administered general anesthesia with VP left in place.

Very few studies have reported on airway management methods for patients with VP. Only one reported case necessitating One-Lung Ventilation (OLV) was published, in 1997, wherein a Hunsaker Mon-Jet tube was inserted into a laryngectomy tube [5]. The external diameter of an 8.0-mm wide Single-Lumen Tube (SLT) is 10.9 mm, whereas the external diameter of a 39 Fr DLT (13.9 mm) is larger. Therefore, a SLT with smaller diameter than a DLT had been used to avoid interference with the VP in the report. However, the main part of VP is very small; if the tracheal opening is sufficiently wide, the risk of interference between VP and DLT is minimal. In addition, the flanges on esophageal and airway sides prevent dislocation of VP. In contrast, the only DLT used is 39 Fr that exhibits low-level flexibility; therefore, VP may be an obstacle while securing the airway in patients with a small stoma. In the present case, the tracheostomy was sufficiently open.

While vocalizing with the shunt, the air is directed into the esophagus by blocking the permanent stoma; however, during mask ventilation, there is a risk of anesthesia gas entering the esophagus. The gas flow rate from the VP one-way valve is very low at airway pressures of less than 10 mmHg [6]. Therefore, with positive pressure ventilation of less than 10 mmHg, gas inflow into the esophageal side is unlikely. The risk of aspiration is considered minimal with mask ventilation kept at the lowest pressure, because VP is located in the upper esophagus. For these reasons, we developed airway strategies as follows: (1) VP is left in place; (2) tracheal intubation occurs after induction of general anesthesia to avoid interference between VP and the tracheal tube due to body movements; (3) mask ventilation is kept at the lowest inspiratory pressure (less than 10 mmHg); and (4) a 39 Fr tracheostomy DLT is initially inserted, but if marked interference between DLT and VP is encountered, a spiral tube and bronchial blocker tube should be used.

In this case, muscle relaxants were administered to avoid interference between the intubation tube and VP due to body movements. We preferred using DLT, and there was no interference between VP and DLT.

The average durability of VP is 182 days, or 7.53 months [7,8]. In cases where a long time has passed since placement, leakage through VP or around it may occur and another surgery has to be performed to replace VP before the intended surgery.

We developed airway strategies to one-lung ventilation for the patients with VP in place.

Author Statements

Acknowledgements

Published with the written informed consent of the patient. No external funding and no competing interests declared.

References

1. ACC B, VP R, MWM van den B, WH van Harten. Patient access to voice prostheses and heat and moisture exchangers: Factors influencing physician's prescription and reimbursement in eight European countries. *Oral Oncol.* 2019; 91: 56-64.
2. Joseph Z, Tessa G, Glenn B, Daniel GD. State of the art: Rehabilitation of speech and swallowing after total laryngectomy. *Oral Oncol.* 2018; 86: 38-47.
3. Itzhak B, Joseph FG. Tracheoesophageal voice prosthesis use and maintenance in laryngectomees. *Int Arch Otorhinolaryngol.* 2020; 24: e535-8.
4. Jane YT, Luke JP, Daniel AB, Robert T. Complications associated with tracheoesophageal voice prostheses from 2010 to 2020: A MAUDE study. *Am J Otolaryngol.* 2020.
5. Ricard JSR. One-lung ventilation for thoracotomy using a Hum-saker jet ventilation tube. *Anesthesiology.* 1997; 87: 1572-4.
6. Fernando HTS, Andrey RS, André MCT, Byron E. Influence of position and angulation of a voice prosthesis on the aerodynamics of the pseudo-glottis. *J Biomechanics.* 2021; 125: 110594.
7. Kipras P, Agnè P, Vykintas L, Gabija P, Gabija G, Virgilijus U. Factors affecting the lifetime of third-generation voice prosthesis after total laryngectomy. *J Voice Available.* 2022; 4: s0892-1997(22)00028-5.
8. Mafalda MS, Ricardo M, Helena V, Margarida S, Helena S. Voice rehabilitation with voice prosthesis: long term results, complications and risk factors. *Acta Otorrinolaringol Esp.* 2022; 73: 219-24.