

Case Presentation

Absence of Bilateral Musculocutaneous Nerves

Shakthi Kumaran R¹ and Chitra R^{2*}

¹Department of Anatomy, Aarupadai Veedu Medical College, India

²Department of Anatomy, Siddhartha Medical College, India

*Corresponding author: Chitra R, Department of Anatomy, Siddhartha Medical College, Vijayawada-520008 (AP), India

Received: December 13, 2018; Accepted: June 21, 2019; Published: June 28, 2019

Abstract

Variations of the lateral cord of brachial plexus have been reported by several authors. During routine educational dissection in the academic year (2008-2009), in a 55-year-old female cadaver, on the right side, lateral cord gave a communicating branch to ulnar nerve, another slender lateral root of median nerve which joined with medial root to form the median nerve which was joined by the complete lateral cord about 10 cm from the coracoid process. Along with this variation, absence of musculocutaneous nerve was noticed. The muscles of front of arm i.e. biceps brachii, brachialis and coracobrachialis received their nerve supply from median nerve. On the left side in the same cadaver, the lateral cord gave three branches- a branch to the coracobrachialis, a slender lateral root of median nerve and another branch to join the median nerve about 10 cm from the coracoid process. The musculocutaneous nerve was absent on the left side also. The biceps brachii and brachialis were supplied by the median nerve on the left side. The variations of the cords of brachial plexus should be kept in consideration while performing surgical exploration of the axilla and arm region to avoid damage to these important nerves

Keywords: Musculocutaneous nerve; Median nerve; Ulnar nerve; Brachial plexus; Coracobrachialis

Case Presentation

During routine educational dissection in the academic year (2008-2009), in a 55-year-old female cadaver, on the right side, lateral cord gave a communicating branch to ulnar nerve, another slender lateral root of median nerve which joined with medial root to form the median nerve which was joined by the complete lateral cord about 10 cm from the coracoid process (Figure 1). Along with this variation, absence of musculocutaneous nerve was noticed. The muscles of front of arm i.e. biceps brachii, brachialis and coracobrachialis received their nerve supply from median nerve. On the left side in the same cadaver, the lateral cord gave three branches- a branch to the coracobrachialis, a slender lateral root of median nerve and another branch to join the median nerve about 10 cm from the coracoid process (Figure 2). The musculocutaneous nerve was absent on the left side also. The biceps brachii and brachialis were supplied by the median nerve on the left side.

Discussion

According to Tountas and Bergaman (1993), musculocutaneous nerve arises from the lateral cord in 90.5%, from lateral and posterior cord in 4%, from medial cord in 2% and as two separate bundles from the medial and lateral cords in 1.4% [1]. In the past many variations have been described regarding the course of musculocutaneous and median nerves. Le Minor (1992) described five types of variations: [2]

Type 1: There is no communication between the median and musculocutaneous nerve. Type 2: The fibers of medial root of median nerve pass through the musculocutaneous nerve and join the median nerve in the middle of the arm. Type 3: The lateral root fibers of median nerve pass through the musculocutaneous nerve and after some distance, leave it to form the root of the median nerve. Type 4: The musculocutaneous fibres join the lateral root of

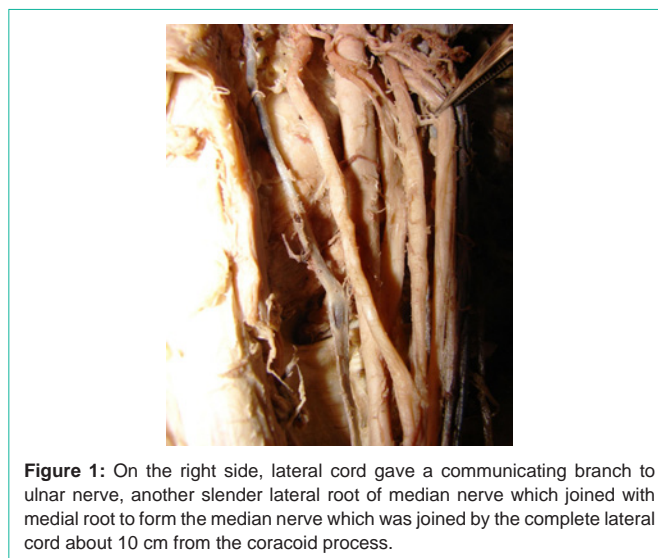


Figure 1: On the right side, lateral cord gave a communicating branch to ulnar nerve, another slender lateral root of median nerve which joined with medial root to form the median nerve which was joined by the complete lateral cord about 10 cm from the coracoid process.

the median nerve and after some distance the musculocutaneous arise from the median nerve. Type 5: The musculocutaneous nerve is absent and the entire fibres of musculocutaneous pass through lateral root and fibres to the muscles supplied by musculocutaneous nerve branch out from the median nerve

Beheiry dissected 60 arms and noted absence of the nerve in only one of them (1.7%) [3]. Prasada Rao and Chaudhary did not find this nerve in 8% of the 24 arms they dissected [4].

Absence of musculocutaneous nerve was reported by many authors [2,5,6]. Bergman et al. [7] reported that 90% of the musculocutaneous nerve arises from the lateral cord while in 2% of the cases it may arise from the median nerve or may be completely absent. Le Minor [2]

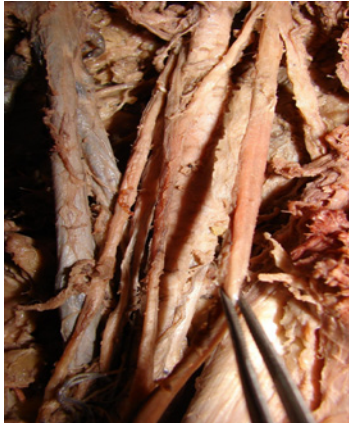

Figure 2: On the left side, the lateral cord gave three branches- a branch to the coracobrachialis, a slender lateral root of median nerve and another branch to join the median nerve about 10 cm from the coracoid process.

and Gümüşburun [8] classified five types of variation, with the 5th type being the complete absence of musculocutaneous nerve, where anterior arm muscles will be supplied by the median nerve. Our present case had complete absence of the MCN coinciding Le Minor's and Gümüşburun [2,8] 5th type of classification but different from the above classification by the branch to the coracobrachialis arising from the lateral cord of brachial plexus. The branch to coracobrachialis arising from the lateral cord of brachial plexus has been reported by Tatar [9].

Sachdeva and Singla reported a rare origin of ulnar nerve from median nerve [10]. In their case also, authors noted a bifurcation of the median nerve shortly after its formation into median nerve proper and the ulnar nerve. Gupta et al. observed a similar type of variation in the formation of ulnar nerve as we report here, differing slightly wherein there was a contribution from medial root of median nerve [11].

References

1. Tountas C, Bergaman R. Anatomic variation of the upper extremity. Churchill Livingstone. 1993; 223-234.
2. Le Minor JM. A rare variation of the median and musculocutaneous nerves in man. Arch Anat Histol Embryol. 1990; 73: 33-34.
3. Beheiry EE. Anatomical variations of the median nerve distribution and communication in the arm. Folia Morphol (Warsz). 2004; 63: 313-318.
4. Prasada Rao PV, Chaudhary SC. Communication of the musculocutaneous nerve with the median nerve. East Afr Med J. 2000; 77: 498-503.
5. Sud M. Absence of the musculocutaneous nerve and the innervation of coracobrachialis, biceps brachii and brachialis from the median nerve. J Anat Soc India. 2000; 49: 176-177.
6. Aydin ME, Kale A, Edizer M, Kopuz C, Demir MT, Corumlu U. Absence of the musculocutaneous nerve together with unusual innervation of the median nerve. Folia Morphol. 2006; 65: 228-231.
7. Bergman RA, Thompson SA, Afifi AK, Saadeh FA. Compendium of human anatomic variation: catalogue, atlas, and world literature. Baltimore, Munich: Urban and Schwarzenberg. 1988; 139-143.
8. Gümüşburun E, Adigüzel E. A variation of the brachial plexus characterized by the absence of the musculocutaneous nerve- a case report. Surg Radiol Anat. 2000; 22: 63-65.
9. Tatar I, Brohi R, Sen F, Tonak A, Celik H. Innervation of the coracobrachialis muscle by a branch from the lateral root of the median nerve. Folia Morphol. 2004; 63: 503-506.
10. Sachdeva K, Singla RK. An unusual origin of an ulnar nerve from a median nerve-a case report. Journal of Clinical and Diagnostic Research. 2011; 5: 1270-1271.
11. Gupta N, Goyal N, Harjeet. Anomalous communications in the branches of brachial plexus. Journal of the Anatomical Society of India. 2005; 54: 22-25.