

Research Article

Presentation of Different Types of Hand Anomalies in Poland's Syndrome

Fijałkowska M* and Antoszewski B

Department of Plastic, Reconstructive and Aesthetic Surgery, Medical University of Lodz, Poland

*Corresponding author: Marta Fijałkowska,
Department of Plastic, Reconstructive and Aesthetic Surgery, Medical University of Lodz, Poland

Received: September 16, 2016; Accepted: October 22, 2016; Published: November 04, 2016

Abstract

Introduction: Poland's syndrome is characterized by variable clinical picture. Classic deformity includes unilateral hypoplasia or aplasia of the sternocostal head of the pectoralis major muscle and ipsilateral hand malformations – in such form pathology is known as complete Poland's anomaly. Variable anomalies in Poland's syndrome cause that there is no uniform treatment schedule.

The aim of this study is to present different types of hand anomalies in patients with Poland's syndrome and own experience of its treatment.

Material and Method: An analysis of types of hand defects and their surgical treatment was carried out in the group of 66 patients with Poland's syndrome who have been hospitalized in Plastic, Reconstructive and Aesthetic Surgery Department /Medical University of Lodz/ during years 1990-2010.

Results: In the analyzed group there were 19 patients with complete Poland's syndrome, 8 of them were surgically treated. Syndactyly observed in patients with complete Poland's anomaly was surgically removed in early childhood.

Conclusion: Poland's syndrome is characterized by variable clinical picture and require individual plan of treatment, depending on patient's age, sex and severity of clinical defects. The treatment of patients with complete Poland's syndrome should be started at the kindergarten age and the surgeries mainly involve separation of syndactyly.

Keywords: Poland's syndrome; Hand anomaly; Classification; Syndactyly; Treatment

Introduction

Poland's syndrome was first described by Alfred Poland in 1841. It is characterized by a variable clinical picture, while all the potential symptoms are rarely present in a single patient. The typical elements of this anomaly include unilateral hypoplasia or absence of the sternocostal portion of pectoralis major muscle and hand defects affecting the same side of the body [1-4]. In women with Poland's syndrome, disturbed development of the breast is observed on the affected body side. Breast growth inhibition has many forms, from mild micromastia to amastia [1,3-5].

Coexisting defects of the chest wall and the hand are known as complete Poland's syndrome [1,6]. However, more commonly, patients suffer from isolated pectoralis major muscle hypoplasia and are diagnosed with partial Poland's syndrome [1,4,6]. Many authors agree that the key, constant and sufficient symptom which allow the Poland's syndrome diagnosis are pectoralis major muscle abnormalities [6,7].

The incidence of Poland's syndrome reported by different authors varies, it ranges from 1:20 000 to 1:100 000 [2-4,6,8]. This condition is three times more common in men than in women and usually the right side is affected in 75% of cases [6,9]. The aetiology of Poland's syndrome is still under discussion. Disruption of the normal development of the subclavian artery, the vertebral artery and/or

their branches, defective migration of fetal mesodermal tissue and intrauterine insults, mainly hypoxia, have been suggested as possible causes [3,9].

In the available literature we can find attempts of classification of hand's anomalies in Poland's syndrome.

Gausewitz in 1984 has divided them into four groups: type 1- five digits present even if hypoplastic; type 2- functional border digits with absent central digits (cleft hand); type 3- more severe absence deformities with no functional digits; type 4- radial ray defects and absent thumb [10].

In 1998 Minguella and Cabrera on the basis of clinical and radiological symptoms classified patients with Poland's syndrome into 5 types: type 1, without syndactyly; type 2 syndactyly and hypoplastic or aplastic middle phalanx; type 3 or "shovel hand" with complete syndactyly also affecting the thumb; type 4 longitudinal deficiency of some digits or radius and type 5 transversal absence [11].

Kuklik (2000) has quoted classification of hand anomalies, which has three subgroups: A- symbrachydactyly associated with brachymesophalangia without oligodactyly; B- the distal phalanges of the second to the fourth fingers are absent; C- the ectrodactyly (cleft) of the hand with no absence of other defect of the carpal bones [12].

The most precise classification was offered by Al-Qattan (2001).

He has divided hand's anomalies in Poland's syndrome in seven grading types with increasing severity of anomaly:

- Type 1- normal hand (isolated pectoral anomaly)
- Type 2- form fruste deformity (the hand appears smaller only when compared to the contralateral side)
- Type 3- the classic deformity (brachysyndactyly)
 - A-mild to moderate hypoplasia of the hand
 - B-severe hypoplasia of the hand
- Type 4- some functional rays still present
 - A radial club hand with floating or absent thumb
 - B-adactyly of the index
 - C-adactyly of the index and long fingers
 - D-adactyly of the central rays creating a cleft hand
 - E-adactyly of the ulnar rays
- Type 5- all digits are functionless or absent
- Type 6- transverse deficiency proximal to the metacarpophalangeal joints
- Type 7- phocomelia-like deficiency [13].

The aim of this study is to present different types of hand anomalies in patients with Poland's syndrome and its treatment.

Material and Method

In the years 1990-2010, 66 patients with Poland's syndrome were treated in Plastic, Reconstructive and Aesthetic Surgery Department/ Medical University of Lodz/. Each patient underwent clinical examination and photographic documentation was performed. On the basis of ambulatory cards, hospital histories and photos the data base of patients with Poland's anomaly was created. The collected data included: age, sex, and side of anomaly, distinction between complete and partial defect, type of hand anomaly classified according to Al-Qattan (2001) and methods of introduced treatment.

In the analyzed group there were 8 men and 58 women. The patients' age, at the time of first consultation, was from 6 to 65 years (on average 28.22 years; SD=10.9).

On the basis of patients' documentation and created data base the analysis of performed treatment was conducted.

Due to the descriptive character of the study, the statistical tests were not accomplished.

Results

In analyzed group only 19 patients had complete Poland's syndrome (28.8%) (13 females and 6 males). According to Al-Qattan (2001) classification type 2 of anomaly was present in 8 patients (42.1%), subtype 3A in 5 (26.3%), subtype 3B in 3(15.8%) (Figure 1), subtype 4C in 1 (5.3%) and subtype 4D in 2(10.5%) (Figure 2). Remaining 47 patients (71.2%) with partial defect were classified to type 1 of hand malformation.

From the group of 19 patients only 8 (5 females and 3 males) were

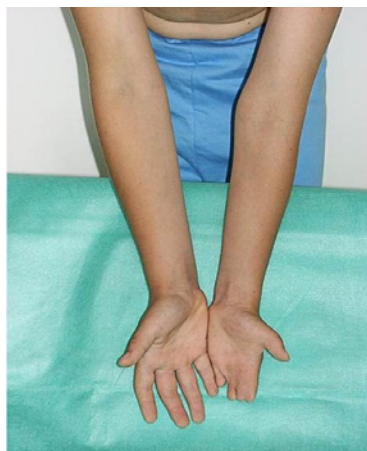

Figure 1: Patient with the classic deformity (brachysyndactyly) (type 3B).

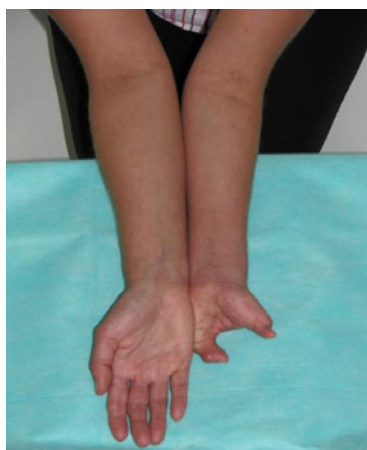

Figure 2: Patient with cleft hand (type 4D).

operated on in Our Center (Figure 3). All procedures were performed under general anaesthesia, at limb ischemia. Syndactyly separation was accompanied by web formation with the use of either 2 triangular flaps or 1 rectangular flap. In 4 patients, syndactyly affected fingers 2-5 and in those cases, separations of fingers 2 and 3 and fingers 4 and 5 were performed at one time. Syndactyly of fingers 3 and 4 was treated at the next stage. Six patients required surgical enlargement of finger web. Syndactyly separation was performed at kindergarten age (between the ages of 2 and 6). Only 1 female patient underwent the procedures at an older age (9 and 10) due to the fact that patient's parents had not reported to the hospital until she was 9. After treatment finishing, patients were able to perform alternating finger movements, impossible previously, and two of them started learning how to play keyboard instruments.

The remaining 11 patients with complete Poland's syndrome had no indications for surgical treatment of the upper limb. In 7 of them, the hand on the affected side was formed correctly, although smaller than the healthy one. In one female patient, the abnormal hand was smaller than the healthy one and in addition fingers 2 and 3 were deformed, while two other patients were diagnosed with ectrodactyly (cleft hand). In one patient from this group, the hand defect was so

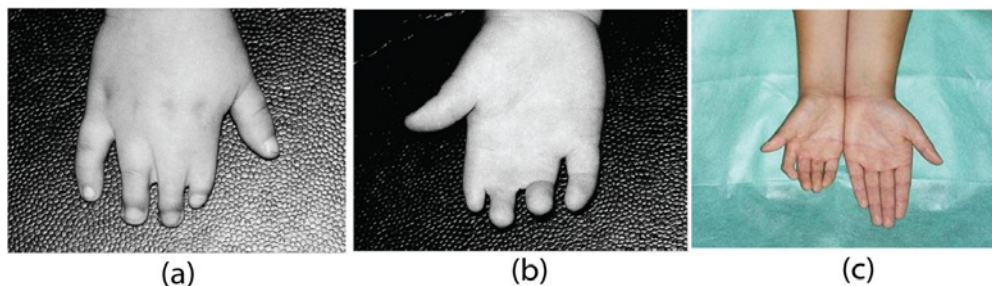


Figure 3: (a) & (b) Patient with the classic deformity (brachysyndactyly) before operation; (c) The same patient after syndactyly releasing.

Table 1: Patients with complete Poland's syndrome treated in our centre.

No of patients	Age /years/	Sex	Affectedside	Type of hand anomaly according to Al-Quattan classification	Surgical treatment
1	25	F	R	2	no
2	23	F	L	2	no
3	14	M	L	2	no
4	25	M	L	3B	yes
5	28	M	R	3A	yes
6	35	F	L	3A	yes
7	23	F	R	2	no
8	15	F	L	2	no
9	52	F	R	2	no
10	38	F	R	2	no
11	28	F	L	4D	no
12	22	F	R	3A	yes
13	9	M	L	4D	no
14	19	F	L	3B	yes
15	11	M	L	3B	yes
16	22	F	R	2	no
17	24	M	L	4C	no
18	29	F	R	3A	yes
19	29	F	R	3A	yes

advanced (absence of fingers 2-5) that it required consultation at the hand defects center.

Discussion

Due to the large number of defects described in Poland's syndrome, there has been no uniform treatment regimen established to date. The therapeutic approach is chosen individually for each patient, depending on the severity of pathology, patient's age and sex [1,4].

Al-Quattan (2001) in his paper described 17 patients with complete Poland's syndrome [13]. The most common type of hand anomaly in his group was type 3 (10 patients). In our research it was 8 patients. Definitely brachysyndactyly is known as the classic deformity existing in Poland's syndrome. In Al-Quattan study there were more patients with severe upper limb malformation (type 5 and 6), while in our group there were more patients with type 2 – the affected hand was smaller only when compared to the contralateral side. Occurring of type 4 of anomaly was very similar – 3 patients in Al-Quattan and

3 patients in our analysis.

In patients with complete Poland's syndrome, hand surgery is performed first. In plastic surgery field syndactyly corrections are mainly performed. Occasionally, advanced abnormalities require amputation of individual non-functional fingers and/or hand prosthesis application [13,14]. Unfortunately, certain forms of defects still remain outside the surgical treatment [1,13]. Surgical separation of syndactyly was performed in pediatric patients at the age of 2-6 years. Authors are in agreement that such age is optimal for this type of procedure [4,13,14]. It is important to start the treatment early in order to improve the hand function. Of significance is also the fact that surgical separation of syndactyly may involve several stages, and if initiated at proper age allows the treatment completion before the child goes to school and starts learning how to write. More advanced upper limb defects require treatment at the hand surgery or orthopedics department. Unfortunately, certain deformations remain outside the available therapeutic potential [1,13].

Conclusion

1. Poland's syndrome is characterized by variable clinical picture and require individual plan of treatment, depending on patient's age, sex and severity of clinical defects.

2. The treatment of patients with complete Poland's syndrome is started at the kindergarten age and the surgeries mainly involve separation of syndactyly.

References

1. Fokin AA, Robicsek F. Poland's syndrome revisited. *Ann Thorac Surg.* 2002; 74: 2218-2225.
2. Al-Qattan MM, Al Thunayan A. The middle phalanx in Poland syndrome. *Ann Plast Surg.* 2005; 54: 160-164.
3. Mentzel HJ, Seidel J, Sauner D, Vogt S, Fitzek C, Zintl F, et al. Radiological aspects of the Poland syndrome and implications for treatment: a case study and review. *Eur J Pediatr.* 2002; 161: 455-459.
4. Ślęzak R, Szaśiadek M. Zespół Polanda. *Pol Merkur Lekarski.* 2000; 9: 568-571.
5. Sadove AM, van Aalst JA. Congenital and acquired pediatric breast anomalies: a review of 20 years' experience. *Plast Reconstr Surg.* 2005; 115: 1039-1050.
6. Dolas SC, Poovamma CU, Prema M, Khandelwal R, Pais AV, Kaul A. Poland's syndrome: a case report with review of literature regarding management. *Breast Dis.* 2014; 34: 121-125.
7. Foucras L, Grolleau JL, Chavoïn JP. Poland's syndrome and hand's malformations: about a clinic series of 37 patients. *Ann Chir Plast Esthet.* 2005; 50: 138-145.
8. Vazirnia A, Cohen PR. Poland's syndrome: a concise review of the clinical features highlighting associated dermatologic manifestations. *Am J Clin Dermatol.* 2015; 16: 295-301.
9. Frioui S, Khachnaoui F. Poland's syndrome. *Pan Afr Med J.* 2015; 21: 294.
10. Gausewitz SH, Meals RA, Setoguchi Y. Severe limb deficiency in Poland's syndrome. *Clin Orthop Relat Res.* 1984; 185: 9-13.
11. Minguella-Sola J, Cabrera-Gonzalez M. [Poland's syndrome. A report of 38 cases]. *An Esp Pediatr.* 1998; 48: 143-147.
12. Kuklik M. Poland-Moebius syndrome and disruption spectrum affecting the face and extremities: a review paper and presentation of five cases. *Acta Chir Plast.* 2000; 42: 95-103.
13. Al-Qattan MM. Classification of hand anomalies in Poland's syndrome. *Br J Plast Surg.* 2001; 54: 132-136.
14. Van Heest AE. Congenital disorders of the hand and upper extremity. *Pediatr Clin North Am.* 1996; 43: 1113-1133.